



**ORTHOPEDIC MEDICAL
ASSISTANT
(OMA) CERTIFICATION
STUDY GUIDE**

NSOMA Orthopedic Medical Assistant

Study Guide Table of Contents

SECTION 1: Skeletal Anatomy and Physiology

SECTION 2: Regional Anatomy

SECTION 3: Orthopedic Medicine – Joint Conditions

SECTION 4: Other Orthopedic Conditions

SECTION 5: Trauma

SECTION 6: Orthopedic Extender in the Physician Setting

NATIONAL SOCIETY OF ORTHOPEDIC
MEDICAL ASSISTANTS

nsoma

SKELETAL ANATOMY & PHYSIOLOGY

UNIT I

Anatomy and Physiology Overview

UNIT 1 – Section Objectives

At the end of this unit you should be able to:

1. Define "Anatomy" and "Physiology".
2. Define "Structure" and "Function".
3. List and describe the levels of organization (from chemical level to system level) of the human body, giving examples of each.
4. List and define the directional terms and the anatomical planes used to describe the position and movement of body parts.
5. List and describe the parts and the main functions of the skeletal system.
6. List and describe the four types of bones, giving examples.
7. Identify the two types of bone tissue and compare them in terms of their structure and function.
8. Compare bone and cartilage in terms of their structure and function.
9. List and describe the types of joints according to their structure and mobility.
10. Compare the three types of muscle tissue in terms of their function and microscopic structure.
11. Describe the macroscopic structure and the main functions of skeletal muscles.
12. Compare the action of agonists and antagonists.
13. List the main functions of the nervous system.
14. List and discuss the division of the nervous system into the CNS and PNS.
15. Describe the functions of sensory and motor nerves.
16. List the main functions of the cardiovascular system.
17. Identify three types of blood vessel and describe their functions.
18. Discuss the roles of the skeletal, muscular, nervous and cardiovascular systems in human body movement.
19. List the components of bone tissue.
20. Compare the two types of bone tissue in terms of their structure and function.
21. Describe the structure of a Haversian system.
22. Discuss how the structure of bone is related to its function.
23. Describe the growth of a long bone.
24. Discuss the replacement and reabsorption of bone tissue.
25. Describe the structure and function of a synovial joint.
26. Describe the structure of articular cartilage.
27. Discuss the structure and function of menisci.
28. Describe the structure and function of ligaments.

UNIT 1 – Anatomy and Physiology

1. LEVELS OF ORGANIZATION IN THE BODY

- 2.1 Chemical Level
- 2.2 Cellular Level
- 2.3 Tissue Level
- 2.4 Organ Level
- 2.5 System Level
- 2.6 The Organism

3. GENERAL LAYOUT OF THE BODY

- 3.1 Planes of the Body
- 3.2 Directional terms

4. THE SKELETAL SYSTEM

- 4.1 Bones
- 4.2 Types of Bones
- 4.3 Bone Tissue
 - 4.3.1 Bone growth and development
 - 4.3.2 Bone aging and disease
- 4.4 Cartilage
 - 4.4.1 Articular cartilage
 - 4.4.2 The joint capsule
- 4.5 Ligaments
- 4.6 Menisci
- 4.7 Joints
 - 4.7.1 Synovial joints - general structure
- 4.8 Joint Stability
- 4.9 Joint Complications

5. THE MUSCULAR SYSTEM

- 5.1 Types of Muscle Tissue
- 5.2 Skeletal Muscles

6. THE NERVOUS SYSTEM

- 6.1 Divisions of the Nervous System
- 6.2 Types of Nerves

7. THE CARDIOVASCULAR SYSTEM

- 7.1 The Heart
- 7.2 Blood Vessels
- 7.3 Blood

SUMMARY

GLOSSARY

UNIT 1 – Basic Anatomy

This module entitled Skeletal Anatomy and Physiology aims to help you learn about the structure and function of the skeletal system. Rather than merely describing parts of the skeletal system, the module intends to demonstrate how the different parts work together and how the skeletal system works with other body systems in performing its functions. In particular, this module emphasizes the function of the skeletal system in locomotion.

The module is divided into two units. The first unit introduces the basic concepts and terminology required for comprehensive understanding of the skeletal system anatomy and physiology. The unit starts with the conceptual level of human body organization and then proceeds to familiarize you with the terminology utilized to describe the position and movement of parts of the body. Lastly, the basic structure and functions of the skeletal, muscular, nervous and cardiovascular systems will be investigated.

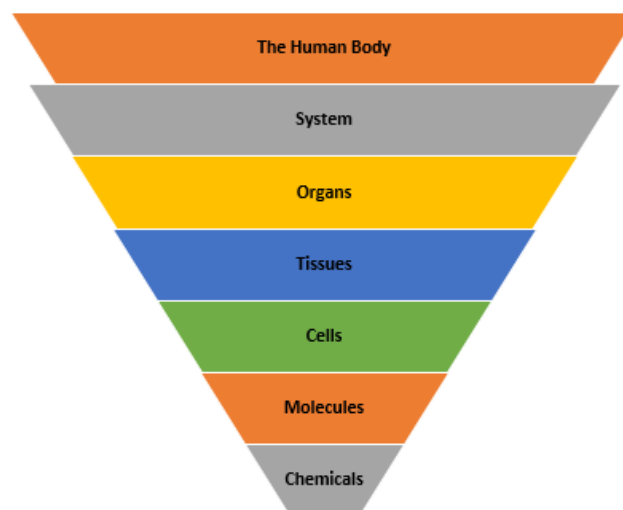
1. ANATOMY AND PHYSIOLOGY

To help in the process of understanding how the human body works, the parts of the body can be described in terms of their **structure** and **function**. The structure of a part is its shape, size, what it consists of and how it is organized. The function is how it works, what it does and how it works together with other parts of the body.

Anatomy is the science of the structure of organisms (living things) and **Physiology** is the science of their function.

2. LEVELS OF ORGANIZATION IN THE BODY

In unicellular (single-celled) organisms, the single cell performs all life functions. It functions independently. However, multicellular (many celled) organisms have various levels of organization within them. Individual cells may perform specific functions and also work together for the good of the entire organism. The cells become dependent on one another. Multicellular organisms have the following 5 levels of organization ranging from simplest to most complex:



<p>CHEMICAL</p>	<p>a. the chemicals that make up the body may be divided into two major categories: inorganic and organic.</p> <p>b. inorganic chemicals are usually simple molecules made of one or more elements other than carbon. examples: water, oxygen, carbon dioxide (an exception), and minerals such as iron, calcium, and sodium.</p> <p>c. organic chemicals are often very complex and always contain the elements carbon and hydrogen. examples: carbohydrates, fats, proteins, and nucleic acids.</p>
<p>CELLULAR</p>	<p>a. the smallest living units of structure and function are cells.</p> <p>b. cells are the smallest living subunits of a multicellular organism such as a human being.</p> <p>c. there are many different types of cells; each is made of chemicals and carries out specific chemical reactions.</p>
<p>TISSUE</p>	<p>a. tissue is a group of cells with similar structure and function.</p> <p>b. there are four groups of tissue. (see Figure: Examples of Four Tissue Types)</p> <p>c. epithelial tissue - cover or line body surfaces; some are capable of producing secretions with specific functions. the outer layer of the skin and sweat glands are examples of epithelial tissue.</p> <p>d. connective tissue - connects and supports parts of the body; some transport or store materials. blood, bone, and adipose tissue (fat) are examples.</p> <p>e. muscle tissue - specialized for contraction, which brings about movement. skeleton muscles and the heart are examples.</p> <p>f. nerve tissue - specialized to generate and transmit electrochemical impulses that regulate body functions. the brain and optic nerves are examples.</p>
<p>ORGAN</p>	<p>a. an organ is a group of two or more different types of tissues precisely arranged so as to accomplish specific functions and usually have recognizable shape.</p> <p>b. heart, brain, kidneys, liver, lungs are examples.</p>
<p>SYSTEM</p>	<p>a. an organ system is a group of organs that all contribute to a particular function.</p> <p>b. examples are the circulatory, respiratory, and digestive systems.</p> <p>c. each organ system carries out its own specific function, but for the organism to survive the organ systems must work together- this is called integration of organ system.</p>
<p>ORGANISM</p>	<p>a. the most complex level.</p> <p>b. all the organ systems of the body functioning with one another constitute the total organism - one living individual.</p>

2.1 Chemical Level

Living material is made up of chemicals - atoms that are organized (joined together) in various ways and are the simplest level within the structural hierarchy. The chemical level of organization includes all the chemicals that are essential for life. The chemical level includes the tiniest building blocks of matter, **atoms**, which combine to form **molecules**, like water. In turn, molecules combine to form **organelles**, the internal organs of a cell.

2.2 Cellular Level

Cells are the basic units of life. They require food and oxygen. Cells can reproduce and can exist in isolation and range in size from 7.5 micrometers to 300 micrometers (a micrometer is a thousandth of a millimeter). In a typical animal cell the **nucleus**, which contains the genetic material and controls the cell's activities, is surrounded by **cytoplasm**, which consists of a semi-fluid substance in which the activities of the cell take place. The cell contents are surrounded by a **cell membrane** which controls substances moving into or out of the cell. (refer to Figure 1)

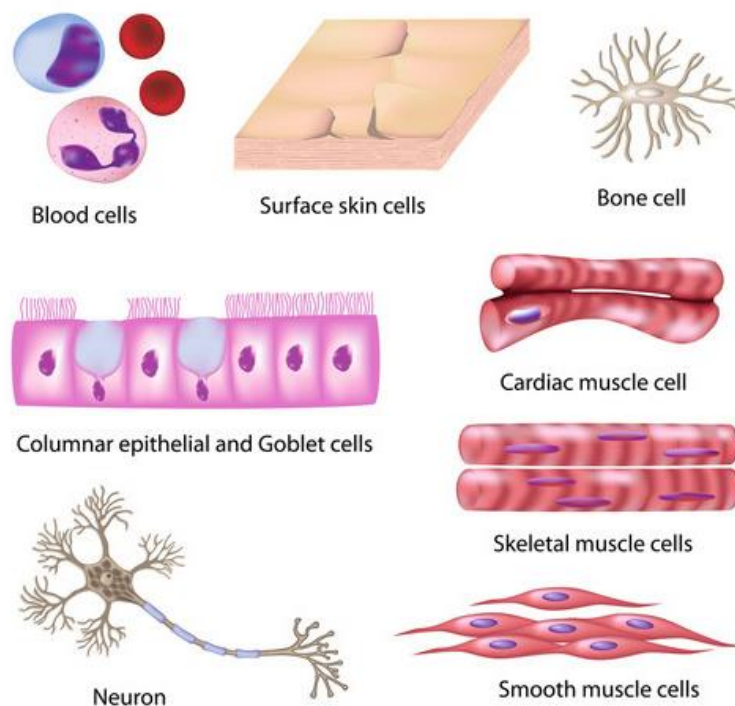



FIGURE 1. SOME OF THE DIFFERENT TYPES OF CELLS FOUND IN THE HUMAN BODY

The shape and size of a cell and the structures it contains vary according to the function of the cell. A human being starts life as a single cell (the fertilized egg) which is 300 micrometers in diameter and carries the genetic material needed for the development of the new human being. This cell divides again and again until a clump of cells is formed. At this stage all the cells are similar. Then the cells start to group into different types as different parts of the genetic material in the cells is 'switched on' - this is called differentiation. This is followed by the development of tissues, organs and systems until the whole human organism is complete.

2 . 3 Tissue Level

Tissues are organized groups of similar cells performing a specific function. Cells in a tissue are surrounded by non-living material referred to as matrix. For example, blood is a tissue consisting of blood cells (red and white cells and platelets) in a liquid matrix (plasma). The functions of blood are to transport substances around the body and protect the body from disease. There are four basic types of human tissues: epithelial, muscle, nervous, and connective tissues. These four tissue types, which are shown in Figure 2 below.

Four Types of Tissues



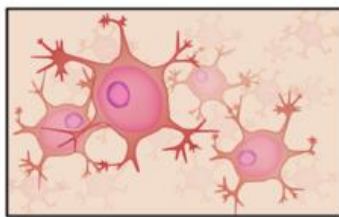
Connective tissue



Epithelial tissue



Muscle tissue



Nervous tissue

2 . 4 Organ Level

Organs are organizations of several types of tissue arranged to work together to perform a specific function. For instance the heart consists of muscle, blood, nervous and connective tissues all working together to pump blood round the body.

2 . 5 System Level

An organ system is a group of anatomical structures that work together to perform a specific function or task. Although we learn about each organ system as a distinct entity, the functions of the body's organ systems overlap considerably, and your body could not function without the cooperation of all of its organ systems. In fact, the failure of even one organ system could lead to severe disability or even death. The human body is composed of 11 different organ systems. These include the following:

Integumentary	Lymphatic
Muscular	Respiratory
Skeletal	Endocrine
Nervous	Urinary/excretory
Circulatory	Reproductive
Digestive	

Organ System	Major Tissues and Organs	Function
Cardiovascular	Heart; blood vessels; blood	Transports oxygen, hormones, and nutrients to the body cells. Moves wastes and carbon dioxide away from cells.
Lymphatic	Lymph nodes; lymph vessels	Defend against infection and disease, moves lymph between tissues and the blood stream.
Digestive	Esophagus; stomach; small intestine; large intestine	Digests foods and absorbs nutrients, minerals, vitamins, and water.
Endocrine	Pituitary gland, hypothalamus; adrenal glands; ovaries; testes	Produces hormones that communicate between cells.
Integumentary	Skin, hair, nails	Provides protection from injury and water loss, physical defense against infection by microorganisms, and temperature control.
Muscular	Cardiac (heart) muscle; skeletal muscle; smooth muscle; tendons	Involved in movement and heat production.
Nervous	Brain, spinal cord; nerves	Collects, transfers, and processes information.
Reproductive	Female: uterus; vagina; fallopian tubes; ovaries Male: penis; testes; seminal vesicles	Produces gametes (sex cells) and sex hormones.
Respiratory	Trachea, larynx, pharynx, lungs	Brings air to sites where gas exchange can occur between the blood and cells (around body) or blood and air (lungs).
Skeletal	Bones, cartilage; ligaments	Supports and protects soft tissues of body; produces blood cells; stores minerals.
Urinary	Kidneys; urinary bladder	Removes extra water, salts, and waste products from blood and body; controls pH; controls water and salt balance.
Immune	Bone marrow; spleen; white blood cells	Defends against diseases.

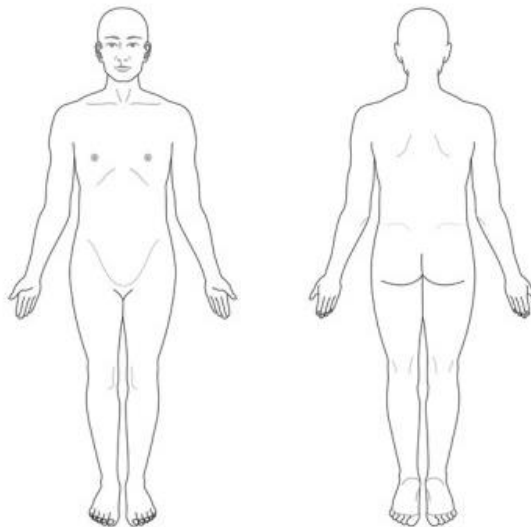
2.6 The Organism

Systems work together - integrate - to perform whole body functions such as movement. The skeletal, muscular, cardiovascular and nervous systems all work together to move the body from place to place (locomotion). The skeletal system supplies the framework for muscle attachment and joints for movement; the muscles supply the forces for movement; the cardiovascular system transports oxygen and nutrients to the muscles to provide energy for movement and removes waste products; and the nervous system supplies the electrical impulses that initiate and co-ordinate muscle contraction. The respiratory and digestive systems are also involved, by supplying the blood with oxygen and nutrients for transportation to the muscles. The whole organism is made up of systems, systems are made up of organs, organs are made up of tissues, tissues are made up of cells and cells contain the chemicals necessary for life.

3. GENERAL LAYOUT OF THE BODY

This module addresses the skeletal system. The anatomical terminology used to describe the positions, views and directions of movement in this system are very important. You should become thoroughly familiar with this terminology as a preparation for the remainder of the course. Most of the following terminology assumes that the body is in the reference position known as the anatomical position: body erect, arms at the sides with palms facing forward. The head and feet also point forward, (see Figure 3)

The anatomical position is the point of reference for all movements. The erect position of the body with the face directed forward, the arms at the side, and the palms of the hands facing forward, used as a reference in describing the relation of body parts to one another.



3.1 Planes and Axes of the Body

There are three sets of reference planes: transverse, coronal and sagittal. Single transverse, coronal and sagittal planes are shown in Figure 3.

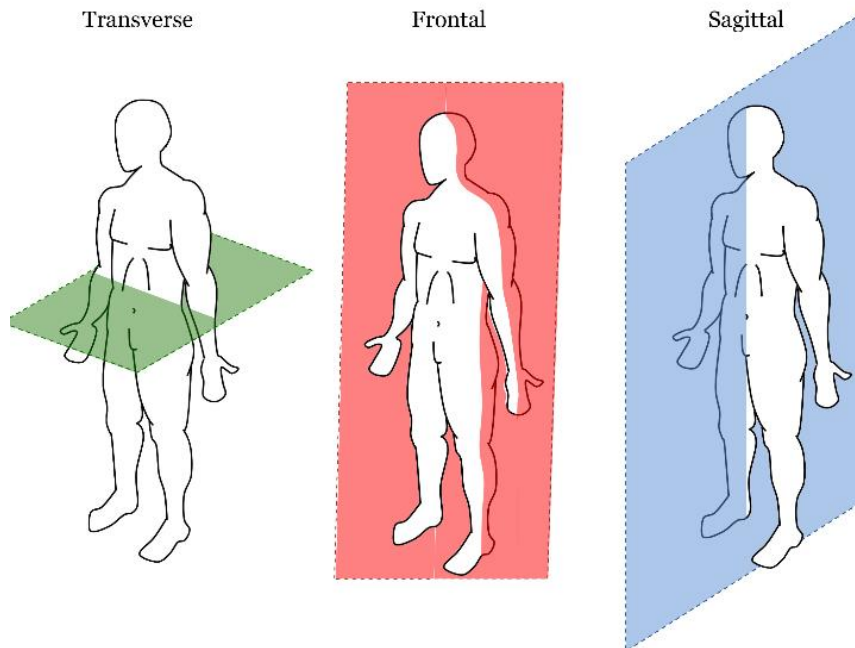


FIGURE 3. REFERENCE PLANES OF THE BODY

Three basic reference planes are used in anatomy:

- A **sagittal plane** is perpendicular to the ground and divides the body into left and right. The *mid-sagittal* or *median plane* is in the midline i.e. it would pass through the midline structures (e.g. navel or spine), and all other sagittal planes (also referred to as *parasagittal planes*) are parallel to it. *Median* can also refer to the mid-sagittal plane of other structures, such as a digit.
- A **coronal** or frontal plane is perpendicular to the ground and divides the body into dorsal (posterior or back) and ventral (anterior or front) portions.
- A **transverse plane**, also known as an *axial plane* or cross-section, divides the body into cranial (head) and caudal (tail) portions. It is parallel to the ground, which (in humans) separates the superior from the inferior, or put another way, the head from the feet.

When describing anatomical motion, these planes describe the axis along which an action is performed. So by moving through the transverse plane, movement travels from head to toe. For example, if a person jumped directly up and then down, their body would be moving through the transverse plane in the coronal and sagittal planes.

Axes

An axis is a straight line around which an object rotates. Movement at the joint take place in a plane about an axis. *There are three axis of rotation.*

- **Sagittal axis** - passes horizontally from posterior to anterior and is formed by the intersection of the sagittal and transverse planes.
- **Frontal axis** - passes horizontally from left to right and is formed by the intersection of the frontal and transverse planes.
- **Vertical axis** - passes vertically from inferior to superior and is formed by the intersection of the sagittal and frontal planes.

Any transverse, coronal or sagittal plane must be parallel to the examples in Figure 3 and the three types of planes are always at right-angles to each other. The sagittal plane which passes through the middle of the body is known as the median plane. Other terms in common use are mid-sagittal instead of median; and not so frequently, parasagittal instead of sagittal. The median plane is the only plane of symmetry in the human body; the left half is a mirror image of the right half (except in small detail).

We often imagine the body to have been cut and separated at a reference plane and then viewed looking directly at the plane. This is sometimes called a cross-section.

3.2 Directional Terms

In skeletal anatomy, directional terms are required for describing viewing directions, relative positions of body parts and relative directions of movement. The terms used in this module are defined below and examples to illustrate each definition.

Superior or cranial - toward the head end of the body; upper (example, the hand is part of the superior extremity).

Inferior or caudal - away from the head; lower (example, the foot is part of the inferior extremity).

Anterior or ventral - front (example, the kneecap is located on the anterior side of the leg).

Posterior or dorsal - back (example, the shoulder blades are located on the posterior side of the body).

Medial - toward the midline of the body (example, the middle toe is located at the medial side of the foot).

Lateral - away from the midline of the body (example, the little toe is located at the lateral side of the foot).

Proximal - toward or nearest the trunk or the point of origin of a part (example, the proximal end of the femur joins with the pelvic bone).

Distal - away from or farthest from the trunk or the point or origin of a part (example, the hand is located at the distal end of the forearm).

Valgus - bent or twisted away from the median plane the big toe is in valgus when bent outwards in a transverse plane

Varus - bent or twisted towards the median plane the foot is in varus when it is bent inwards in the coronal plane

TERM	DEFINITION	EXAMPLE
Flexion	bending at a joint that makes the angle smaller	bending the head forward to the chest
Extension	straightening a joint to make the angle larger	straightening the knee
Hyperextension	extension beyond the straight line of the anatomical position	bending the wrist back
Abduction	moving a part away from the median plane	raising an arm or leg out to the side
Adduction	moving a part towards the median plane	bringing splayed fingers back together
Circumduction	moving a part so that the distal part moves in a circle	drawing a large circle -circumduction of the upper arm at the shoulder
Rotation	moving a bone so that it rotates about its own long axis	turning a lower limb so that the patella (knee cap) is facing away from the lower limb -the femur rotates

4. THE SKELETAL SYSTEM

The skeletal system consists of the bones, their joints and their associated tissues such as ligaments and cartilage. The major bones are shown in Figure 3. It supports the body and protects vital organs. It also provides joints and a framework for muscle attachment, thus playing a part in body movement. This module concentrates on the latter function.

4.1 Bones

A bone is a rigid organ that constitutes part of the vertebral skeleton. Bones support and protect the various organs of the body, produce red and white blood cells, store minerals and also enable mobility. Bone tissue is a type of dense connective tissue. Bones come in a variety of shapes and sizes and have a complex internal and external structure. They are lightweight yet strong and hard, and serve multiple functions. Mineralized osseous tissue or bone tissue, is of two types – cortical and cancellous and gives it rigidity and a coral-like three-dimensional internal structure. Other types of tissue found in bones include marrow, endosteum, periosteum, nerves, blood vessels and cartilage.

4 . 2 Structure

Bone is not a uniformly solid material, but is mostly a matrix. The primary tissue of bone, osseous tissue, is relatively hard and lightweight. Its matrix is mostly made up of a composite material incorporating the inorganic mineral calcium phosphate in the chemical arrangement termed calcium hydroxylapatite (this is the osseous tissue that gives bones their rigidity) and organic collagen, an elastic protein which improves fracture resistance. Bone is formed by the hardening of this matrix around entrapped cells. When these cells become entrapped from osteoblasts they become osteocytes.

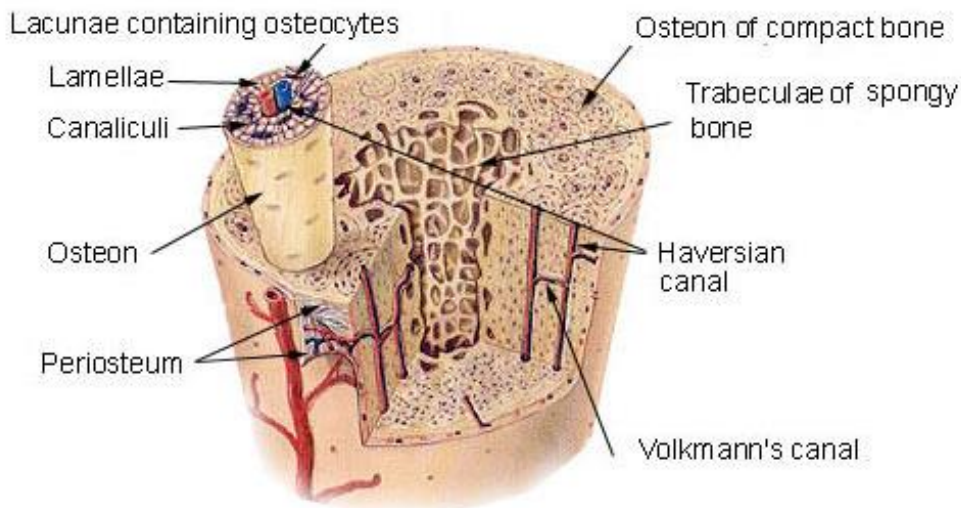
4 . 3 Layered Structure

Cortical bone

The hard outer layer of bones is composed of cortical bone also called compact bone. Cortical referring to the outer (cortex) layer. The hard outer layer gives bone its smooth, white, and solid appearance, and accounts for 80% of the total bone mass of an adult skeleton.

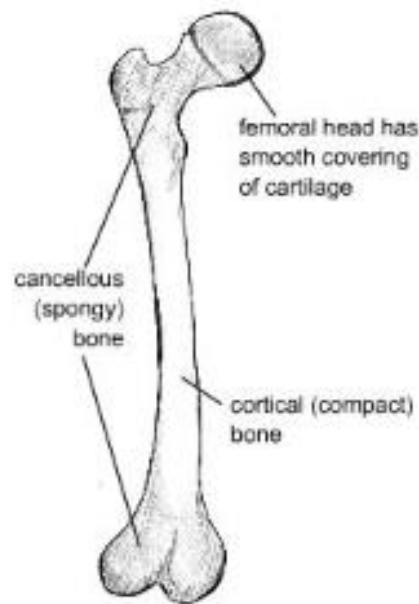
Cortical bone consists of multiple microscopic columns, each called an osteon. Each column is multiple layers of osteoblasts and osteocytes around a central canal called the Haversian canal. Volkmann's canals at right angles connect the osteons together. The columns are metabolically active, and as bone is reabsorbed and created the nature and location of the cells within the osteon will change. Cortical bone is covered by a periosteum on its outer surface, and an endosteum on its inner surface. The endosteum is the boundary between the cortical bone and the cancellous bone.

Compact Bone & Spongy (Cancellous Bone)



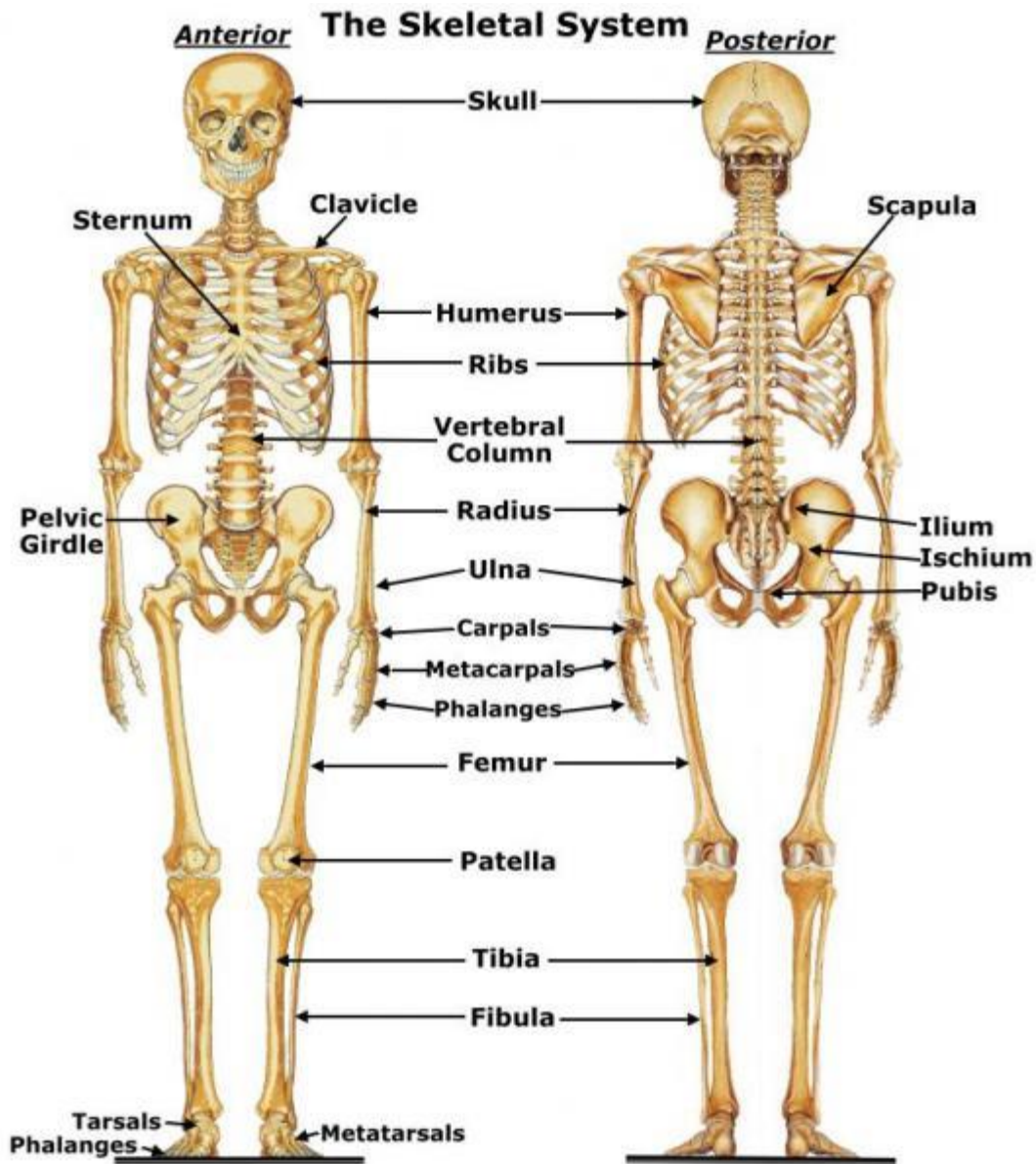
cancellous bone

Filling the interior of the bone is the cancellous bone also known as trabecular or spongy bone tissue. It is an open cell porous network. Thin formations of osteoblasts covered in endosteum create an irregular network of spaces. Within these spaces are bone marrow and hematopoietic stem cells that give rise to platelets, red blood cells and white blood cells. Trabecular marrow is composed of a network of rod- and plate-like elements that make the overall organ lighter and allow room for blood vessels and marrow. Trabecular bone accounts for the remaining 20% of total bone mass but has nearly ten times the surface area of compact bone.



Bone marrow

Bone marrow is the flexible tissue in the interior of bones. In humans, red blood cells are produced by cores of bone marrow in the heads of long bones in a process known as hematopoiesis. On average, bone marrow constitutes 4% of the total body mass of humans; in an adult weighing 65 kilograms (143 lb), bone marrow typically accounts for approximately 2.6 kilograms (5.7 lb). The hematopoietic component of bone marrow produces approximately 500 billion blood cells per day, which use the bone marrow vasculature as a conduit to the body's systemic circulation. Bone marrow is also a key component of the lymphatic system, producing the lymphocytes that support the body's immune system.



4.2 Types of Bones

The bones of the body come in a variety of sizes and shapes. The four principal types of bones are long, short, flat and irregular.

Long Bones

Bones that are longer than they are wide are called long bones. They consist of a long shaft with two bulky ends or extremities. They are primarily compact bone but may have a large amount of spongy bone at the ends or extremities. Long bones include bones of the thigh, leg, arm, and forearm.

Short Bones

Short bones are roughly cube shaped with vertical and horizontal dimensions approximately equal. They consist primarily of spongy bone, which is covered by a thin layer of compact bone. Short bones include the bones of the wrist and ankle.

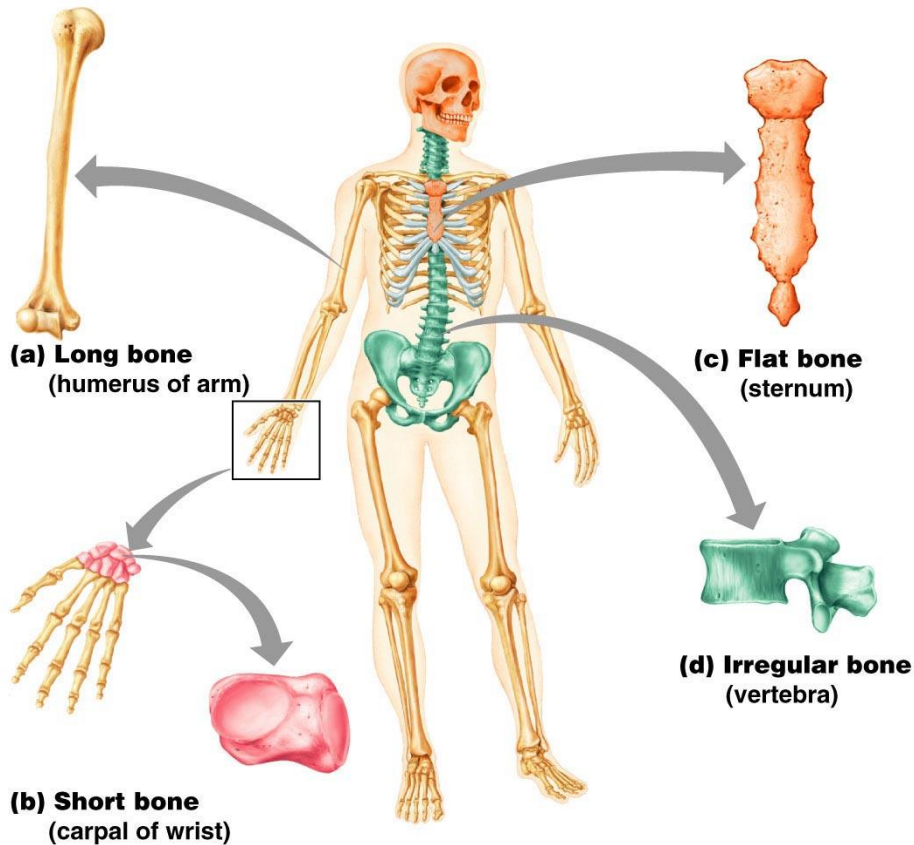
Flat Bones

Flat bones are thin, flattened, and usually curved. Most of the bones of the cranium are flat bones.

Irregular Bones

Bones that are not in any of the above three categories are classified as irregular bones. They are primarily spongy bone that is covered with a thin layer of compact bone. The vertebrae and some of the bones in the skull are irregular bones.

All bones have surface markings and characteristics that make a specific bone unique. There are holes, depressions, smooth facets, lines, projections and other markings. These usually represent passageways for vessels and nerves, points of articulation with other bones or points of attachment for tendons and ligaments.



Copyright © 2009 Pearson Education, Inc., publishing as Pearson Benjamin Cummings.

NOTE:

Sesamoid bones is not a category based on shape although tend to be short bones. A sesamoid bone is a bone that develops within a tendon. The knee cap or patella is an example.

Bones are classified into four groups according to their structure.

LONG	SHORT	FLAT	IRREGULAR
Humerus	Carpals	Skull Bones	Vertebrae
Ulna	Tarsals	Scapula	Sacrum
Femur		Ribs	Coccyx
Tibia			Facial Bones
Fibula			Jaw Bones
Metacarpals			Ear bones
Metatarsal			Hyoid Bone
Phalanges			
Radius			

4.3 Bone Tissue

Bones consist of bone tissue, a large number of blood vessels and in certain areas a rich nerve supply.

Bone tissue consists of bone cells, a non-cellular organic component and an inorganic component. The non-cellular organic component consists of very strong collagen protein fibers embedded in a jelly-like matrix called ground substance. The inorganic component consists of crystals of calcium phosphate (hydroxyapatite) which are deposited within the matrix giving bone its hardness. The non-cellular material makes up a much greater part of bone tissue than the bone cells. The collagen fibers are very tough when pulled but they bend easily; The calcium phosphate crystals are very strong and they can withstand compression, but they shatter when exposed to excessive bending or impact. The combination of these materials in bone gives it some of the useful properties of each material.

4.3.1 Bone growth and development

The terms osteogenesis and ossification are often used synonymously to indicate the process of bone formation. Parts of the skeleton form during the first few weeks after conception. By the end of the eighth week after conception, the skeletal pattern is formed in cartilage and connective tissue membranes and ossification begins.

Bone development continues throughout adulthood. Even after adult stature is attained, bone development continues for repair of fractures and for remodeling to meet changing lifestyles. Osteoblasts, osteocytes and osteoclasts are the three cell types involved in the development, growth and remodeling of bones. Osteoblasts are bone-forming cells, osteocytes are mature bone cells and osteoclasts break down and reabsorb bone.

There are two types of ossification: intramembranous and endochondral.

4.3.2.1 Intramembranous

Intramembranous ossification involves the replacement of sheet-like connective tissue membranes with bony tissue. Bones formed in this manner are called intramembranous bones. They include certain flat bones of the skull and some of the irregular bones. The future bones are first formed as connective tissue membranes. Osteoblasts migrate to the membranes and deposit bony matrix around themselves. When the osteoblasts are surrounded by matrix they are called osteocytes.

4.3.2.1 Enchondral Ossification

Endochondral ossification involves the replacement of hyaline cartilage with bony tissue. Most of the bones of the skeleton are formed in this manner. These bones are called endochondral bones. In this process, the future bones are first formed as hyaline cartilage models. During the third month after conception, the perichondrium that surrounds the hyaline cartilage "models" becomes infiltrated with blood vessels and osteoblasts and changes into a periosteum. The osteoblasts form a collar of compact bone around the diaphysis. At the same time, the cartilage in the center of the diaphysis begins to disintegrate. Osteoblasts penetrate the disintegrating cartilage and replace it with spongy bone. This forms a primary ossification center. Ossification continues from this center toward the ends of the bones. After spongy bone is formed in the diaphysis, osteoclasts break down the newly formed bone to open up the medullary cavity.

The cartilage in the epiphyses continues to grow so the developing bone increases in length. Later, usually after birth, secondary ossification centers form in the epiphyses. Ossification in the epiphyses is similar to that in the diaphysis except that the spongy bone is retained instead of being broken down to form a medullary cavity. When secondary ossification is complete, the hyaline cartilage is totally replaced by bone except in two areas. A region of hyaline cartilage remains over the surface of the epiphysis as the articular cartilage and another area of cartilage remains between the epiphysis and diaphysis. This is the epiphyseal plate or growth region.

4.3.2.1 Bone Growth

Bones grow in length at the epiphyseal plate by a process that is similar to endochondral ossification. The cartilage in the region of the epiphyseal plate next to the epiphysis continues to grow by mitosis. The chondrocytes, in the region next to the diaphysis, age and degenerate. Osteoblasts move in and ossify the matrix to form bone.

This process continues throughout childhood and the adolescent years until the cartilage growth slows and finally stops. When cartilage growth ceases, usually in the early twenties, the epiphyseal plate completely ossifies so that only a thin epiphyseal line remains and the bones can no longer grow in length. Bone growth is under the influence of growth hormone from the anterior pituitary gland and sex hormones from the ovaries and testes.

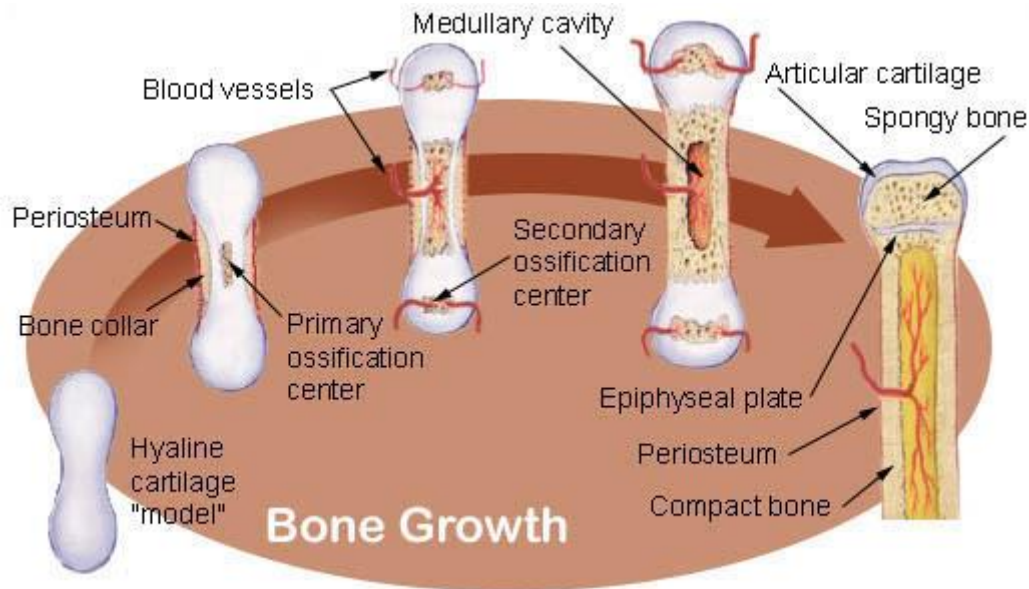


Illustration showing how a bone develops and grows

Even though bones stop growing in length in early adulthood, they can continue to increase in thickness or diameter throughout life in response to stress from increased muscle activity or to weight. The increase in diameter is called appositional growth. Osteoblasts in the periosteum form compact bone around the external bone surface. At the same time, osteoclasts in the endosteum break down bone on the internal bone surface, around the medullary cavity. These two processes together increase the diameter of the bone and, at the same time, keep the bone from becoming excessively heavy and bulky.

4.3.3 Bone ageing and disease

Although the processes involved in controlling bone growth and the maintenance of a balance between bone formation and breakdown, are known in some detail, they are not fully understood. Ageing is an important factor, as both men and women lose bone as they get older. But the rate of bone loss after the menopause is much faster in women than in men in the same age range, so we know that sex hormones are also important. The bone wasting disease known as osteoporosis occurs more frequently in post-menopausal women than in men of a similar age. This disease results in a general loss of bone, leading to weaker bone which is more prone to fracture. Exercise in old age helps to reduce this effect, by stimulating bone growth, and so being elderly is not an excuse for physical rest! When we are older our bones will be weaker because of the loss of bone and trabecular structure, but otherwise older bone generally performs as well as it used to in most respects. For instance, if broken, older bones heal as well as younger bones, although not of course as well as growing bone.

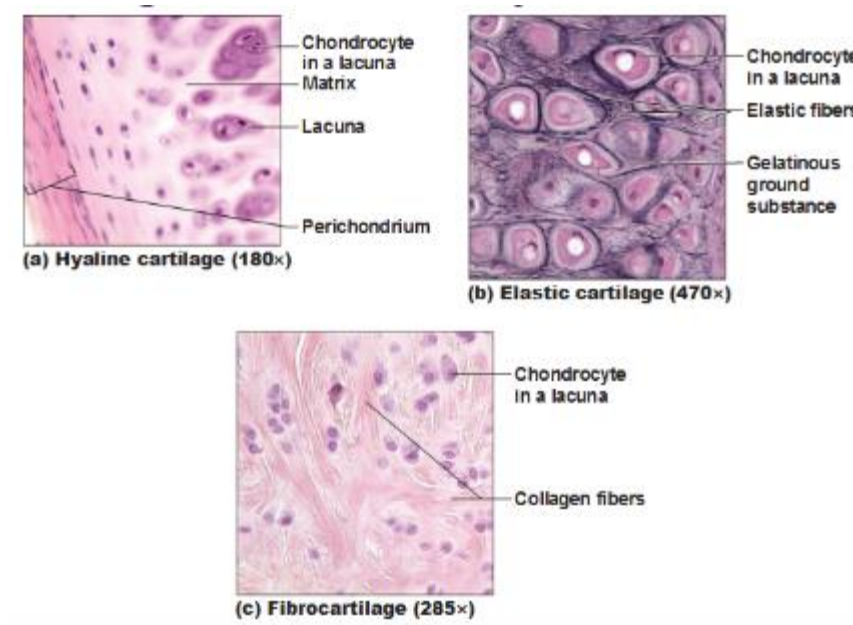
Sometimes bones maintain their organic component but not their inorganic component, so that the bone is not hard. This is known as rickets in children and osteomalacia in adults. It is generally caused by a shortage of vitamin D. It is mentioned here because it is a separate disease and should not be confused with the far commoner osteoporosis.

4.4 Cartilage

Cartilage consists of cartilage cells, fibers and ground substance. Cartilage is divided into three types according to the number and type of fibers present. Hyaline cartilage is the most abundant type of cartilage in the body. It is found lining the ends of bones and joints (articular cartilage), in the nose, trachea and lungs, and at the ends of the ribs. It contains a small number of collagen fibers, making it strong but flexible. This structure enables it to play a part in support and, at the joints, to absorb shock and reduce friction. Fibrocartilage contains very large numbers of collagen fibers making it very strong and rigid. It is found in the symphysis pubis and the intervertebral discs. Elastic cartilage contains elastic fibers making it strong and elastic. It is found in the external part of the ear, maintaining its shape. Unlike bone, cartilage has no blood supply so it takes longer to repair if damaged. It also has no nerve supply.

4.4.1 Articular cartilage

Articular cartilage is a form of hyaline cartilage which is present at the end of bones which articulate in a synovial joint. It consists of a matrix of a non-cellular material known as ground substance. Within the matrix there are cells, called chondrocytes. These cells are more densely packed in the deeper layers adjacent to the bone.



Articular cartilage is smooth and provides a low friction surface for the articulating bone ends. It has a firm consistency but is fairly pliable and has shock absorbing properties. It distributes loads evenly over a large surface area, reducing contact stress and therefore wear.

This highly specialized tissue has limited regenerative capabilities. The superficial layers of the cartilage are replaced through regeneration as they wear. However, if the deep layers of cartilage are lost in an accident, the capacity of articular cartilage to regenerate is limited. The reasons for this are not fully understood but it is probably because the deeper layers of cartilage have a higher ratio of cells to matrix and so their loss is more significant.

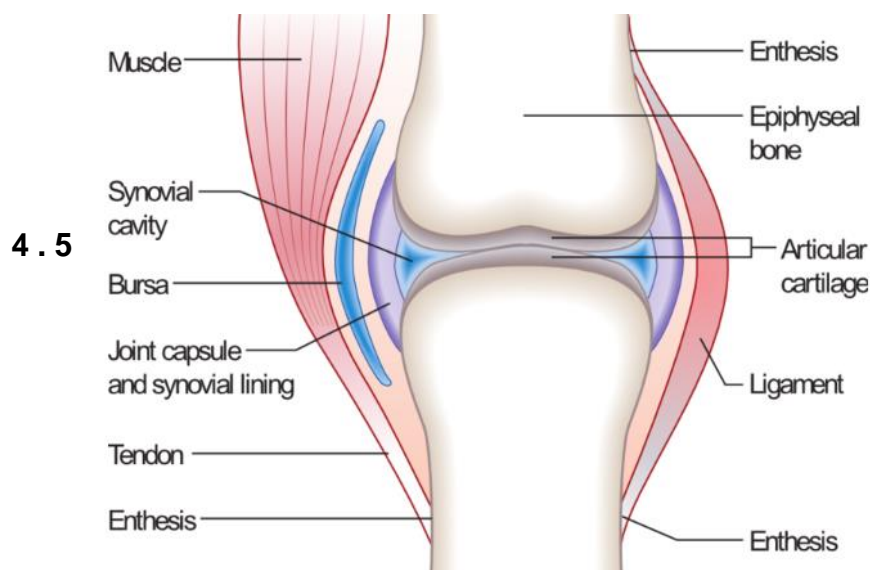
It is probable that in cases of severe cartilage loss, the repair tissue is always by a combination of collagen fibers and cartilage - fibrocartilage. The more the joint is kept moving, the greater will be the ratio of cartilage to fibrous tissue. This is probably because, as outlined above, the movement of a joint forces synovial fluid into the cartilage, supplying nutrients and removing waste. Even in the most favorable circumstances pure cartilaginous replacement is not thought to occur.

4 . 4 . 2 The Joint Capsule

A joint capsule is a thin, fibrous sac containing fluid, which encloses a joint. The fluid provides lubrication for bone movement. Most joints in the human body are freely movable and have much more complex structures than the immovable or even the slightly movable types. The articular (adjoining) ends of bones in a freely movable joint are covered with a thick layer of articular cartilage, which is resistant to wear and produces a minimum of friction when it is compressed as the joint is moved.

A tubular joint capsule that has two distinct layers holds joint bones together. The outer layer consists mostly of dense, white, fibrous connective tissue, the fibers of which are attached to the periosteum around the outside ring of each bone of the joint near its articular end. The outer fibrous layer of the capsule, therefore, completely encloses the other parts of the joint. It is flexible enough, though, to allow movement and strong enough to help prevent the articular surfaces from being pulled apart. Bundles of strong, tough collagenous fibers called ligaments reinforce the joint capsule and help to bind the articular ends of the bones together. Some ligaments appear as bulges in the fibrous layer of the capsule, while others are accessory structures located outside the capsule. In either case, these structures also prevent too much movement at the joint, because the ligament is relatively inelastic and becomes tightly drawn whenever a normal limit of movement has been achieved in the joint. The inner layer of the joint capsule consists of a shiny, vascular lining of loose connective tissue called synovial membrane. The membrane covers all of the surfaces within the joint capsule, except the areas that are covered by cartilage.

Some freely movable joints are partially or completely divided into two compartments by disks of fibrocartilage called menisci located between the articular surfaces. Such a disk is attached to the fibrous layer of the joint capsule at the sides, and its free surface projects into the joint cavity. Certain freely movable joints also have closed, fluid-filled sacs called bursae associated with them. Each bursa has an inner lining of synovial membrane, which may be continuous with the synovial membrane of a nearby joint cavity. Bursae act as cushions and aid the movement of tendons, which glide over such bony parts or over other tendons. The names of the bursae indicate their locations; for example, a suprapatellar bursa, a prepatellar bursa, and an infrapatellar bursa.

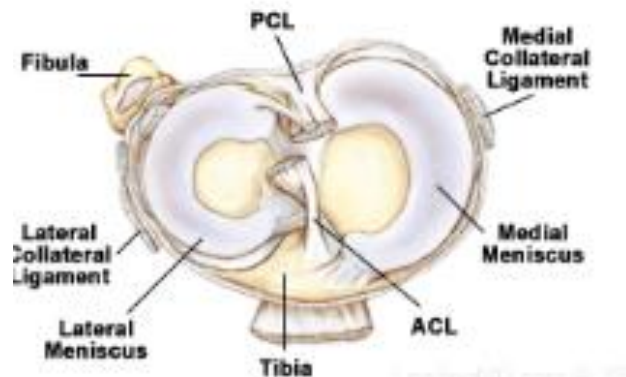


Ligaments are composed of collagen fibers arranged in more or less parallel bundles. They are attached to the bones on either side of a joint, holding the joint in place and resisting stretching forces pulling on the joints, thus providing joint stability. The position of the ligaments around a joint determines the direction in which the joint can move. They determine the axis of motion of a joint by limiting the directions in which it may move. Ligaments have a blood supply and a nerve supply. They have no regenerative powers so if they are damaged they heal by repair, forming a scar. The scar is unlikely to result in healing at the correct length, and scar tissue is liable to stretch under tension. Therefore the healing of ligaments quite often leaves a less efficient structure than the original one. If the sensory receptors and nerves in a ligament are damaged this can cause the loss of the ability to provide the central nervous system with accurate sensory information. The loss of sensory information is particularly serious as this prevents the reflex contractions of antagonist muscles to protect a joint from abnormal loads or from being placed in unsatisfactory positions.

4.6 Menisci

Some joints, the knee and the jaw for example, have small fibrocartilage structures within them which separate the cartilaginous articular surfaces. These are properly called the menisci or **articular discs**. Their function is incompletely understood, but primarily it is almost certainly load distribution, particularly where a joint is subject to a lot of rotation. This is classically seen in the knee. It is perhaps significant that the only mammal that cannot rotate its knees, the fruit bat, has no menisci. The menisci also help in distributing synovial fluid over a larger surface area but this is probably not a major function.

The medial meniscus and lateral meniscus are specialized structures within the knee. These crescent-shaped shock absorbers between the tibia and femur have an important role in the function and health of the knee. Once thought to be of little use, the menisci (plural) were routinely removed when torn. Now we know that the menisci contribute to a healthy knee because they play important roles in joint stability, force transmission, and lubrication.



4.7 Joints

Joints, also called **articulations**, are the regions of contact between bones. They hold the bones together and some allow movement to take place. They are classified into three types according to their structure and degree of mobility.

A joint or articulation (or articulate surface) is the location at which bones connect. They are constructed to allow movement (except for skull, sacral, sternal, and pelvic bones) and provide mechanical support, and are classified structurally and functionally.

Structural classification is determined by how the bones connect to each other, while functional classification is determined by the degree of movement between the articulating bones. In practice, there is significant overlap between the two types of classifications.

Structural classification (binding tissue)

Structural classification names and divides joints according to the type of binding tissue that connects the bones to each other. There are three structural classifications of joints:

- fibrous joint – joined by dense regular connective tissue that is rich in collagen fibers
- cartilaginous joint – joined by cartilage
- synovial joint – not directly joined – the bones have a synovial cavity and are united by the dense irregular connective tissue that forms the articular capsule that is normally associated with accessory ligaments.

Functional classification (movement)

Joints can also be classified functionally according to the type and degree of movement they allow:

- synarthrosis – permits little or no mobility. Most synarthrosis joints are fibrous joints (e.g., skull sutures).
- amphiarthrosis – permits slight mobility. Most amphiarthrosis joints are cartilaginous joints (e.g., intervertebral discs).
- diarthrosis – freely movable. All diarthrosis joints are synovial joints (e.g., shoulder, hip, elbow, knee, etc.), and the terms "diarthrosis" and "synovial joint" are considered equivalent. Diarthroses can in turn be classified into six groups according to the type of movement they allow: arthrodia, enarthrosis, ginglymus, rotary diarthrosis, condyloid articulation and articulation by reciprocal reception.

4.7.1 Synovial joints - general structure

A synovial joint, also known as diarthrosis, is the most common and most movable type of joint in the body of a mammal. As with most other joints, synovial joints achieve movement at the point of contact of the articulating bones.

Synovial fluid - the synovial fluid fills the synovial capsule and has three functions:

1. Lubrication of the joint surfaces to reduce friction. The synovial fluid is circulated around the joint by the movement of the joint
2. Nutrition of the articular cartilage. It is thought that the articular cartilage gains its nutrition from two sources: partly from the blood supply from the bone under the cartilage but mainly through minute fissures reaching the depths of the cartilage layer from the surface. Via this latter route synovial nutrients are forced into the fissures when the joint moves.
3. Removal of waste materials from the tissues of the joint.

Synovial joints contain the following structures:

- **Synovial cavity:** all diarthroses have the characteristic space between the bones that is filled with synovial fluid
- **Articular capsule:** the fibrous capsule, continuous with the periosteum of articulating bones, surrounds the diarthrosis and unites the articulating bones; the articular capsule consists of two layers - (1) the outer fibrous membrane that may contain ligaments and (2) the inner synovial membrane that secretes the lubricating, shock absorbing, and joint-nourishing synovial fluid; the articular capsule is highly innervated, but avascular (lacking blood and lymph vessels), and receives nutrition from the surrounding blood supply via either diffusion (a slow process) or by convection, a far more efficient process achieved through exercise
- **Articular cartilage:** the bones of a synovial joint are covered by this layer of hyaline cartilage that lines the epiphyses of joint end of bone with a smooth, slippery surface that does not bind them together; articular cartilage functions to absorb shock and reduce friction during movement

•

There are six types of synovial joints. Some are relatively immobile, but are more stable. Others have multiple degrees of freedom, but at the expense of greater risk of injury. In ascending order of mobility, they are:

Name	Example	Description
Gliding joints (or plane joints)	carpals of the wrist, acromioclavicular joint	These joints allow only gliding or sliding movements, are multi-axial such as the articulation between vertebrae.
Hinge joints	elbow (between the humerus and the ulna)	These joints act as a door hinge does, allowing flexion and extension in just one plane
Pivot joints	atlanto-axial joint, proximal radioulnar joint, and distal radioulnar joint	One bone rotates about another
Condyloid joints (or ellipsoidal joints)	wrist joint (radiocarpal joint)	A condyloid joint is where two bones fit together with an odd shape (e.g. an ellipse), and one bone is concave, the other convex; some classifications make a distinction between condyloid and ellipsoid joints; ^{[4][5]} these joints allow flexion, extension, abduction, and adduction movements (circumduction).
Saddle joints	Carpometacarpal or trapeziometacarpal joint of thumb (between the metacarpal and carpal - trapezium), sternoclavicular joint	Saddle joints, which resemble a saddle, permit the same movements as the condyloid joints but allow greater movement
Ball and	shoulder (glenohumeral) and	These allow for all movements except gliding

socket joints	hip joints	
"universal Joint"		
Compound joints / modified hinge joints	knee joint	condylar joint (condyles of femur join with condyles of tibia) and saddle joint (lower end of femur joins with patella)

4 . 8 Joint Stability

Immobile and slightly mobile joints are very stable - they do not allow the bones to move out of their correct position. Synovial joints must allow the bones to move relative to each other but must also maintain the bones in their correct position in the joint. The stability of synovial joints is determined by:

- ◆ the shape of the bone surfaces in the joint
- ◆ the arrangement of ligaments around the joint
- ◆ the muscles (or tendons of muscles) which cross the joint

Immobile joints

The bones are held firmly together by short collagen fibers. These joints are known as **fibrous joints** and allow no movement. Examples are found in the skull and at the distal ends of the tibia and fibula (the distal tibio-fibular joint).

Slightly mobile joints

The bones are held together by fibrocartilage. These joints are known as cartilaginous joints. Examples are found between the vertebrae and between the innominate bones of the pelvis. The latter joint is called the symphysis pubis and it allows a little "give" which is desirable, particularly when giving birth!

Very mobile joints

The bones are held together by ligaments and muscles. The bones may also be shaped to fit well together at the joint thus helping to hold the bones in place but also allowing certain types of movement. These joints are called synovial joints (see Figure 12) and allow a wide range of movements. Examples of this type are the hip and knee joints. The ends of the bones in a synovial joint are covered with articular cartilage. A sleeve of tough fibrous material called the capsule is attached to the bones and encloses the joint. The inner layer of the capsule is lined with a synovial membrane which produces synovial fluid. The synovial fluid fills the synovial cavity, lubricating the joint and providing nutrients to the articular cartilage. These joints in particular allow us the movement that is not only a major factor in our survival but also a prime source of our enjoyment of life.

4 . 9 Joint Complications

A living joint has the capacity to regenerate its surface in response to wear and to restore a smooth articulating surface after damage, provided that the damage is superficial. The mechanism of repair is dependent on a good blood supply to the deeper layers of the cartilage and on nutrition from the synovial fluid.

In certain situations this balance of wear and repair breaks down - There is either too much wear or too little repair. This is of course a simplistic way of describing the problem but it serves as a useful way of thinking about joint diseases such as arthritis. Arthritis is a word which only really

means "joint disease" but has come to mean a wearing of the joint. It is commoner in old age, but not all old people have arthritis. Therefore arthritis is not inevitably caused by joints ageing. The truth is that we do not know why arthritis occurs in most cases. In general, as wear is the same in those with arthritis as those without, then the problem must lie with the repair process. Despite much research in this field, the cause of this breakdown of normal repair is still obscure.

When the cause of arthritis is unknown it is termed PRIMARY arthritis. There are, of course, known physical and pathological factors that contribute to arthritis. These factors are generally related to damage, where wear is more easily recognized and understood. Such arthritis is known as SECONDARY arthritis. Secondary arthritis may be caused by:

- ◆ birth abnormalities - e.g.. congenital dislocation of the hip,
- ◆ inflammatory changes - e.g.. tuberculosis; untreated infection; rheumatoid arthritis,
- ◆ metabolic upsets - e.g.. gout, and trauma - e.g.. a badly united fracture involving a joint.

5. THE MUSCULAR SYSTEM

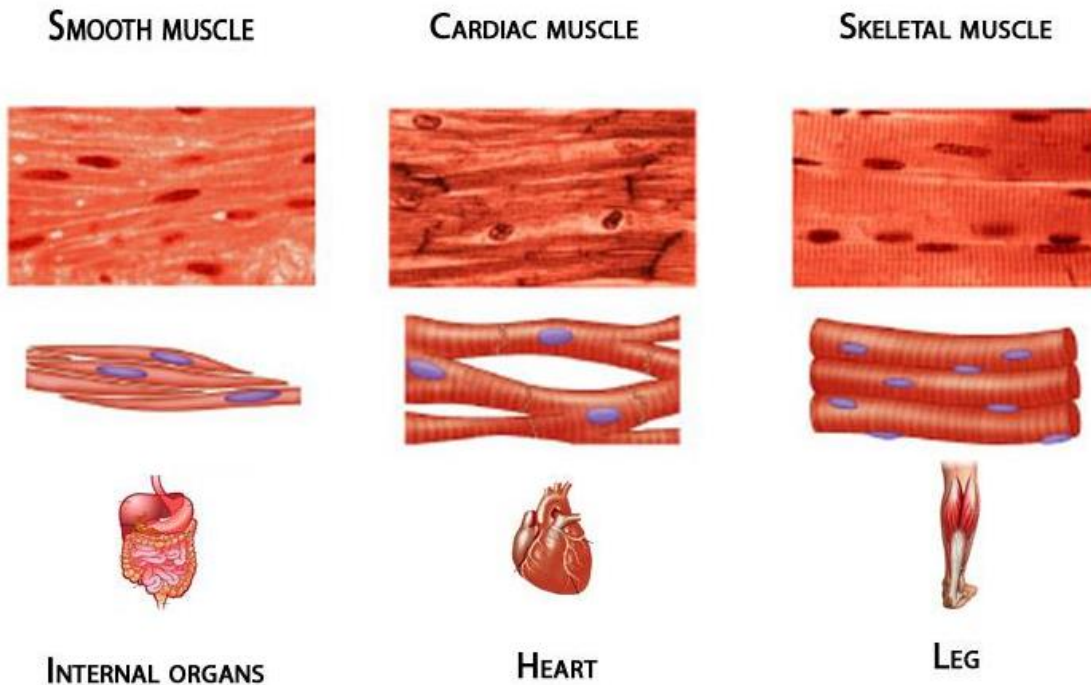
The muscular system consists of the muscles and their associated tissues such as tendons. If any part of your body moves, muscle moves it. The main function of the muscular system is to cause movement.

5 . 1 Types of Muscle Tissue

Muscle tissue may be classified into three types depending on the structure of its cells and its function.

1. Smooth muscle tissue is not involved with locomotion. Its main action is to provide low power rhythmic contractions over long periods of time. For example, in the digestive system smooth muscles are found in the walls of the gut providing the contractions needed to push food materials along its length. In the cardiovascular system, smooth muscle is found in the walls of blood vessels where it plays a part in controlling blood flow.
2. Skeletal muscle tissue is found in skeletal muscles. Skeletal muscles make up 30-40% of body weight and are responsible for movement and controlling body posture. It is also called striated muscle because the cells appear striped under the microscope due to the alignment of the filaments (tiny fibers) within the cells. Smooth muscle does not have these "stripes".
3. Cardiac muscle tissue is found in the wall of the heart. It is striated but the shape and arrangement of the muscle cells is different from skeletal muscle tissue. The function of cardiac muscle is to contract regularly causing the heart to pump.

We do not have voluntary control over the actions of smooth muscle and cardiac muscle in the same way as we control the actions of skeletal muscles.



5.2 Skeletal Muscles

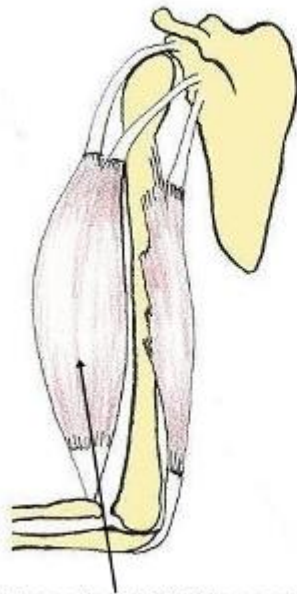
Muscles produce forces which maintain posture as well as producing movement from place to place (locomotion). Muscles also produce heat when they are active and this is used to maintain body temperature.

A muscle causes movement when it contracts and shortens, pulling on the bones to which it is attached. This pull results in movement at the joint between the bones. The muscles that produce movement at a joint are connected to the bones on either side of the joint - they are said to cross the joint. Some muscles cross more than one joint so contraction of these muscles can cause movement at both joints. In most cases the body of the muscle itself does not lie across the joint. It is usually on the proximal side of the joint and is connected to the distal bone by a long narrow structure known as a tendon. The tendon consists of tough fibrous tissue. If the attachment of a muscle to bone is by a short, wide, sheet-like fibrous tissue structure, the attachment is called an aponeurosis).

One end of a muscle's attachment to bone is called the origin and the other end the insertion. The origin is always on the less mobile bone and the insertion is always on the more mobile bone. For the limbs this means that the origin of a muscle is always proximal and the insertion distal.

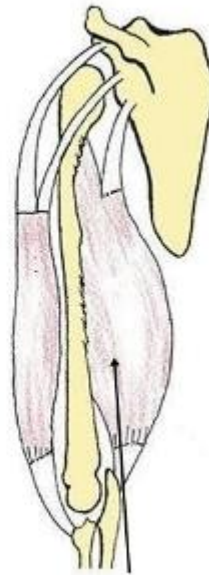
The movement of any of the major joints involves the coordinated action of many muscles. Those involved in producing the movement are called agonists while those opposing the movement (causing the opposite movement) are called antagonists. The most powerful muscle causing movement in a particular direction is called the prime mover.

Agonist



The biceps brachii is the agonist which flexes the elbow.

Antagonist



The triceps is the antagonist which resists flexion and extends the elbow.

6. THE NERVOUS SYSTEM

The nervous system consists of the brain and spinal cord, the nerves and sensory organs and associated tissues. The functions of the nervous system are communication, sorting of information and control of body functions.

6.1 Divisions of the Nervous System

The nervous system is divided into:

CNS - the central nervous system. This consists of the brain and the spinal cord. The spinal cord carries information to the brain from the periphery and vice versa, and is responsible for reflexes. The brain controls and coordinates the activities of the body.

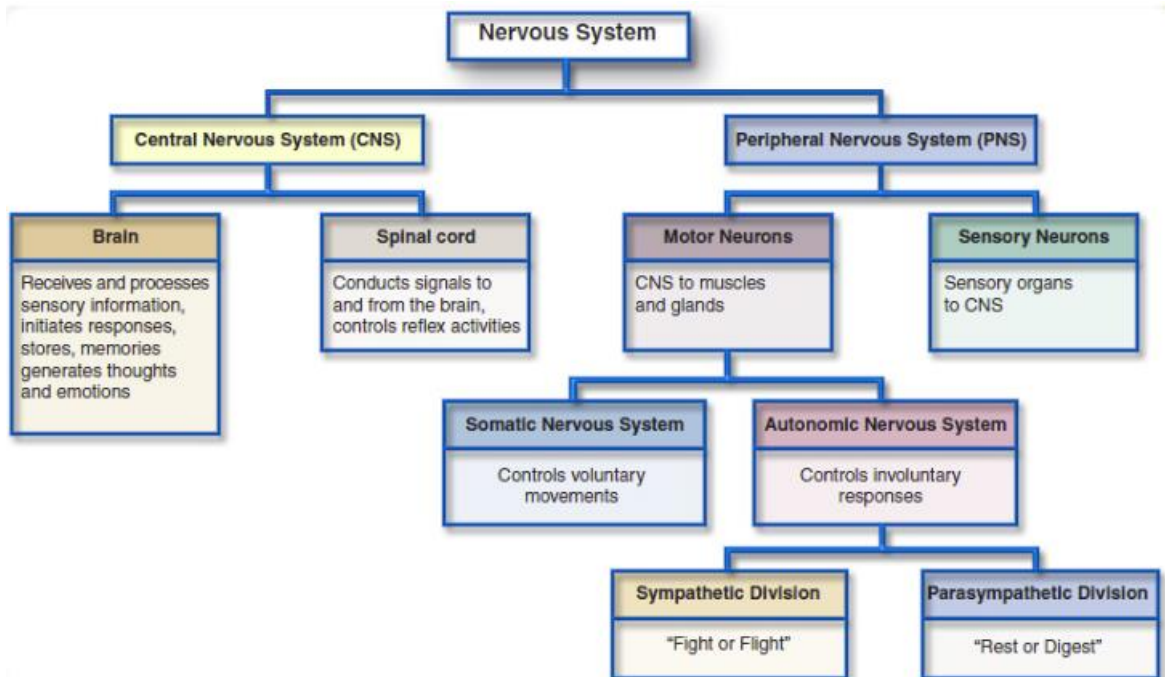
PNS - the peripheral nervous system. This consists of all the parts of the nervous system outside the CNS, i.e. the nerves and the sensory organs. The PNS detects stimuli from the environment and carries the information to the CNS, then carries signals from the CNS to the muscles, invoking a response.

6.2 Types of Nerves

Nerves can be classified into two types:

Sensory nerves bring signals from sensory receptors in the periphery and pass information to the central nervous system.

Motor nerves carry signals to the muscles from the brain.



7. THE CARDIOVASCULAR SYSTEM

The cardiovascular system consists of the heart, blood vessels and the blood. The heart pumps the blood in the blood vessels round the body. The function of this system is transport: moving important substances such as oxygen, nutrients and hormones to the tissues and taking waste substances such as carbon dioxide away.

7.1 The Heart

The heart is a four chambered organ with a wall of cardiac muscle. When the muscular wall contracts, the heart "beats" and blood in the chambers of the heart is pumped out into the blood vessels and round the body.

7.2 Blood vessels

There are three types of blood vessel:

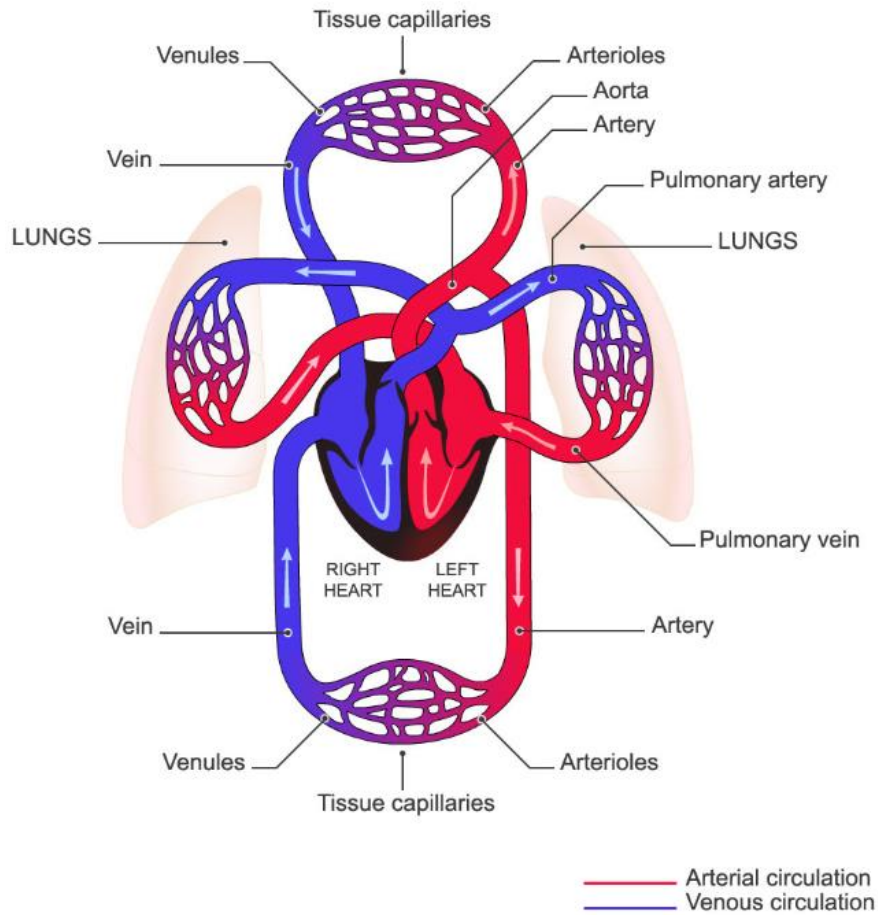
Capillaries are microscopic blood vessels 5-20 um (micrometers, thousandths of a millimetre) in diameter which form networks in the tissues of the body. The wall of a capillary is only one cell thick so substances can move rapidly in and out of the tissues.

Arteries transport blood away from the heart. The major arteries branch into smaller and smaller arteries which then branch into smaller and smaller vessels called arterioles which connect with the capillary network.

Veins transport blood towards the heart. Capillaries connect with very small veins called venules which connect with larger and larger veins which connect with the major veins.

7.3 Blood

Blood consists of a fluid (plasma) containing dissolved substances and cells (red blood cells, white blood cells and platelets). Red blood cells transport oxygen, white blood cells are involved in defense against microorganisms and platelets are involved in forming blood clots after injury. Red blood cells are formed in bone marrow.



SUMMARY

This unit has introduced you to the basic concepts required to study the structure and function of the skeletal system. It has included some aspects of the muscular system and the nervous and cardiovascular systems, as these systems are also of importance in skeletal anatomy and physiology.

GLOSSARY

Anatomy and Physiology- Levels of organization

cells
tissues
organs
systems
anatomical position
transverse plane
coronal plane
sagittal plane
median plane
bone functions
shoulder girdle
upper arm
forearm
wrist
hand
pelvic girdle
thigh
leg
ankle
foot
types of bone
bone cells
collagen fibres
ground substance
calcium phosphate
Haversian system
lamellae
lacunae
canaliculi
trabeculae
ossification
membranous
enchondral
articular cartilage
epiphyseal plate
germinal layer
osteoporosis
rickets
osteomalacia
hyaline cartilage
fibrocartilage
chondrocytes
menisci
articular discs
joints
immobile joints
slightly immobile joints
very mobile joints
synovial joints
synovial fluid
synovial membrane
joint movement and stability
arthritis
smooth muscle
skeletal muscle
cardiac muscle
tendon
origin
insertion
agonists
antagonists
prime mover
central nervous system
peripheral nervous system
sensory nerves
motor nerves
the heart
capillaries
artery
vein
blood

SKELETAL ANATOMY & PHYSIOLOGY

UNIT I – Part 2

Regional Anatomy

UNIT 1 – Section Objectives

At the end of this unit you should be able to:

1. List the bones and joints of the pelvic girdle.
2. Describe how the bones, ligaments and joints of the pelvis co-operate to stabilize the pelvic girdle.
3. Name the major bones of the lower limb.
4. Describe the following features of the hip, knee and ankle joints: stability, axes of movement type of movement blood supply
5. Describe the major muscles in each limb segment and identify the prime movers of each type of movement of the hip, knee and ankle.
6. Name the three major peripheral nerves of the lower limb and which muscle groups they supply.
7. Describe the role of the patella.
8. Describe how the knee ligaments stabilize the joint and how their destruction disrupts normal knee movement.
9. Describe the shape of the foot and list the major bones.
10. Describe the axis of the subtalar joint and its movement of inversion and eversion.
11. Describe the first metatarsophalangeal joint and how deformities lead to the formation of bunions.
12. List the three main bones and three main joints of the upper limb.
13. Describe the shoulder girdle.
14. Discuss how the scapulo-thoracic and gleno-humeral joints work together to allow shoulder movement.
15. Describe the following features of the shoulder, elbow and wrist joints: stability axes of movement type of movement
16. Describe the major muscle groups in each limb segment for each type of movement of the shoulder, elbow and wrist and digits.
17. Name the three major peripheral nerves of the upper limb and the muscle groups which they supply.
18. Describe the role of tendons in operating the hand.
19. Describe the function of the thumb.
20. List the four regions of the spine.
21. Describe the general shape and construction of the vertebral column.
22. Describe the movement of each of the regions of the spine.
23. Describe the structures which stabilize the spine and determine posture.

24. List the functions of the spine.
25. Describe the structure and shape of a typical vertebra.
26. Describe the structure and function of an intervertebral disc.
27. Describe a motion segment.
28. Describe how the limb girdles and ribs attach to the spine.

UNIT 1 – Regional Anatomy

A. THE LOWER LIMB

1. STRUCTURE AND FUNCTION OF THE LOWER LIMB

- 1.1 Function
- 1.2 General Layout

2. THE PELVIC GIRDLE

- 2.1 Function
- 2.2 Structure
- 2.3 Stability

3. THE HIP JOINT

- 3.1 Stability
- 3.2 Type of Movement
- 3.3 Classification of Muscle Action
- 3.4 Muscles
 - 3.4.1 Abductors
 - 3.4.2 Adductors
 - 3.4.3 Flexors
 - 3.4.5 Extensors
- 3.5 Nerve Supply
- 3.6 Blood Supply

4. THE KNEE JOINT

- 4.1 Structure
- 4.2 Stability
- 4.3 Types of Movement
- 4.4 Muscles
 - 4.4.1 Extensors
 - 4.4.2 Flexors

5. THE ANKLE JOINT

- 5.1 Stability
- 5.2 Axes of Movement
- 5.3 Types of Movement
- 5.4 Muscles
 - 5.4.1 Plantarflexors
 - 5.4.2 Dorsiflexors
- 5.5 Blood Supply

6. THE FOOT

- 6.1 Shape and Stability
- 6.2 Bones of the Foot
- 6.3 Subtalar joint
- 6.4 First Metatarsophalangeal Joint

B. THE UPPER LIMB

7. STRUCTURE AND FUNCTION OF THE UPPER LIMB

- 7.1 Function
- 7.2 General Layout
- 7.3 Shape

8. THE SHOULDER GIRDLE

- 8.1 Function
- 8.2 Structure

9. THE SHOULDER JOINT

- 9.1 General Structure
- 9.2 Stability
- 9.3 Axes of Movement
- 9.4 Types of Movement
- 9.5 Muscles
- 9.6 Examples of Muscle Activity
- 9.7 Nerve Supply

10. THE ELBOW JOINT

- 10.1 General Structure
- 10.2 Stability
- 10.3 Axes of Movement
- 10.4 Type of Movement
- 10.5 Muscles
- 10.6 Examples of Muscle Activity

11. THE WRIST JOINT

- 11.1 General Structure
- 11.2 Stability
- 11.3 Axes of Movement
- 11.4 Type of Movement
- 11.5 Muscles
- 11.6 Examples of Muscle Activity
- 11.7 Nerve Supply

12. THE HAND

- 12.1 Shape and Stability
- 12.2 Bones and Joints
- 12.3 Tendons
- 12.4 The Thumb

C. THE SPINE

13. STRUCTURE AND FUNCTION OF THE SPINE

- 13.1 General Structure and Function
- 13.2 Shape of the Spine
- 13.3 Movement
- 13.4 The Skull, the Ribs and the Limb Girdles

14. THE REGIONS OF THE SPINE

- 14.1 Cervical
- 14.2 Dorsal (thoracic)
- 14.3 Lumbar
- 14.4 Sacrum and Coccyx

15. THE VERTEBRAE

- 15.1 A Typical Vertebra
- 15.2 The Intervertebral Disc

16. SPINAL STABILITY

- 16.1 Muscles
- 16.2 Ligaments
- 16.3 Facet joints

17. THE SPINAL CORD

- 17.1 General Structure and Function
- 17.2 Nerve Roots

SUMMARY

GLOSSARY

UNIT 2 – Regional Anatomy

In this unit you will review the anatomy and physiology of the following regions of the body: **(1) the lower limb, (2) the upper limb and the (3) spine.**

A. THE LOWER LIMB

This is the part of the body below, and including, the hip joint, commonly known as the "leg". The section starts by describing the main features of the lower limb and pelvic girdle. (The pelvic girdle is included in the unit because it forms one side of the hip joint and because it has a crucial role in the functioning of the lower limb). The hip and knee joints and their associated muscles are then studied in detail. The section concludes with less detailed sub-sections on the ankle and foot.

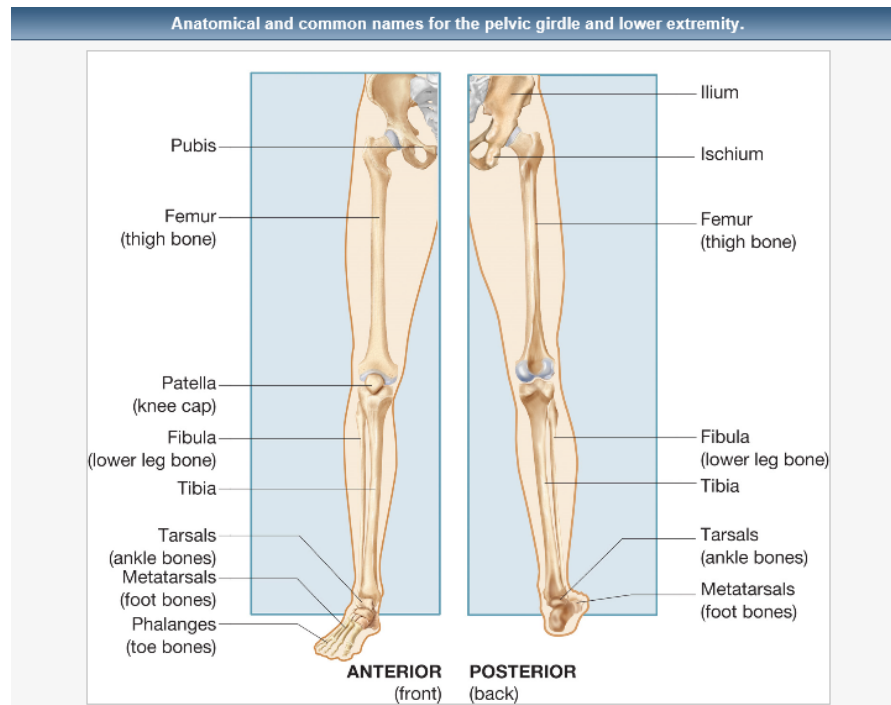
1. STRUCTURE & FUNCTION OF THE LOWER LIMB

1.1 Function

The lower limb consists of four major parts: a girdle formed by the hip bones, the thigh, the leg, and the foot. It is specialized for the support of weight, adaptation to gravity, and locomotion. The lower limbs (or lower extremities) are responsible for carrying and propelling the rest of the body. The lower extremity helps in maintaining our upright posture

The lower limb generates great power through the action of its muscles and at the same time keeps the body balanced. This means that the muscle action must be highly organized and coordinated. If the lower limb is damaged by disease or injury, full mobility will only return *if both* coordination and muscle power are restored during healing.

1.2 General Layout



<http://biology-forums.com/index.php?action=gallery;sa=view;id=8791>

The **lower limb** consists of three segments: the **thigh**, the **leg**, and the **foot**.

Note the medical meaning of the term "leg". The hip, knee and ankle joints define the ends of these segments and allow them to move. The gastrocnemius is posterior and the tibia (crest) is the anterior part of the leg.

The pelvic girdle (commonly known as the pelvis) consists of a large ring of bone at the base of the backbone. It forms a firm foundation for the powerful muscles which help make the body move forwards and upwards when we walk, run and jump. The socket side of the hip joint is a part of the pelvic girdle.

2. THE PELVIC GIRDLE

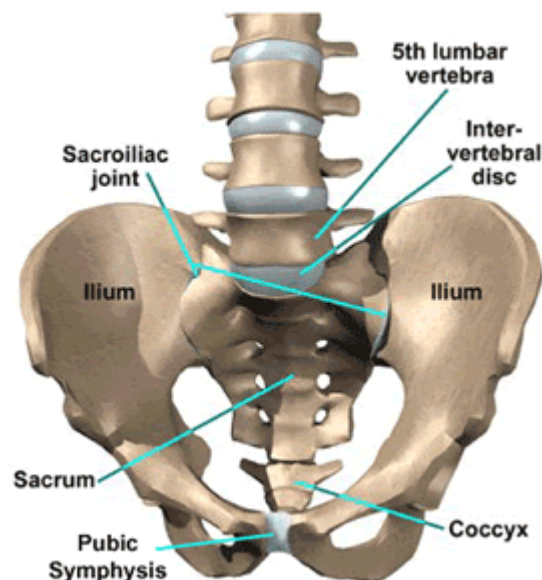
2.1 Function

This is a ring of bone, joints and ligaments which:

- ◆ acts as the anchor for muscles which move the hip and knee joints
- ◆ transmits the load on the backbone to the lower limb
- ◆ provides a platform for the soft contents of the abdomen
- ◆ provides protection for important structures including the bladder and (in the female) the organs of reproduction

2.2 Structure

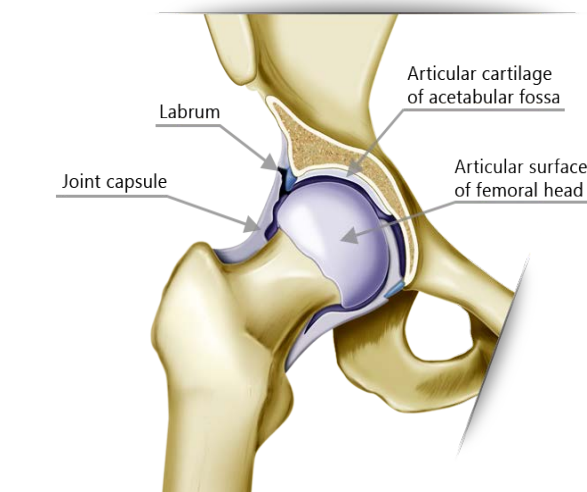
The pelvic girdle (illustrated below) is made up of three bones: the sacrum and the two innominate bones (innominate literally means "no name!"). The sacrum is part of the spinal column (or backbone, or vertebral column) and is joined to each innominate bone by a fibrous joint. The two innominate bones are joined together at the front by a cartilaginous joint, known as the symphysis pubis, which permits a degree of "play" between the two innominate bones but essentially holds them together.



This combination of three bones and three joints forms a ring which has a small degree of flexibility. The flexibility or "give" helps the pelvic girdle to withstand stresses. It is interesting that prior to childbirth changes occur in the body that increase this "give" in the pelvis.

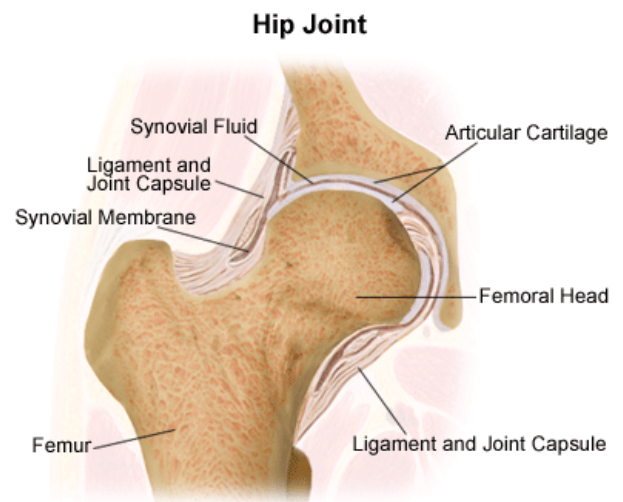
3. THE HIP JOINT

The hip joint (illustrated below) is a synovial joint between the innominate bone of the pelvic girdle and the proximal end of the femur. It is in the form of a "ball and socket". The socket is called the acetabulum and the ball consists of the head of the femur.



<http://nydnrehab.com/what-we-treat/hip-pain/hip-groin-pain/>

<http://bahriortho.com/total-hip-replacement.php>



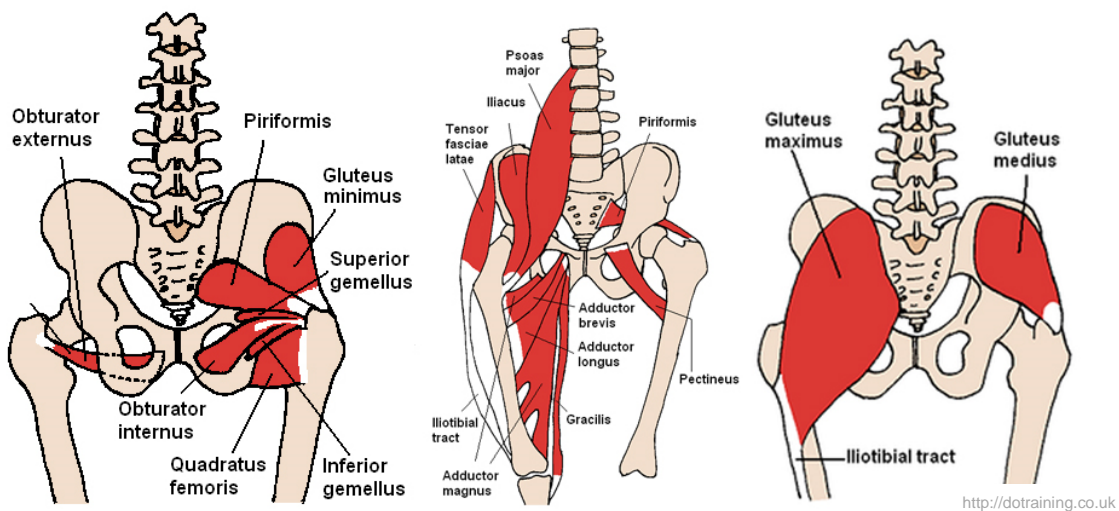
3.1 Stability

Three factors contribute to hip joint stability:

- ◆ Shape,
- ◆ Ligaments, and
- ◆ Muscles.

The shape of the joint makes it stable. A ball and socket construction is the best configuration for both stability and variety of directions movement.

Ligaments are also important for the stability of the hip joint but are secondary to the shape. The ligaments are particularly strong around the anterior and inferior sides of the joint (*illustrated below*). This means that the head of the femur is most likely to dislocate by being forced backwards out of the acetabulum. Even to do this requires a lot of force and traumatic hip dislocation is rarely seen except after serious road traffic accidents.



Finally the joint is covered in a thick layer of **muscles** which will be described in detail later. Although the primary function of these muscles is to cause movement of the lower limb, they make an important contribution to the stability of the hip.

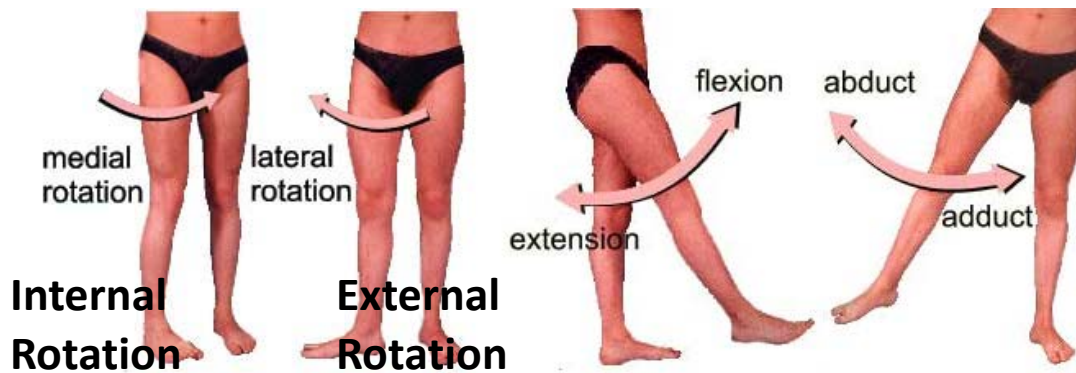
The result of these factors is a joint that is very stable over a wide range of angular movement. This is an essential requirement because of the large propulsive forces that the muscles in that area impart to the body.

3.2 Type of Movement

When we describe hip joint motion in terms of planes the following names are used:

- ◆ **Flexion** - rotation of the femur so it swings forwards in the sagittal plane
- ◆ **Extension** - rotation of the femur so it swings backwards in the sagittal plane
- ◆ **Abduction** - rotation of the femur so it swings laterally in the coronal plane
- ◆ **Adduction** - rotation of the femur so it swings medially in the coronal plane

- ◆ **Internal rotation** - rotation of the femur about its long axis resulting in the knee cap pointing inwards
- ◆ **External rotation** - rotation of the femur about its long axis resulting in the knee cap pointing outwards
- ◆ **Circumduction** - movement of the distal femur in a circle without internal or external rotation taking place. In a large circumduction the hip moves through the following positions: flexed - abducted - extended - adducted.



<http://nritarutya.com/know-hip/>

The actual angular ranges of these different motions are not important to remember at this stage. However, as an aid to diagnosis, if one hip has a smaller range of movement than the other then there is likely to be something significantly wrong with one of the joints.

3.3 Classification of Muscle Action

The movements described above are achieved by the muscles crossing the joint. Such muscles can be regarded as the "motors" of the joint. Many of these muscles act to produce a movement that does not lie exactly in one of the anatomical planes. For example one muscle may simultaneously flex and abduct resulting in motion in a plane somewhere between the sagittal and coronal planes (i.e. the motion takes place in both planes).

Most muscles act more powerfully in one anatomical plane and less powerfully in the others. In the plane where the muscle is less powerful, motion is generated with assistance from other muscles. The most powerful muscle contributing to a movement in a particular direction is known as the prime mover. For any other directions it will be a secondary mover. For example the psoas is the prime flexor of the hip and the quadriceps is a secondary hip flexor and the prime extensor of the knee.

Remember that if a muscle crosses two joints, it will tend to cause motion of both joints. For example, the hamstrings cross the hip and the knee. If they contract alone they will extend the hip and flex the knee. In practice other muscles may contract to prevent the knee flexing as the hamstrings contract to extend the hip. When muscles act against each other in this way to prevent a movement they are called antagonists. On the other hand when muscles act alone or in combination to produce a movement they are called agonists.

3.4 Muscles

3.4.1 Abductors

Gluteus Maximus

The gluteus maximus is the largest of the gluteal muscles. It is also the most superficial, producing the shape of the buttocks.

- **Attachments:** Originates from the gluteal (posterior) surface of the ilium, sacrum and coccyx. It slopes across the buttock at a 45 degree angle, then inserts into the iliotibial tract and gluteal trochanter of the femur.
- **Actions:** It is the main extensor of the thigh, and assists with lateral rotation. However, it is only used when force is required, such as running or climbing.
- **Innervation:** Inferior gluteal nerve.

Gluteus Medius

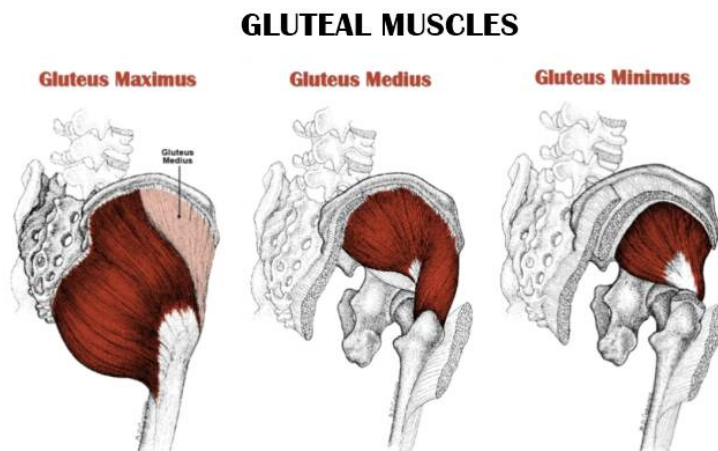
The gluteus medius muscle is fan shaped and lies between the gluteus maximus and the gluteus minimus. It is similar in shape and function to the gluteus minimus.

- **Attachments:** Originates from the gluteal surface of the ilium and inserts into the lateral surface of the greater trochanter.
- **Actions:** Abducts and medially rotates the lower limb. During locomotion, it secures the pelvis, preventing pelvic drop of the opposite limb.
- **Innervation:** Superior gluteal nerve.

Gluteus Minimus

The gluteus minimus is the deepest and smallest of the superficial gluteal muscles. It is similar in shape and function to the gluteus medius.

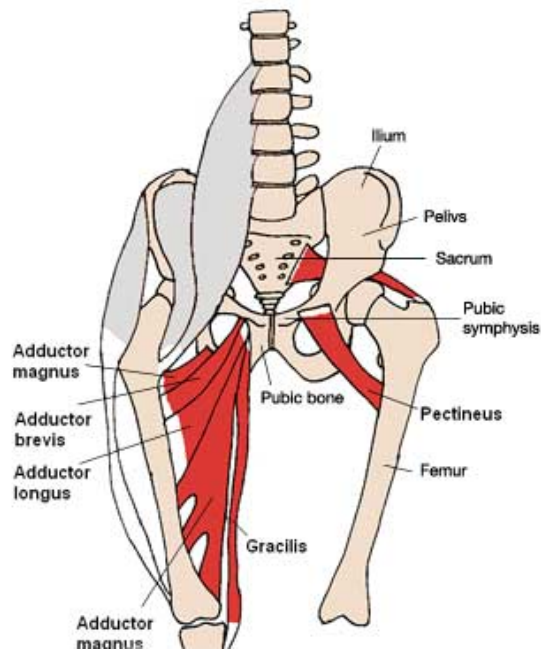
- **Attachments:** Originates from the ilium and converges to form a tendon, inserting to the anterior side of the greater trochanter.
- **Actions:** Abducts and medially rotates the lower limb. During locomotion, it secures the pelvis, preventing pelvic drop of the opposite limb.
- **Innervation:** Superior gluteal nerve.



3.4.2 Adductors

The primary adductors of the hip joint are named according to their length and size. They are the **adductor longus**, **adductor brevis** and **adductor magnus** (*illustrated below*). They are also secondary internal rotators of the femur.

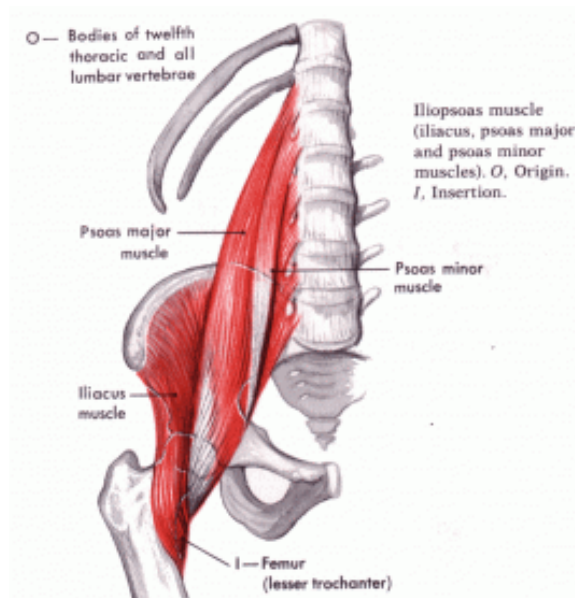
<https://www.blendspace.com/lessons/DFQSHYZall8IA/hip-adductors-adduction>



3.4.3 Flexors

The prime flexors of the hip joint are the iliacus and psoas muscles which act as a single unit known as the iliopsoas (*illustrated below*).

<http://blog.endevr.com/2013/11/08/recovery-of-a-hip-flexor-strain/>

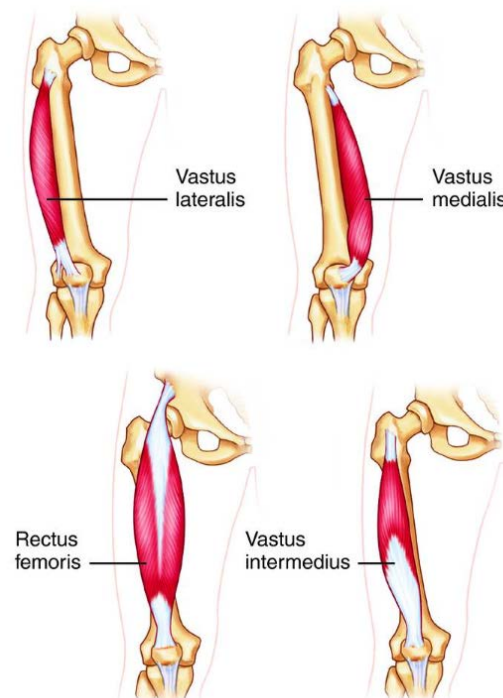


The quadriceps muscle group is made up of two muscles: the rectus femoris and the three parts of the vastus (*illustrated below*). The quadriceps is only a secondary flexor of the hip because it is not well placed to do this strongly.

The quadriceps is subdivided into four separate portions or 'heads', which have received distinctive names:

- Rectus femoris occupies the middle of the thigh, covering most of the other three quadriceps muscles. It originates on the ilium. It is named from its straight course.
- The other three lie deep to rectus femoris and originate from the body of the femur, which they cover from the trochanters to the condyles:
 - Vastus lateralis is on the *lateral side* of the femur (i.e. on the outer side of the thigh).
 - Vastus medialis is on the *medial side* of the femur (i.e. on the inner part thigh).
 - Vastus intermedius lies between vastus lateralis and vastus medialis on the *front* of the femur (i.e. on the top or front of the thigh), but deep to the rectus femoris. Typically, it cannot be seen without dissection of the rectus femoris.

All four parts of the quadriceps muscle ultimately insert into the tibial tuberosity, via the patella, where the quadriceps tendon becomes the patellar ligament, which then attaches to the tibia.



freedictionary.com/_viewer.aspx?path=MosbyMD&name=quadriceps
\$url=http%3A%2F%2Fmedical-
freedictionary.com%2Fquadriceps%2Bfemoris

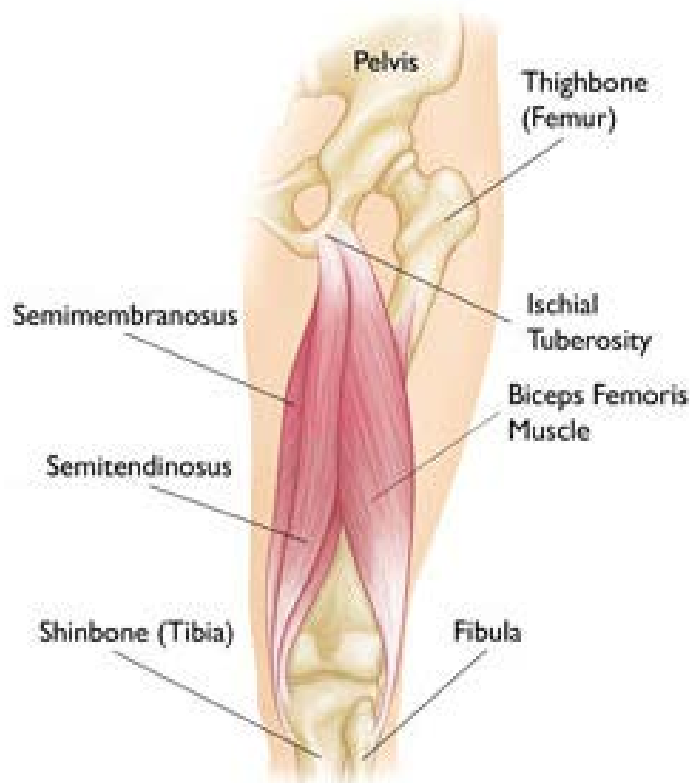FIGURE. THE QUADRICEPS (SECONDARY HIP FLEXOR).

3 . 4 . 4 Extensors

The hamstring muscles occupy the posterior compartment of the thigh. The hamstrings consist of three muscles which are, specified from medial to lateral in the midthigh, the semimembranosus, the semitendinosus, and the biceps femoris. The biceps femoris (Latin: two headed muscle of the thigh) consists of a long head with origin at the ischial tuberosity and a short head with origin from the distal posterior femoral diaphysis.

The common site of insertion is the fibular head. The other hamstring muscles along with the long head of the biceps femoris originate from closely placed sites on the posterior/inferior surface of the ischial tuberosity. The semimembranosus and the semitendinosus insert on the proximal medial tibia.

The hamstrings "primary" function is NOT knee flexion. In walking or running, for example, the primary function of the hamstring is to decelerate the lower leg in the sagittal plane. Positionally, knee flexion in walking/running occurs as a result of hip flexion and plantarflexion, again positionally.

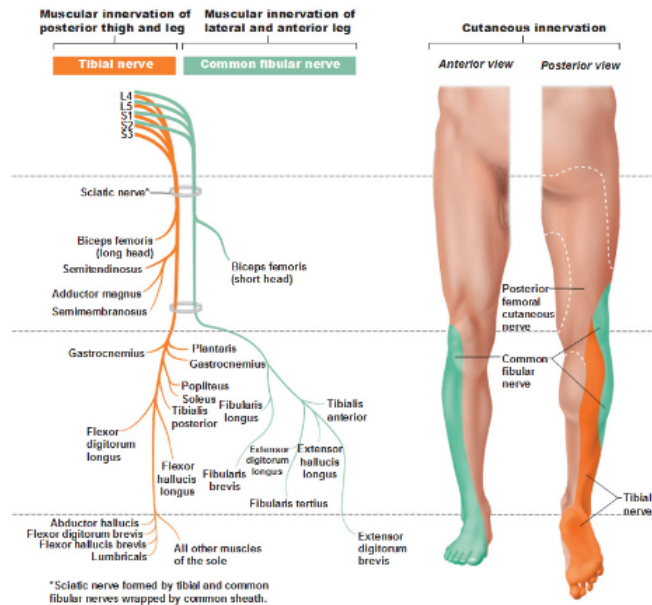


3 . 5 Nerve Supply

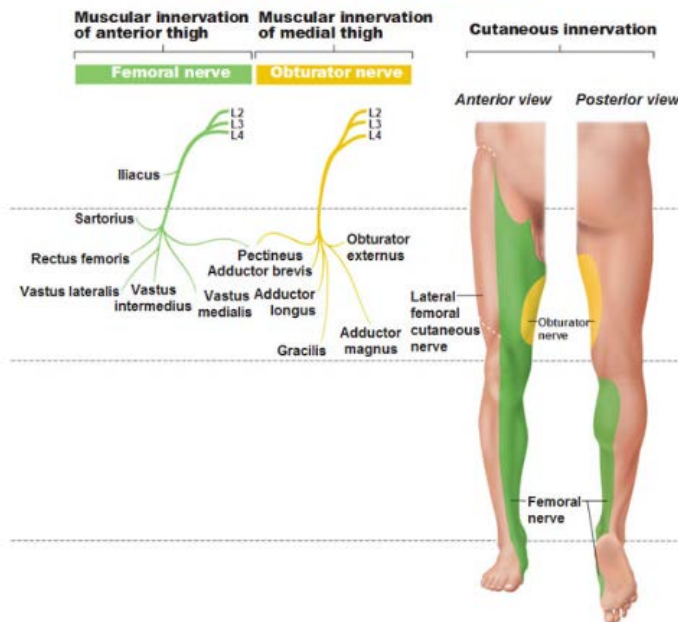
Muscles contract in response to stimuli that mainly originate in the brain. The stimuli are carried to the muscles by special fibers called nerves. These come from various parts of the brain and pass down the center of the spine in the spinal cord. The nerves of the brain and spinal cord are part of the central nervous system or CNS. Once the nerves leave the spinal cord and branch out all over the body they are known as peripheral nerves and form part of the peripheral nervous system or PNS.

The major peripheral nerves supplying the lower limb are:

- ◆ the sciatic nerve which supplies the extensors,
- ◆ the obturator nerve which supplies the adductors, and
- ◆ the femoral nerve which supplies the flexors.



The Lumbar Plexus

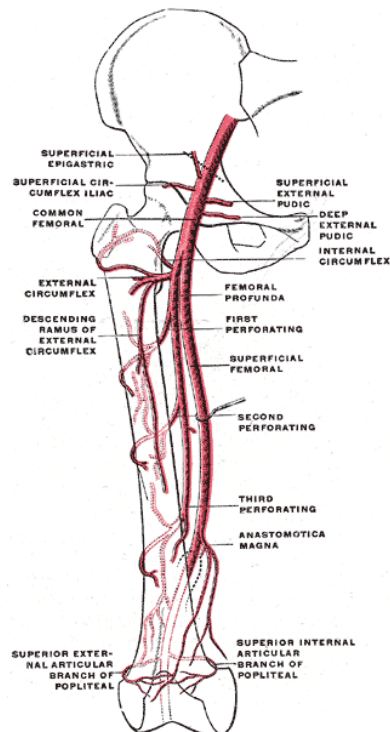
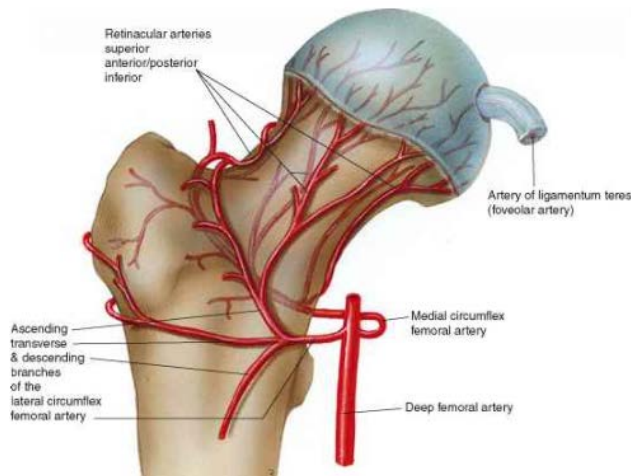


3.6 Blood Supply

The main artery supplying blood to the hip joint is the femoral artery. The femoral artery has a deep branch, the profunda femoris (profunda means deep), which sends 2 blood vessels through the joint capsule to circle the neck of the femur, called the medial and lateral circumflex arteries.

The lateral and medial circumflex arteries are the main supply of blood to the femoral head. Whereas most bones have abundant backup (collateral) blood supply, the head of the femur only has one other source of blood supply: a tiny branch of the obturator artery which travels through the ligamentum teres. This tiny artery to the head of the femur is important in preventing Avascular Necrosis of the head of the femur when the blood supply from the medial and lateral circumflex arteries is disrupted (e.g. through fracture of the neck of the femur).

<http://www.alpfmedical.info/femoral-head/vascular-supply-to-the-femoral-head.html>



<http://www.bananarepublican.info/AVN.htm>

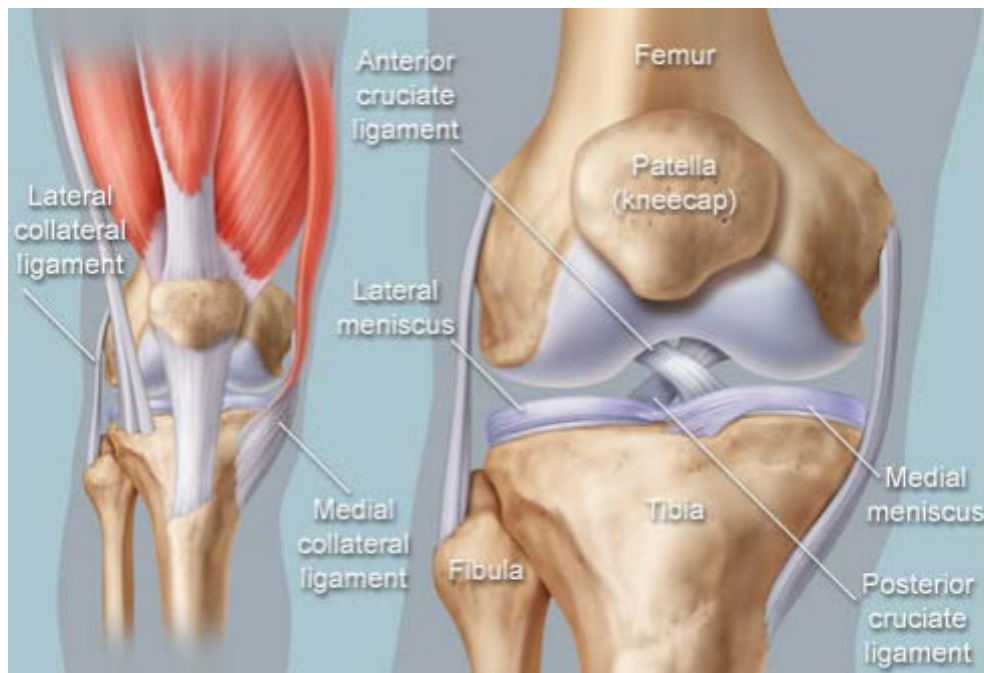
Image from Gray's Anatomy

4. THE KNEE JOINT

4.1 Structure

The knee joint is formed by the convex distal surfaces of the femur and the flat proximal surface of the tibia (*illustrated below*). The knee cap (or patella) is a small sesamoid bone between the muscular part of the quadriceps and the tendinous insertion of that muscle into the tibia. The patella glides over the end of the femur during knee motion. The part of the synovial cavity of the knee in which the patella moves is referred to, for descriptive convenience, as the patella-femoral compartment.

The two convex femoral condyles move on the flat surface of the tibia. These two regions are referred to, again for descriptive convenience, as the medial and lateral compartments. It is important to realize that the medial, lateral and patella-femoral compartments of the knee are simply regions of the same joint. The fibula does not form part of the knee joint except to act as an anchor for knee muscles and ligaments.



www.webmd.com/pain-management/knee-pain/picture-of-the-knee

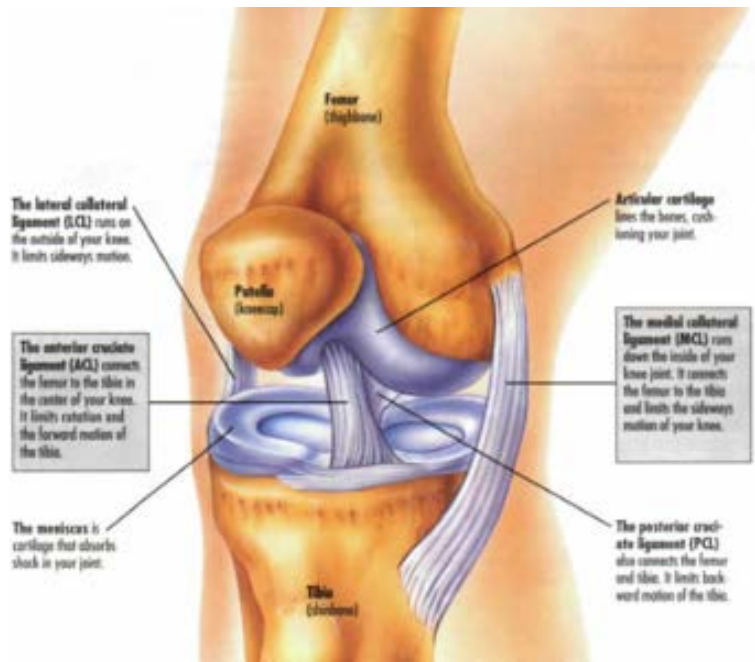
4.2 Stability

Four factors contribute to knee stability:

- ◆ Ligaments,
- ◆ Muscles,
- ◆ Menisci, and
- ◆ Shape

(Unlike the hip, the shape of the bones of the knee are such that they contribute very little to stability.)

The stability of the knee joint stems mainly from its ligaments. On either side of the joint lie the medial and lateral collateral ligaments (*illustrated below*). Within the joint are two large ligaments which cross each other in the center of the knee joint. These are the anterior and posterior cruciate ligaments.



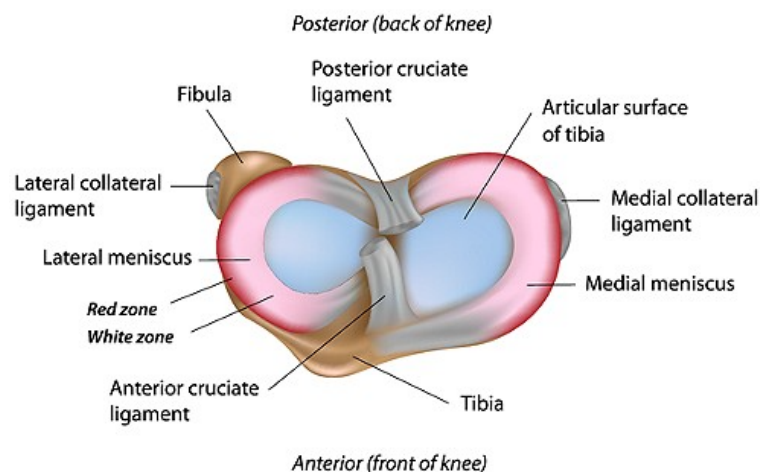
<http://www.totum.ca/other-pages/knee-injuries/>

For example if a collateral ligament is ruptured the knee can still be quite stable, especially in the straight position. On the other hand an accident, such as a lateral blow to the leg, will often damage more than one ligament, and in this case the knee is not stable.

Muscles have a minor role in controlling stability at the knee. The muscle with most relevance is probably the extensor muscle (quadriceps). If this is weak the patient may feel a loss of stability at the knee and the knee may be more prone to injury. Also during rehabilitation following knee injuries a patient may be required to do exercises to strengthen the quadriceps. This can give some compensation for the stability lost by permanent ligament or meniscus damage.

The menisci or semilunar cartilages (*illustrated below*) are crescent shaped pieces of fibrocartilage which lie on top of the tibia and are attached to it by short, tough ligaments. They aid stability by making the flat top of the proximal tibia slightly dish shaped, thus fitting the femoral condyles.

Superior (top) view of the right knee



4.3 Types of movement

Under the action of the muscles the knee joint is able to carry out the following movements:

- ◆ Flexion - the tibia moves posteriorly in the sagittal plane
- ◆ Extension - the tibia moves to a straight line (or slightly more) relative to the femur in the sagittal plane

As we have seen, rotation is possible but the ligaments are more important than muscles in producing it. There is very little adduction/abduction (motion about our axis two above) unless injury has occurred.

4.4 Muscles

When we were studying the hip we saw that it was surrounded by the bodies of the muscles that cross it. The knee is different, having mainly the tendons of its muscles around it. This means that the joint edges are easy to feel but it also means the joint is quite exposed to injury. Most of the important muscles of the knee are found around the thigh.

4.4.1 Extensors

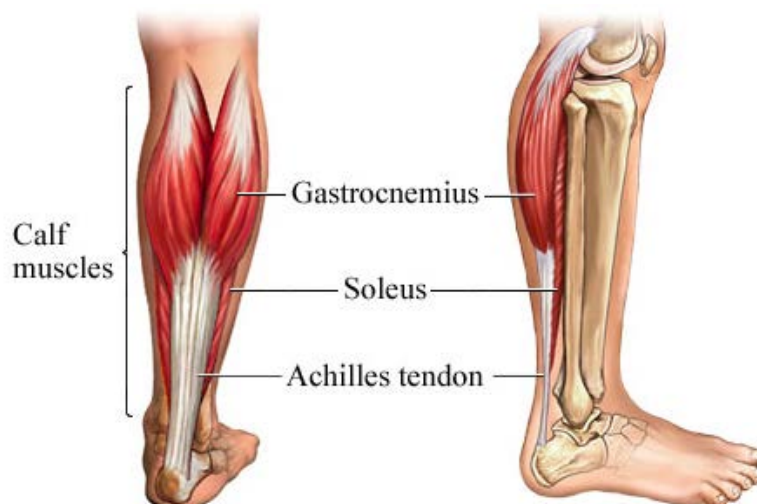The quadriceps muscle has been described in the previous section (the hip). Its insertion into the tibia is via the patella. The patella is joined to the quadriceps by a very short tendon called the **quadriceps tendon**. From the inferior border of the patella the very strong **patellar tendon** passes to the front of the tibia and is attached at a "bump" on the bone known as the **tibial tubercle**.

The patella is a **sesamoid bone**. Sesamoid bones are bones set in tendons and they occur elsewhere such as in the hand and foot. Their function is not always obvious and the numbers present vary between individuals, suggesting that they are not always essential.

In the case of the knee the patella is important and always present. Its function is to increase the efficiency of the quadriceps muscle in extending the knee.

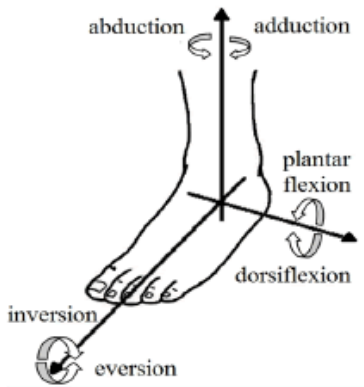
4.4.2 Flexors

The **hamstrings** were described in section on the hip. As well as being extensors of the hip they are also flexors of the knee. The **gastrocnemius** muscles (Figure 16) which act across the knee joint, are secondary flexors. At the knee they are primarily muscles of posture and balance.

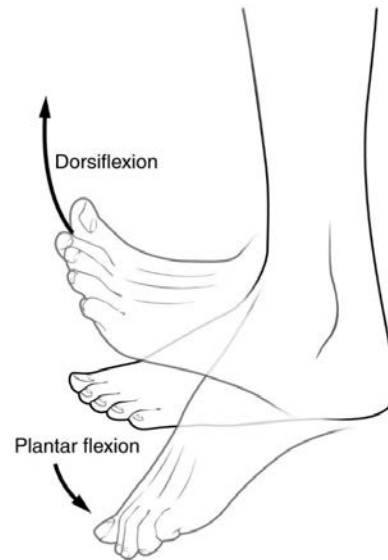

5.2 Axes of Movement

Motion of the ankle joint takes place primarily about a single axis. It is approximately horizontal and allows the foot to move in a sagittal plane. The position of the axis is along a line running between the tip of the fibula, known as the lateral malleolus and the medial projection of the tibia called the medial malleolus. These are the obvious bony prominences on the outside and inside of your ankle.



http://www.scielo.org.co/scielo.php?pid=S0012-73532012000600006&script=sci_arttext



www.properpillow.com

Figure 4. Basic ankle movements.

5.3 Types of Movement

As we have seen, the types of motion of the ankle are limited to flexion and extension in the sagittal plane. The proper names for these are dorsiflexion (toes move towards head) and plantarflexion (toes move away from head) as in Figure 18.

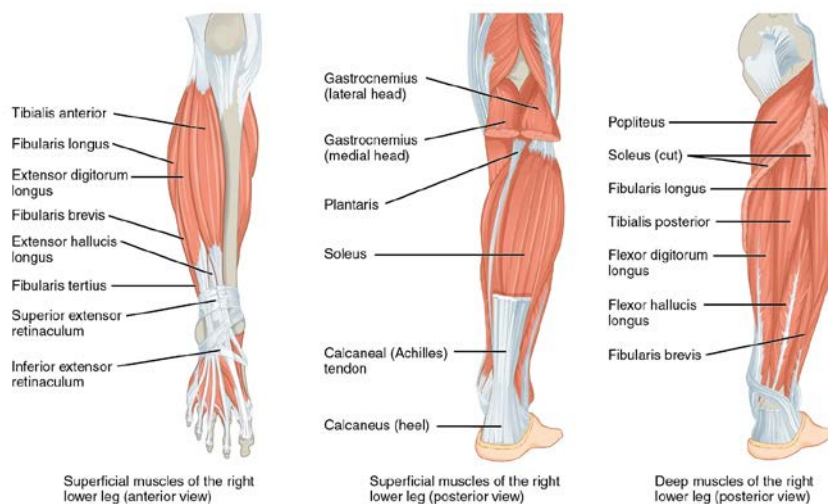
5.4 Muscles

5.4.1 Plantarflexors

The principal plantarflexors are the soleus and gastrocnemius (Figure 19) which are important power muscles and posture controllers when standing. They are attached to the os calcis (or heel bone) by the tendo calcaneus (achilles tendon, tendo achilles).

5.4.2 Dorsiflexors

Dorsiflexion of the foot is produced by the tibialis anterior, the extensor digitorum longus and the extensor hallucis longus (*illustrated below*).



<http://danceproject.ca/muscles-youre-using-wrong-calf-edition/#.VWkanM9Viko>

5.5 Blood Supply

The blood supply to the proximal part of the ankle is by numerous small vessels and is not usually a source of problems. The blood supply of the talus however is unusual in that the whole of the talus receives its blood supply from the distal end, i.e. from the foot. This means that if the talus breaks the proximal end may be without a blood supply (avascular). Luckily the talus is rarely broken in ankle injuries but if it is the consequences of avascular necrosis can be very serious as loss of the talus means destruction of the normal walking pattern.

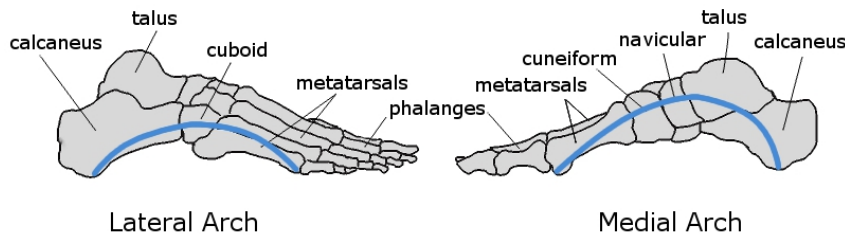
6. THE FOOT

The foot is a complicated structure of bones, synovial joints, ligaments and tendons. It is not our intention to go into the intricate detail of this structure but rather to stress the main anatomical features: its shape, the main bones and the two most important joints. The complexity of the foot is simply a reflection of the various demanding functions required of it. These include:

- ◆ load distribution (without it the end of the leg would get severely damaged!)
- ◆ provision of a stable ground contact that stays flat when the ground is sloping
- ◆ shock absorption
- ◆ transmission of propulsion forces

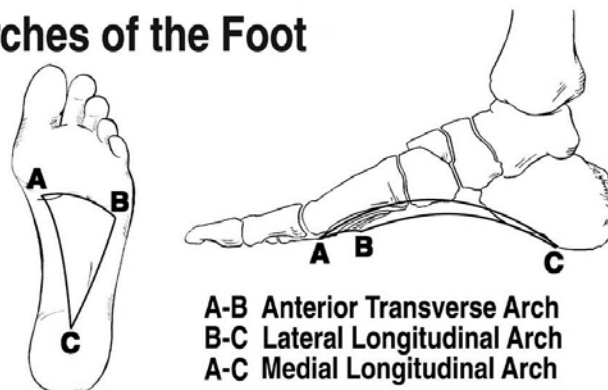
6.1 Shape and Stability

The bones in the foot are all interconnected by synovial joints and held together by strong ligaments. The tendons of the muscles of the calf further contribute to the shape and stability of the foot by pulling on the bones and holding them in a certain position or posture. The load bearing and shock absorbing functions of the foot stem partly from two arch shaped arrangements of some of the foot bones. (An arch gives high structural strength for a minimum amount of structural material). The most important and obvious arch is the longitudinal arch (Figure 21). This feature is obvious when viewing the medial side of the foot and it gives the footprint its characteristic shape.



www.alphaorthotics.com

Arches of the Foot



The foot changes shape under load. The muscles, actively, and the ligaments, passively, control the shape of the foot so that it can absorb loads. This will be important in walking and jumping, or in carrying something heavy.

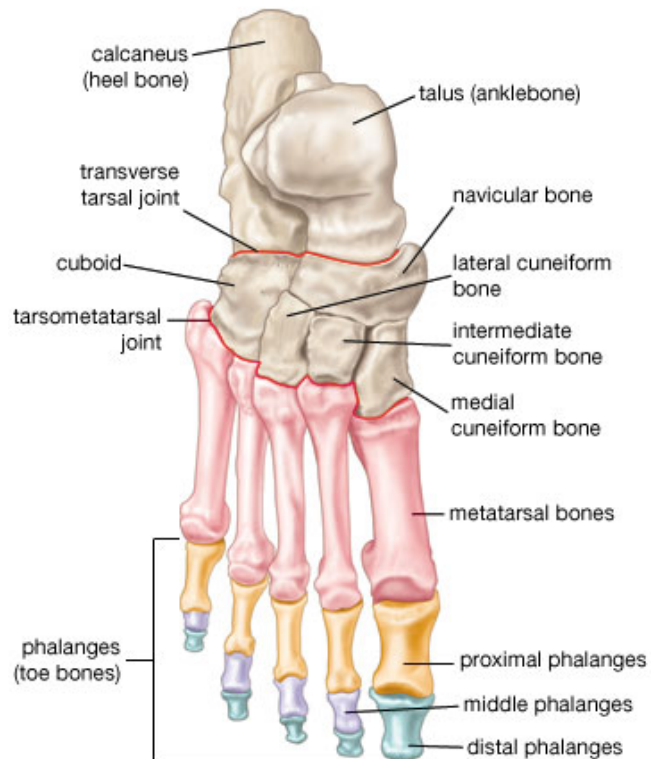
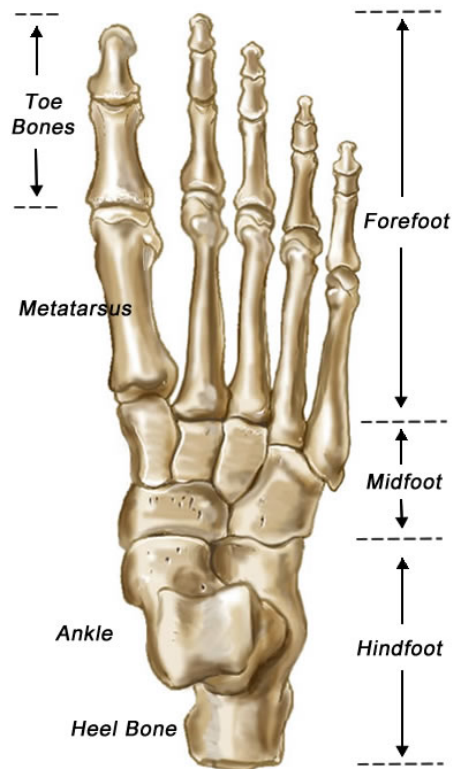
6.2 Bones of the Foot

The foot is often described, for convenience, in three regions:

The hindfoot - This consists of the talus, which forms the distal part of the ankle joint and the os calcis (also known as the calcaneus or heel bone) which articulates with the talus proximally and some of the tarsal bones in front.

The midfoot (or Tarsus) - This consists of the navicular and the cuboid bones along with the cuneiforms. This collection of bones is also known as the tarsal bones.

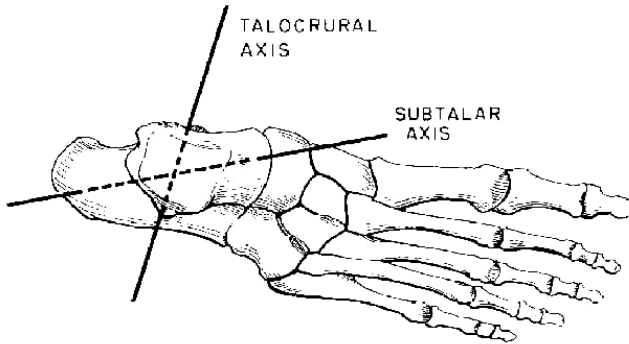
The forefoot - This consists of the five metatarsals and the toes (phalanges).



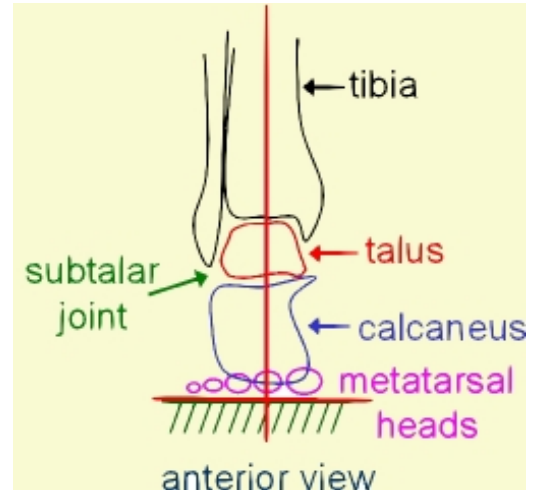
© 2007 Encyclopædia Britannica, Inc.

6.3 Subtalar Joint

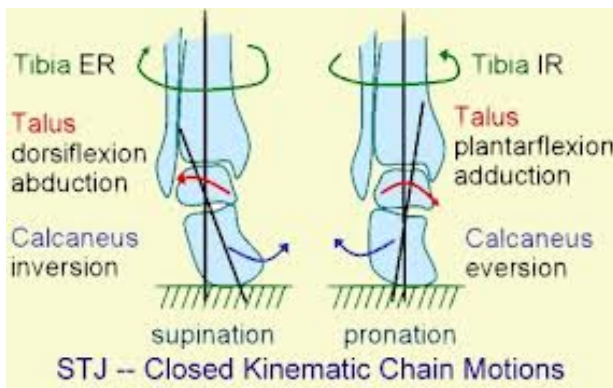
The subtalar joint is the articulation between the talus and the os calcis. This joint has an oblique axis as shown in Figure 23.



<http://moon.ouhsc.edu/dthomps/namics/labs/ankle.htm>



<http://moon.ouhsc.edu/dthomps/namics/labs/ankle.htm>



<http://moon.ouhsc.edu/dthomps/namics/labs/ankle.htm>

E 23. THE AXIS OF THE SUBTALAR JOINT SEEN FROM (A) ABOVE (B & C) REAR.

This joint allows an inward and outward rotation of the foot (about an approximately horizontal, front to back axis) defined as follows:

- ◆ Inversion - rotation of the foot so that the sole faces medially
- ◆ Eversion - rotation of the foot so that the sole faces laterally

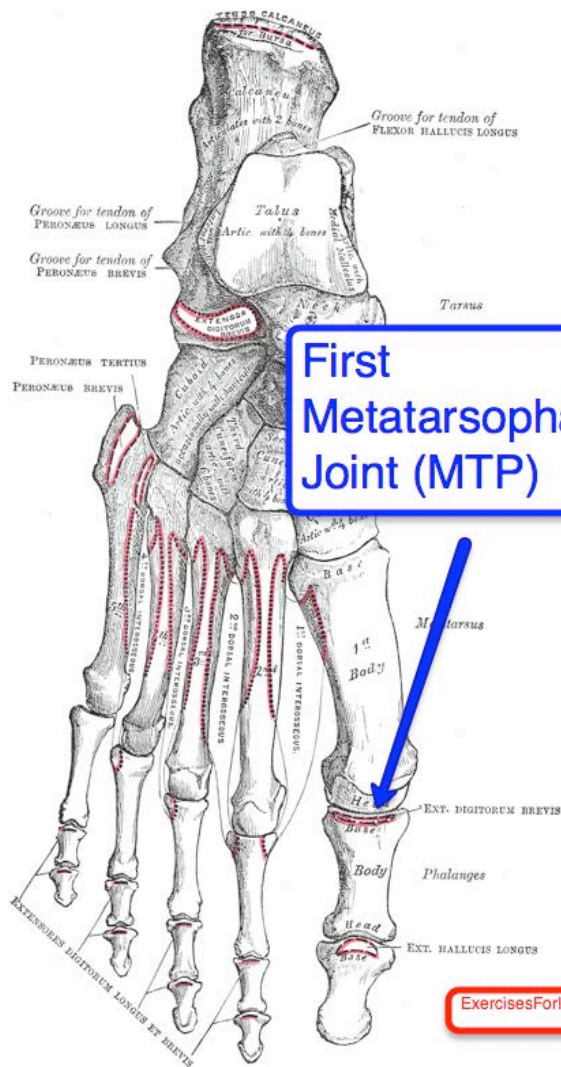
These movements are valuable when walking over rough ground or across a slope. Together with the ankle the subtalar joint helps produce smooth walking, whatever the ground is like.

6.4 First Metatarsophalangeal Joint

The first metatarsophalangeal joint (Figure 24) is an articulation on the medial side of the foot between the great toe, or hallux, and the first metatarsal. It is a synovial joint in the form of a hinge and permits dorsiflexion and plantarflexion of the toe. Although it is a small joint it is important in walking and in particular in permitting the flexor hallucis muscle to impart downward pressure on the ground during running, walking and jumping.

When the joint becomes worn every footstep becomes very painful and so the sufferer tends to hold the joint stiff. This condition is known as Hallux Rigidus although the accurate

description is osteoarthritis of the first metatarsophalangeal joint. Another common problem occurs if the big toe gets bent out of alignment causing the first metatarsal to rub on the shoes. The result is the formation of a fluid filled sac known as a bunion.



First Metatarsophalangeal Joint (MTP)

ExercisesForInjuries.com

B. THE UPPER EXTREMITY

In this section you will study the anatomy and physiology of the upper limb. This is the part of the body commonly known as the "arm". The unit starts by describing the main features of the upper limb and the method by which this is suspended from the rest of the skeleton. Then the shoulder, elbow and wrist joints are described along with their associated muscles, nerves and movements. The section concludes with a sub-section on the hand and thumb.

7. STRUCTURE & FUNCTION OF THE UPPER LIMB

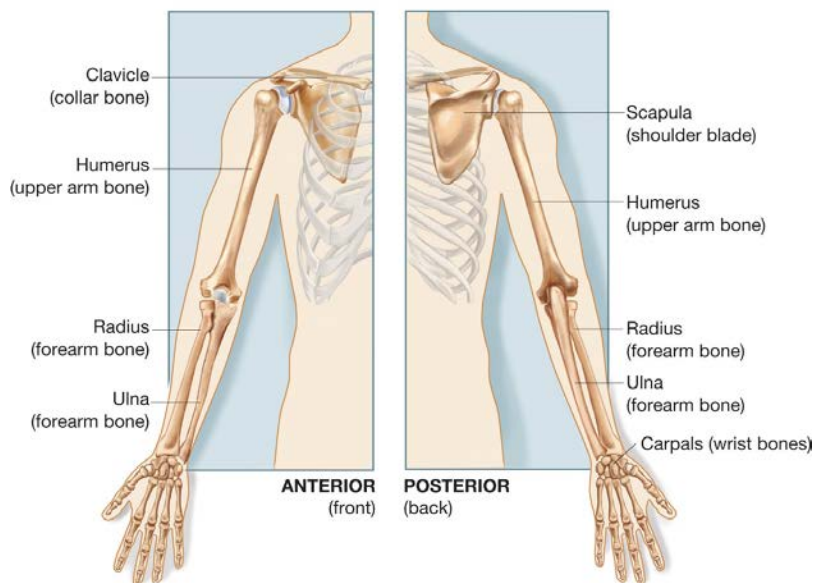
7.1 Function

The main role of the upper limb is to position the hand in space. In contrast to the lower limb, therefore, the joints of the upper limb are designed to achieve a wide range of movement rather than to provide stability.

The development of the hand as an instrument for exploring and modifying the environment is of great significance to humans. The upper limb allows us to position a hand on any part of our body, to reach out our hands to manipulate or sense objects in our environment and to communicate with each other. We can use our hands to gather information about the size, shape, texture and temperature of an object, and to manipulate objects with great skill and precision or to grip them powerfully. A very special feature of our hand is the thumb which "opposes" the other digits, making it easier to hold and manipulate objects. This, combined with a highly specialized muscle and nerve supply, makes the hand a highly sophisticated yet powerful tool.

7.2 General Layout

The upper limb (*illustrated below*) consists of three segments of bones and joints: the **arm**, the **forearm** and the **hand**. The shoulder, elbow and wrist joints define the ends of these segments and allow them to move relative to each other. The side of the upper limb seen when the palm of the hand is uppermost is the flexor (anterior) surface. The opposite surface (the back of the hand), is the extensor (posterior) surface.



The upper limb is suspended from the axial skeleton (the spine, skull, rib cage and breastbone) by groups of large muscles. The only joint holding the upper limb to the rest of the skeleton is the joint between the collar bone (clavicle) and the breast bone (sternum). The shoulder girdle from which the rest of the upper limb hangs includes the clavicle (collar bone) and the scapula (shoulder blade).

The shoulder joint itself includes the articulation between the scapula and the thorax (chest) and between the scapula and humerus. The elbow joint is formed by the distal humerus and the two forearm bones; the radius and the ulna. The wrist joint is formed by the end of the radius and the seven small wrist bones. The end of the ulna only contributes to the wrist joint via a cartilage disc.

In the hand many small joints controlled by many individual tendons make both precise movements and a powerful grip possible. However, the hand would be much less useful without the thumb and its ability to touch the tips of each of the other digits.

7.3 Shape

You can see in Figure 25 that the humerus and forearm bones are not in a straight line. A slight angle (in the coronal plane) occurs at the elbow. This is called the carrying angle and enables the forearm to swing past the pelvis. In women the average angle is a little greater than in men, to allow the arm to swing clear of their wider pelvis.

8. THE SHOULDER GIRDLE

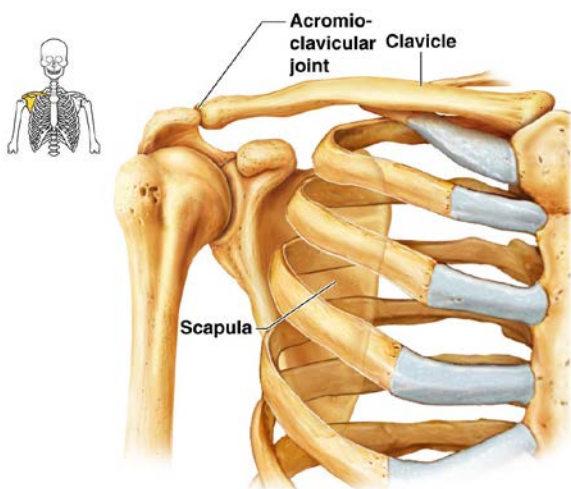
8.1 Function

Unlike the pelvic girdle, the shoulder girdle is a light and mobile structure and has the ability to move on the chest wall under the control of several large muscles. Its functions are:

- ◆ to suspend the arm from the axial skeleton
- ◆ to participate in moving the arm and so position the hand in space

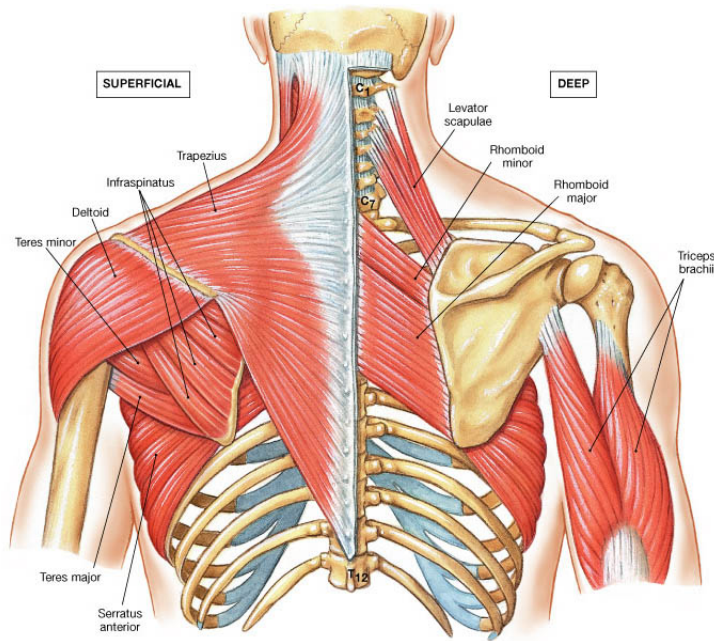
8.2 Structure

Shoulder girdle (*illustrated below*) is made up of the clavicle and scapula. These two bones are joined together where the lateral end of the clavicle meets the acromion process of the scapula. You can feel this bony process and the indentation of the joint at the point of your own shoulder. The shoulder girdle is suspended from the chest wall by a joint between the sternum and the medial end of the clavicle. This joint is the only bony attachment of the shoulder girdle to the rest of the skeleton.



(a) Articulated right shoulder (pectoral) girdle showing the relationship to bones of the thorax and sternum

Copyright © 2009 Pearson Education, Inc., publishing as Pearson Benjamin Cummings.

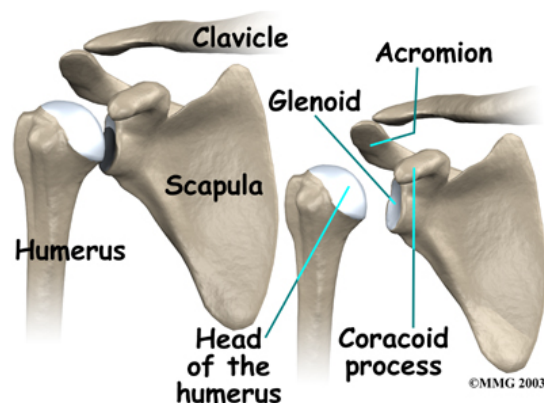
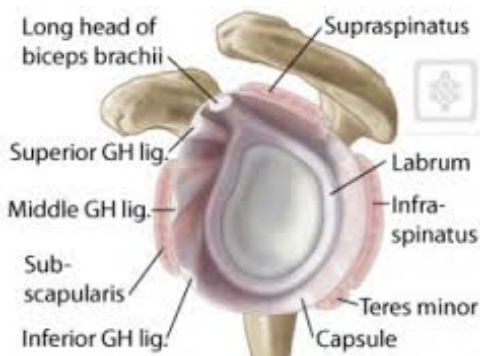

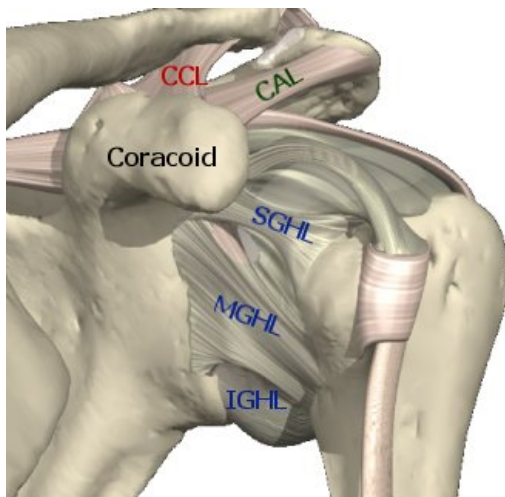
The remainder of the stability of the shoulder girdle is due to large muscles from the chest wall and neck which suspend the clavicle and scapula (*illustrated above*). In particular the trapezius muscle suspends the clavicle and scapula and the serratus anterior secures the scapula to the chest wall.

9. THE SHOULDER JOINT

9.1 General Structure

The shoulder joint is a synovial joint of the ball and socket type. Unlike the hip joint though, the ball and socket of the shoulder joint are much less fully developed and more resemble an egg sitting on a spoon. The articular surface of the scapula is called the glenoid fossa (Figure 28). This is shallow but has a thick cartilaginous rim called the labrum which helps to further enclose the head of the humerus. The joint is surrounded by a capsule and most importantly by the rotator cuff (*illustrated below*).





<http://morphopedics.wikidot.com/reverse-total-shoulder-replacement>

9.2 Stability

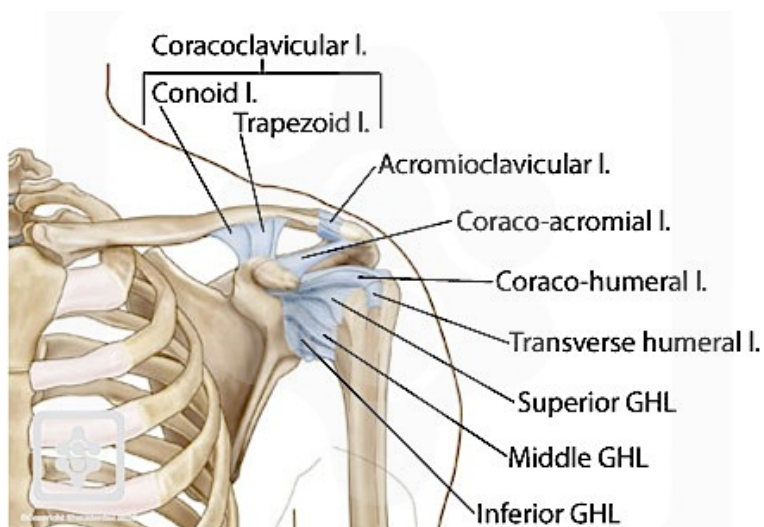
The egg on a spoon analogy suggests that the shoulder joint is not very stable as far as its bony shape goes and indeed in the shoulder joint, stability has been sacrificed for the sake of increased mobility. Dislocations of the shoulder are therefore not infrequent.

However, three structures do contribute to stability of the joint:

- ◆ the glenoid labrum
- ◆ the coraco-acromial ligament
- ◆ the rotator cuff

The glenoid labrum is a cartilaginous rim around the glenoid fossa of the scapula which helps to contain the head of the humerus.

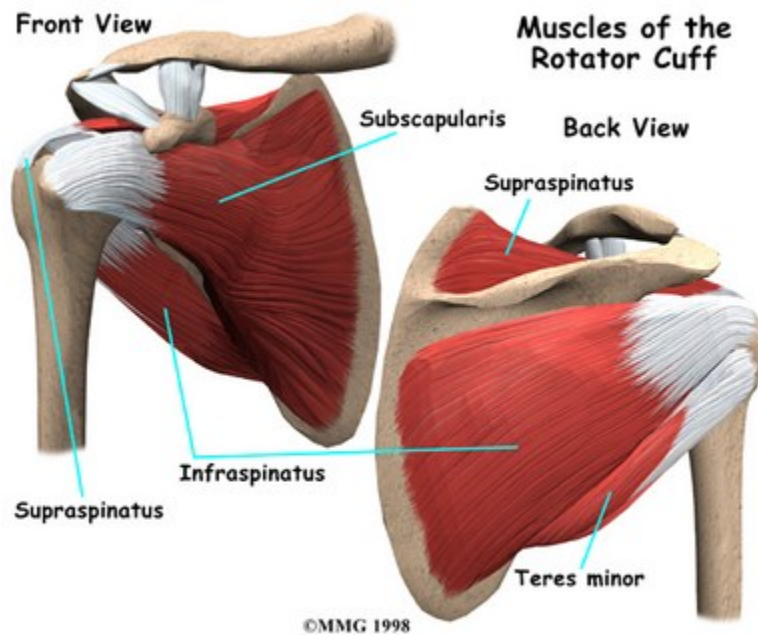
The coraco-acromial ligament is a strong arc of tissue between the acromion process and the coracoid process of the scapula



<http://www.shoulderdoonline.co.uk/article.asp?article=1179>

This forms a "roof" to the shoulder and helps to prevent the head of the humerus slipping out of the top of the glenoid fossa. The other ligaments of the capsule are not particularly strong and consequently the shoulder is more likely to dislocate in other directions.

The rotator cuff: this group of four muscles arises from the broad flat areas of the scapula and comes together to insert beyond the head of the humerus. They thus form a cuff of tissue like the fingers of a hand cupping a ball. The rotator cuff is an important adjunct to stability but also contributes to moving the shoulder joint. The muscles of the rotator cuff are subscapularis, infraspinatus, supraspinatus and teres minor (illustrated below).



9.3 Axes of Movement

The shoulder girdle can be moved in several directions on the chest wall. This ability together with the large range of movement possible at the shoulder joint (correctly called the **glenohumeral joint**) allows the arm to be moved into many positions.

The combination of scapulothoracic and glenohumeral movement, make the shoulder joint the most mobile in the body. The different axes of movements allow movements in the:

- ◆ coronal plane
- ◆ sagittal plane

In addition, rotation along the long axis of the humerus is possible.

9.4 Types of Movement

- ◆ **Flexion** - swinging the arm forwards in the sagittal plane
- ◆ **Extension** - swinging the arm backwards in the sagittal plane.
- ◆ **Abduction** - swinging the arm laterally in the coronal plane.
- ◆ **Adduction** - swinging the arm medially in the coronal plane.
- ◆ **Internal rotation** - rotation of the arm along its long axis so that the hand turns towards the body.
- ◆ **External rotation** - rotation of the arm along its long axis so that the hand turns away from the body.
- ◆ **Circumduction** - movements of the whole arm in a circle (a combination of flexion, abduction, extension and adduction).

9.5 Muscles

When thinking of muscles controlling the shoulder joint, we must think of those which move the shoulder girdle and those which move the glenohumeral joint. In addition, the rotator cuff muscles also stabilize the glenohumeral joint while other muscles move it.

Muscle actions:

- ◆ **trapezius** - rotates the scapula upwards and shrugs the shoulders.
- ◆ **serratus anterior** - stabilises the scapula to the chest wall and pulls it forwards.
- ◆ **pectoralis major** - flexes and adducts the glenohumeral joint.
- ◆ **latissimus dorsi** - extends and adducts the glenohumeral joint.
- ◆ **deltoid** - abducts the glenohumeral joint.
- ◆ **rotator cuff** - these four muscles stabilise the glenohumeral joint during movement and when acting individually, can abduct, extend and rotate the joint.

9.6 Examples of Muscle Activity

Muscle action around the shoulder can easily be observed on yourself. The action of the trapezius can be felt while shrugging the shoulders.

During pull-ups the arm is being extended and adducted on the body. The action of pectoralis major and the latissimus dorsi is easily observed.

The main abductor of the glenohumeral joint is deltoid. This action is used when putting the arm into a jacket sleeve.

9.7 Nerve Supply

The nerve supply to the upper limb comes from the neck region. The nerves are distributed via the brachial plexus in the neck and passed to their appropriate muscle groups. The brachial plexus is a region where several nerves make cross connections with each other. The major peripheral nerves of the upper limb are:

- ◆ the median nerve which supplies the flexor muscles in the forearm and controls the thumb.
- ◆ the ulnar nerve which supplies some of the flexor muscles in the forearm and controls the other small muscles in the hand.
- ◆ the radial nerve which controls the extensors of the hand and wrist.
- ◆ the musculocutaneous nerve which supplies the flexor muscles of the arm.

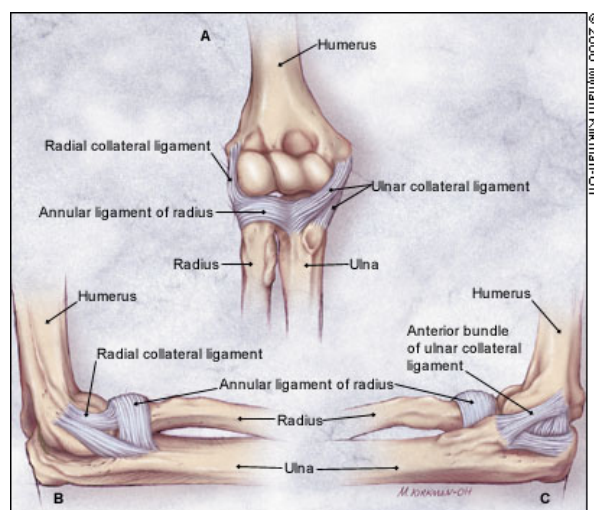
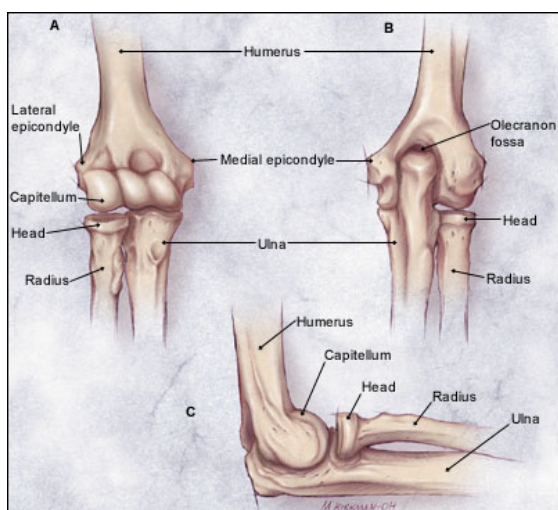
10. THE ELBOW JOINT

10.1 General Structure

The elbow joint is formed by the distal surface of the humerus and the proximal articular surfaces of the forearm bones, the radius and ulna (*illustrated below*).

There are three components to the joint:

1. The joint between the distal humerus and the proximal ulna is a uniaxial hinge **joint**. The bobbin-shaped **trochlea** of the humerus articulates with the trochlear notch in the **olecranon process** (*illustrated below*) of the proximal ulna.
2. The joint between the distal humerus and the proximal radius is an example of a **uniaxial pivot joint**.
3. The rotation of the radius on the distal humerus is facilitated by a joint between the proximal radius and the ulna to which it is bound by a ligamentous sling.



10.2 Stability

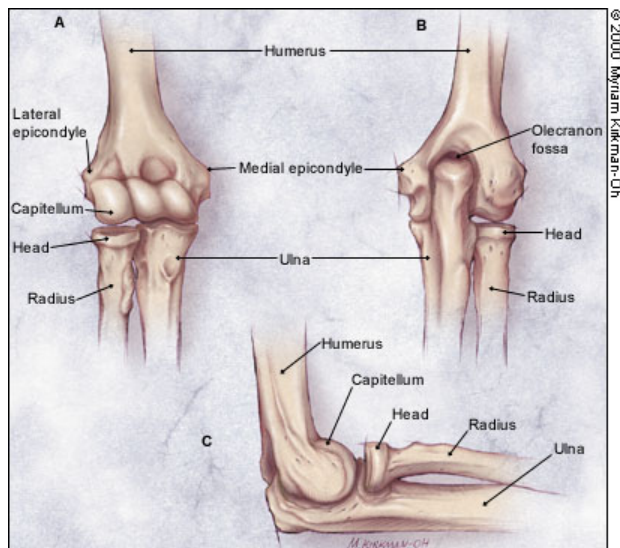
Three factors contribute to elbow stability:

- ◆ ligaments,
- ◆ muscles, and
- ◆ shape.

As mentioned before, the radius is bound to the ulna by a "sling" of ligaments. This is called the annular ligament. It forms a cuff in which the radius can rotate to function as a uniaxial pivot joint. Holding the forearm to the arm, are two collateral ligaments, one on the radial and one on the ulnar side. The ulnar or medial collateral ligament is, like its namesake in the knee, the more well developed. The capsule of the elbow joint is a looser, thinner structure than the ligaments and does not contribute much to stability.

The long muscles crossing the elbow joint contribute to its stability. On the anterior side of the elbow there are flexor muscles which flex the joint and on the posterior side of the elbow there are extensor muscles which extend the joint.

In profile, the olecranon process resembles the end of a spanner (Figure 32). It is well designed to resist forces (particularly in an anteroposterior or posteroanterior direction) as it grasps the trochlea like a nut. However, only a moderate amount of stability is present to resist forces from side to side in a medial or lateral direction.



<http://www.aafp.org/afp/2000/0201/p691.html>

10.3 Axes of Movement

The elbow joint allows movement through two axes:

- ◆ a horizontal axis in the coronal plane, and
- ◆ a vertical axis along the length of the forearm

Movement around the first axis allows flexion and extension in the sagittal plane. Movement about the second axis down the length of the forearm, allows the radius to rotate. As it does so its distal end migrates around the distal end of the ulna. This action allows the hand to be turned over. The position when the palm is facing upwards is called "supination" and when the palm is facing downwards is called "pronation". In this position the radius has rotated around the ulna along the long axis of the forearm and is now lying on top of the ulna instead of by its side.

10.4 Type of Movement

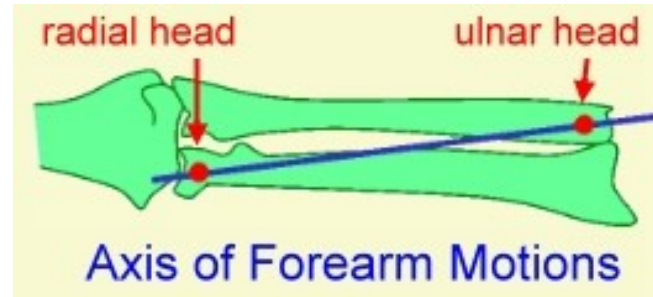
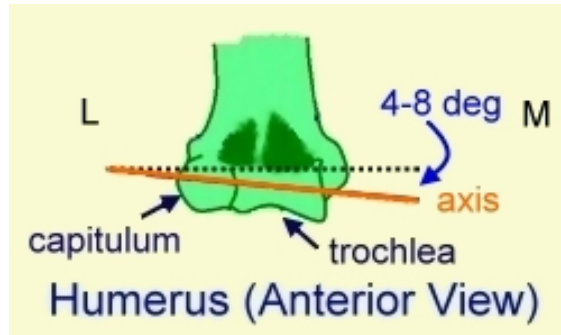
Under the action of muscle, the elbow joint is able to carry out the following movements:

Flexion - the forearm is bent upwards.

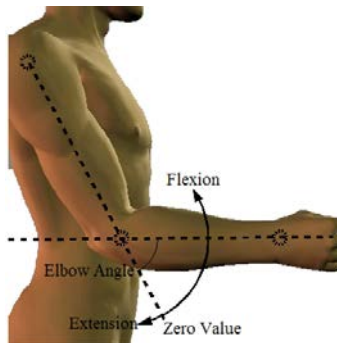
Extension - the forearm moves backwards to be in line with the humerus.

Supination - this is the position the forearm adopts when the radius and ulna lie parallel to each other and the palm is turned face up.

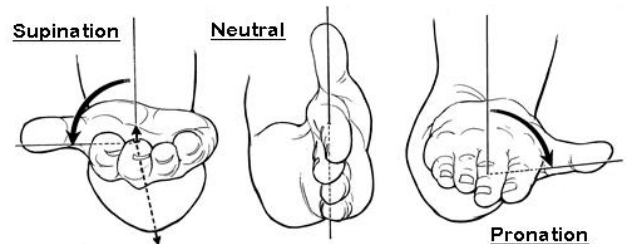
Pronation - this is the position achieved when the radius has rotated round the ulna. The palm is turned face down.



www.pt.ntu.edu.tw



<http://www.dh.aist.go.jp/bodyDB/a/Hatze-97-01e.html>



www.studyblue.com

10.5 Muscles

The muscles which control the elbow joint originate on either the scapula or the humerus.

Flexors - the most prominent group of muscles in the arm are the flexors. The **biceps brachii** muscle is easily seen at the front of the upper arm when you "flex your muscles". It comes from two origins on the scapula and inserts into the proximal radius. Its action is therefore to flex the forearm but because it is sited on the medial side of the radius, it also acts as a prime mover of supination for external rotation of the forearm. The brachialis muscle rises on the shaft of the humerus and inserts into the ulna and is the most powerful flexor of the elbow.

Extensors - the **triceps brachii** is the extensor of the elbow. It has one origin from the scapula and one from the proximal humerus. It occupies the entire back of the arm and inserts into the olecranon process of the ulna.

Pronators - the **pronator teres** is an example. This muscle arising from the medial side of the distal humerus can pull the radius over the ulna thus rotating it along its long axis into pronation. This action is the reverse of the supinating action of biceps.

Supinators - as mentioned before, biceps brachii acts as a supinator of the forearm. A second muscle, called **supinator**, wraps around the back of the radius to achieve this action as well.

10.6 Examples of Muscle Activity

We tend to think of the biceps as being the muscle most prominent during flexion of the elbow. This is true but it also can be seen to act during supination of the forearm. It is very obvious when using a screwdriver to secure a screw tightly. It must be turned clockwise. This action can be carried out easily using a screwdriver in the right hand but not in the left. Supination of the forearm is necessary and the biceps can be seen to work strongly during this action. If you turn the same screw with the left hand, it requires pronation and this action is not so strong.

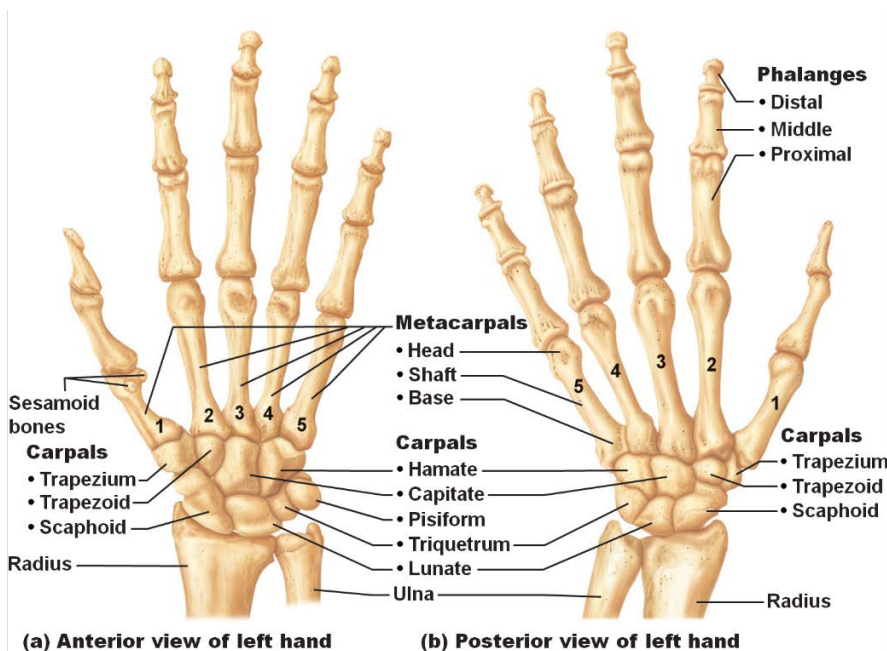
11. THE WRIST JOINT

11.1 General Structure

The wrist joint is a complex structure made up of many bones but for the sake of simplicity it can be thought of as three joints next to each other. These are the joints between:

- ◆ The distal ends of the radius and ulna
- ◆ The distal radius and the first row of wrist bones (carpals)
- ◆ The two rows of wrist bone

The bones are held together by ligaments which run between them and across them. There are collateral ligaments on either side arising from the radius and the ulna. No muscle bodies cross the wrist joint. If they did so the wrist and hand would be large unwieldy structures unable to carry out fine work in small spaces. Instead the majority of muscles controlling the wrist and hand are in the forearm and only muscle tendons cross the wrist into the hand. Some muscles in the hand itself control free movement of the digits.

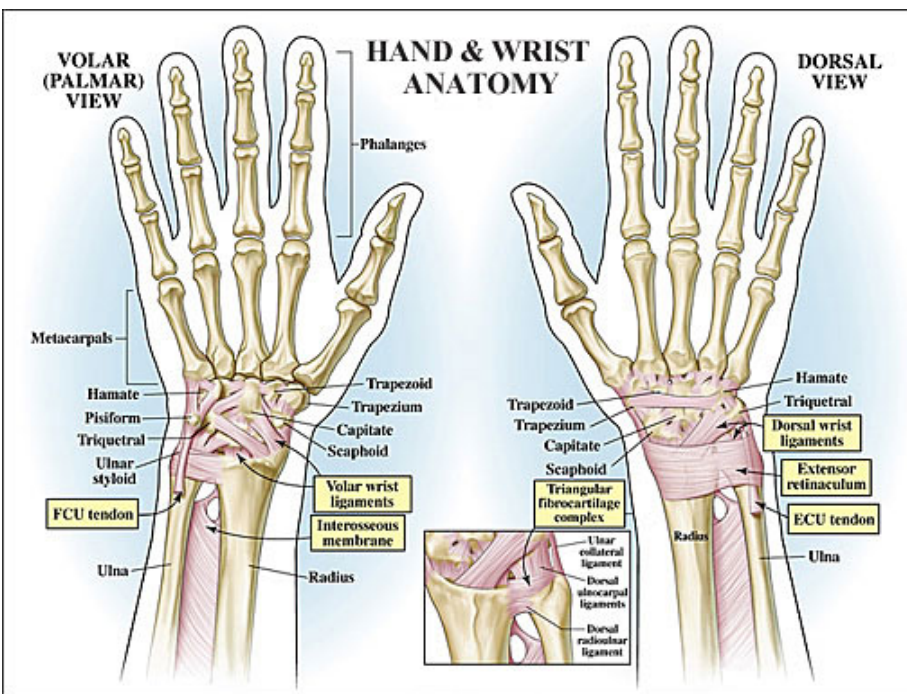


11.2 Stability

Dislocations and sprains of the wrist joints are common which is not surprising after looking at the structure of the joint. Stability of the wrist depends on:

- ◆ shape, and
- ◆ ligaments

The shape of the joint between the radius and the first row of carpal bones does not provide a lot of stability. The stability of the wrist is therefore dependent on the strong ligaments on the anterior aspect of the wrist (*illustrated below*). If they are torn or stretched they fail to work properly. When intact they hold the bony components of the wrist and hand together like a three-link chain. If they are damaged, the chain collapses. This pattern is called an intercalated segment and its collapse is referred to as intercalated segment instability. In the normal wrist, the ligaments prevent the three-link chain collapsing under the pull of the tendons passing on either side of it



11.3 Axes of Movement

The wrist has two axes of movement:

- ◆ **Sagittal** - allowing movements in a sideways direction.
- ◆ **Coronal** - allowing movements in a backwards and forwards direction.

Note that the axis of movement is at right angles to the plane of movement. Therefore the coronal axis allows movement in a sagittal plane and vice versa. These movements occur at the two joints we have discussed previously; the **radiocarpal** and the **midcarpal** joints.

11.4 Type of movement

- ◆ **Flexion** - movement of the hand anteriorly in the sagittal plane. This movement at the wrist is sometimes called palmar flexion.
- ◆ **Extension** - movement of the hand posteriorly in the sagittal plane. This movement is sometimes called dorsiflexion.
- ◆ **Abduction** - movement of the hand away from the mid-line of the body in the coronal plane. This movement is sometimes called radial deviation because it is taking place towards the radial side of the wrist.
- ◆ **Adduction** - movement towards the mid-line of the body in the coronal plane. This movement is sometimes called ulnar deviation because it is taking place towards the ulnar side of the wrist.

11.5 Muscles

We will consider the muscles in groups according to the movement which they carry out. As mentioned before the muscles which control wrist movement arise from either the forearm or distal humerus. Only their **tendons** cross the wrist joint to insert into the carpal bones to produce movement of the joint. The muscles and tendons on opposite surfaces of the forearm and wrist balance each other like guy ropes supporting a tent.

Palmar flexors - The principal muscles which produce palmar flexion of the wrist are flexor carpi radialis and flexor carpi ulnaris.

Dorsiflexors - the muscles producing dorsiflexion balance the palmar flexing muscles. They are called extensor carpi radialis and extensor carpi ulnaris.

11.6 Examples of Muscle Activity

You can see therefore that if the two flexor muscles pull together they will produce palmar flexion of the wrist, for instance this happens if you are sitting and you pull a table towards your chair.

If the two muscles on the ulnar side pull together, then they will produce ulnar deviation of the wrist (move the hand sideways in the direction away from the thumb) without any palmar flexion or dorsiflexion taking place. This movement is useful when using a keyboard.

When the two dorsiflexors contract together they produce dorsiflexion of the wrist which is neither deviated towards the radius or the ulnar sides. This is necessary to enable the fingers to produce a powerful grip.

11 . 7 Nerve Supply

There are three nerves which control the movement of the wrist and hand:

- ◆ Median nerve
- ◆ Ulnar nerve
- ◆ Radial nerve

The radial nerve controls the extensor muscles. The medial and ulnar nerves control the flexor muscles.

12. THE HAND

Our study of the upper limb has now brought us to its termination and the reason for its great mobility ... the hand.

Three characteristics make the hand very important to humans:

- ◆ Motor control - the musculature and nervous control to enable the execution of fine precision movements as well as strong grasping actions.
- ◆ Sensory ability - the highly developed sensory ability of the thumb, index and middle fingers have earned them the title of "the eyes of the hand".
- ◆ The thumb - without the ability of the thumb to touch the tips of the other digits, we would be less able to benefit from the previous two abilities of the hand.

12 . 1 Shape and Stability

The hand is made up of five metacarpal bones based on the carpal bones. The individual bones of the fingers and thumb are called phalanges. These bones are held together by ligaments. Stability of the joint between the metacarpal bones and the carpal bones is due to their shape and

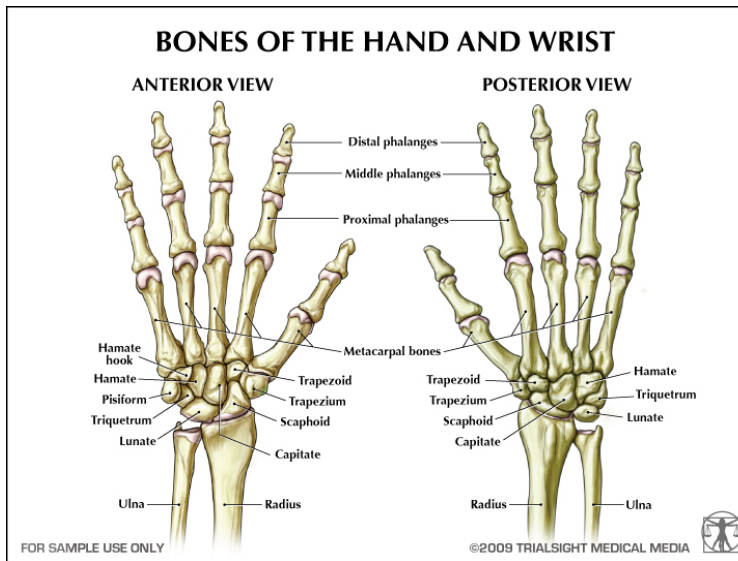Unit 2 - Skeletal Anatomy and Physiology 27

ligamentous supports. Ligaments stretching between the metacarpal heads secure the metacarpals together at the knuckle area. In the fingers the phalanges are supported by collateral ligaments at each joint. These are arranged so as to allow hinge movements only. Consequently there is some weakness in an antero-posterior direction. Dislocation of the joints between the phalanges is possible.

The hand has the ability to conform to a variety of shapes. It can become broad and flat or long and narrow. It can make a fist or cup itself around a ball. The thumb can be used with the tip of any finger to pick up objects of different sizes.

12.2 Bones and Joints

The bones and joints which make up the hand and fingers are shown in Figure 36.



<http://www.oustormcrowd.com/knowing-the-details-of-human-anatomy-hand/human-hand-bones-anatomy/>

12.3 Tendons

The tendons which control the movements of the fingers arise from muscles found in the forearm. There are also **short muscles** in the hand sited in the **thenar** and **hypothenar eminences**. These are the bulky mounds of muscle situated in the palm at the base of the thumb and along the fifth metacarpal. Short muscles also found between the metacarpal bones are called the **intrinsic muscles** of the hand and they control fine movement of the digits. The muscles arising in the forearm are called the **extrinsic muscles** of the hand.

Flexor muscles - the tendons of the long flexor muscles enter the hand on its anterior surface by running together across the wrist through the "**carpal tunnel**". Two tendons run to each finger but one flexor tendon goes to the thumb.

Extensor muscles - on the back of the hand the tendons of the extensor muscles reach the hand under a strap of tissue binding them to the back of the wrist. There is an extensor tendon to each of the fingers and two to the thumb.

12.4 Thumb

If you had to think of a quotation for something the thumb might say it would have to be "Without me you can do nothing". This vital digit gives the hand its great powers of fine control and its ability to pick up small objects or to grasp large things strongly.

Movement - the ability of the thumb to touch the tips of the other digits is due to the saddle shape of the joint between the base of the first metacarpal and the trapezium (one of the carpal bones). This joint allows movement in two directions. The metacarpal can be extended away from the palm and also brought across the palm. It can also be adducted towards the index finger and abducted to stand straight up in the air. The fine control of the thumb is due to the intrinsic muscles in the thenar eminence at its base. These are innervated by the median nerve.

Sensation - the radial half of the hand is supplied by the median nerve. The sensory supply is very well developed and consequently the thumb, index and middle fingers can accurately determine the size, texture, temperature and shape of objects.

C. THE SPINE

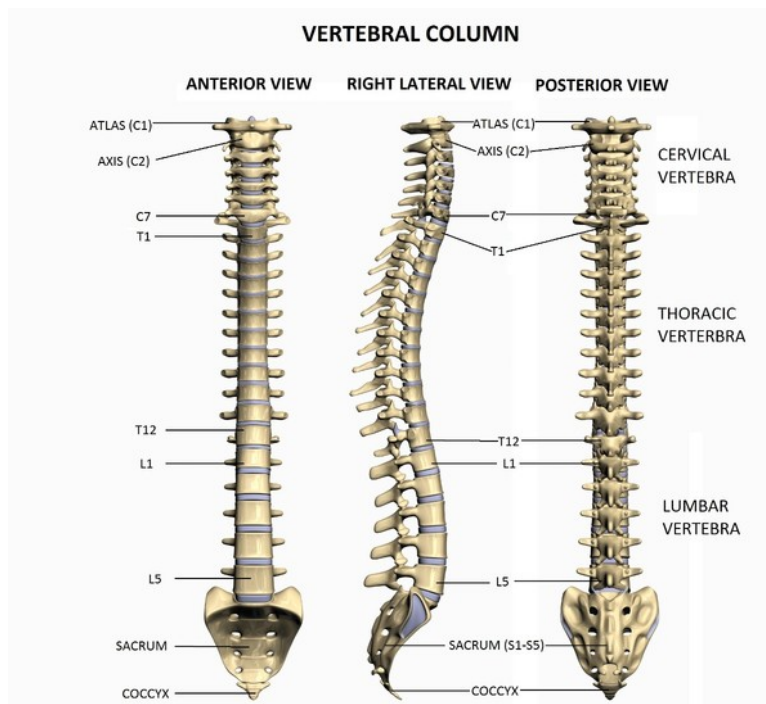
The previous sections of this unit describe the parts of the skeletal system which make up the appendicular skeleton - the limb girdles and the limbs. In the rest of this unit you will study the axial skeleton - the vertebral column, the skull, the sternum and the ribs. The terminology used must be made clear at the beginning to avoid confusion between the terms "vertebral column", "spine" and "spinal cord". The vertebral column refers to the stack of bones'- the vertebrae. The spinal cord refers to the bundle of nerves which passes through the center of the vertebral column. The spine is used as a general term to describe the vertebral column, spinal cord and associated structures.

13. STRUCTURE AND FUNCTION OF THE SPINE

13.1 General Structure and Function

The spine is made up of a column of segments which has the following functions:

- ◆ it supports the weight of the head and trunk
- ◆ it acts as a shock absorber to smooth out the jarring caused by daily activity such as walking, running and jumping
- ◆ it acts as an anchor for the limb girdles and ribs
- ◆ it provides a conduit for the spinal cord and the nerves which branch from it



Each segment is called a vertebra. Most vertebrae can move relative to the ones next to them and some can move more than others. By moving our body we can readily appreciate that the vertebrae in the neck region have the greatest freedom of movement. Muscles attached to the vertebrae cause this movement to take place.

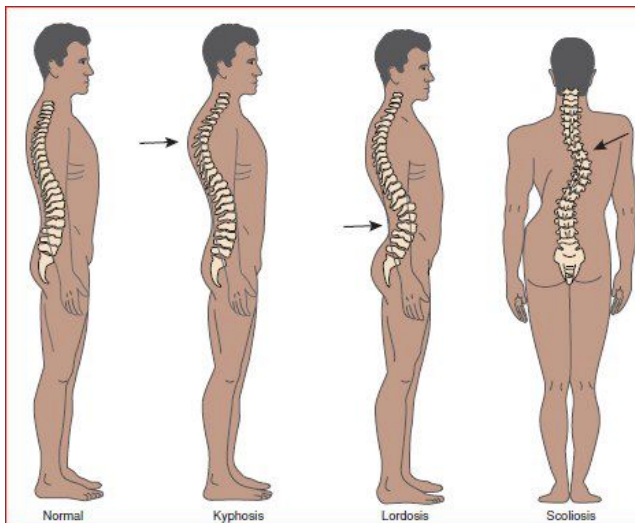
The spinal cord runs down the inside of the vertebral column, through a hole in each vertebra, and the peripheral nerves branch from the cord through holes between the vertebrae to the different regions of the body.

13.2 Shape of the Spine

The spine is not a straight column. Rather it is a series of alternating curves. This is best seen on the diagram below. We can identify four regions of the vertebral column:

- ◆ cervical
- ◆ dorsal (thoracic)
- ◆ lumbar
- ◆ sacrum and coccyx

Alterations in spinal curvature in any one region will have important effects on the mechanics of the whole spine. An inward curvature of the spine is known lordosis. An outward curvature of the spine is known as a **kyphosis***



<http://healthtipsinsurance.com/stories/24210/Structure-Of-Spinal-Cord.html>

13.3 Movement

The different regions of the spine have differing ranges of movement. The range of movement is affected by the shape of the vertebrae and the orientation of the joints between individual vertebrae.

The spine as a whole is very mobile, particularly in flexion and rotation. This permits us to see all around us, to bend over forwards and to bend from side to side. In order to make some sense of this mobility it is important to describe movements in conventional anatomical planes. The list below illustrates the regions of the spine where most of the movements described occur.

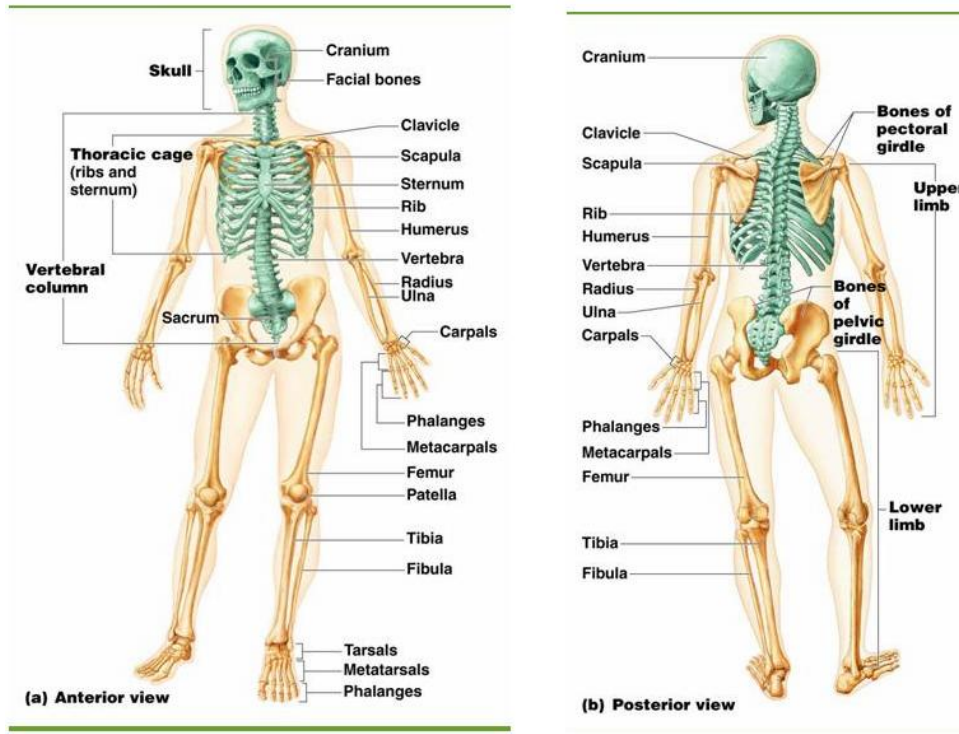
- ◆ **Flexion - Anterior flexion** - cervical and lumbar regions, **Lateral flexion** - cervical region
- ◆ Extension - cervical, thoracic (dorsal) and lumbar regions
- ◆ **Rotation** - predominantly in upper cervical region - some in the lumbar region

13.4 The Skull, the Ribs and the Limb Girdles

The vertebral column, the ribs, sternum and the skull are often known as the axial **skeleton**. The limb girdles and the limbs are known as the appendicular skeleton.

From the diagram in Figure 39, it is easy to see that the ribs and the **pelvis** quite literally are suspended from the central structure of the spine by means of joints stabilized by ligaments and muscles.

The shoulder girdle is also partially suspended from the vertebrae of the dorsal spine. The scapula is held against the ribs by muscles attached to the vertebrae. It is attached at the front, by means of the clavicle, to the breast bone.

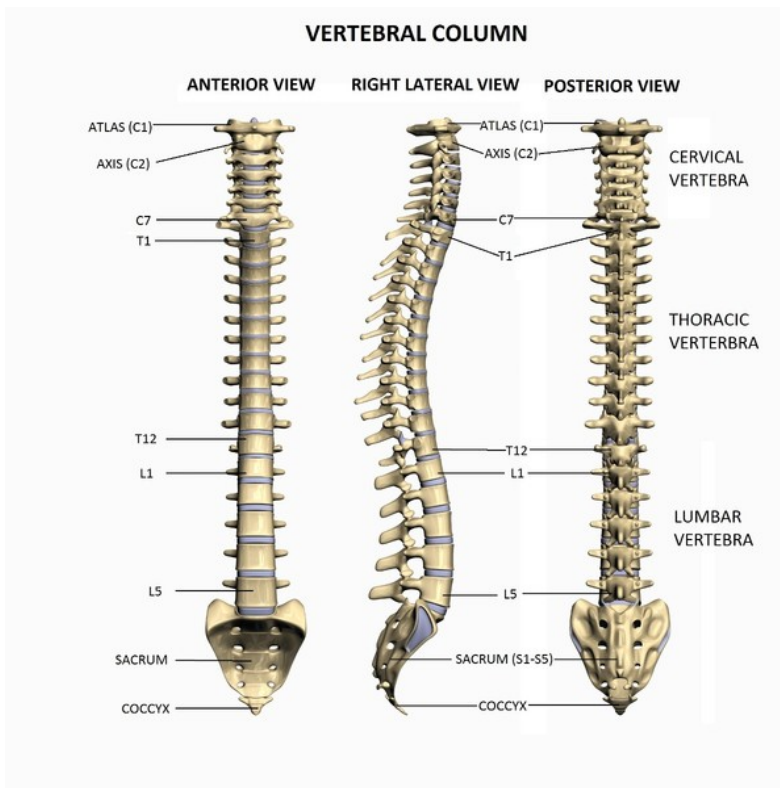


www.studyblue.com

The skull (also called the **cranium**) is a bony box composed of flat bones joined by very short and rather convoluted fibrous joints. It has a large hole (the foramen magnum) at its base for the spinal cord to pass out and down the tunnel formed in the middle of the vertebral column. The two eye sockets (**orbits**) at the front have small holes to allow nerves to pass from the eye ball to the brain. There are a small number of very small holes around the front of the foramen magnum to let a few nerves pass through which supply structures around the face and mouth (cranial nerves). Otherwise the bony box is closed. The result is a very robust container which accommodates and protects the brain. This is fine for preventing damage from minor knocks and for providing a good site for the eyes and nose. However if the brain bleeds, following a more serious accident, or swells for similar reasons or because of a growth then there is little spare room. This means that the brain is very susceptible to anything that takes up space and causes a rise in pressure within the skull (**rise in intra-cranial pressure**). If this happens the blood supply cannot get through to the brain cells, which are highly dependent on an oxygen supply. Minor reductions in oxygen result in brain dysfunction such as confusion and eventually loss in consciousness. Severe lack of oxygen (**hypoxia**) is rapidly fatal.

14. THE REGIONS OF THE SPINE

The different regions of the vertebral column have a slightly different structure, range of movement and function.



14.1 Cervical

The cervical spinal region consists of seven vertebrae that are found in the area we commonly call the neck. This is the most mobile section of the spine. The top two bones, the atlas and the axis, are particularly mobile and these bones and their articulation with each other enables most of the rotation of the head from side to side. The rest of the bones and joints in the neck allow mainly anterior or forward flexion and extension - or nodding of the head. The region is very susceptible to injury and wearing diseases because it is so mobile.

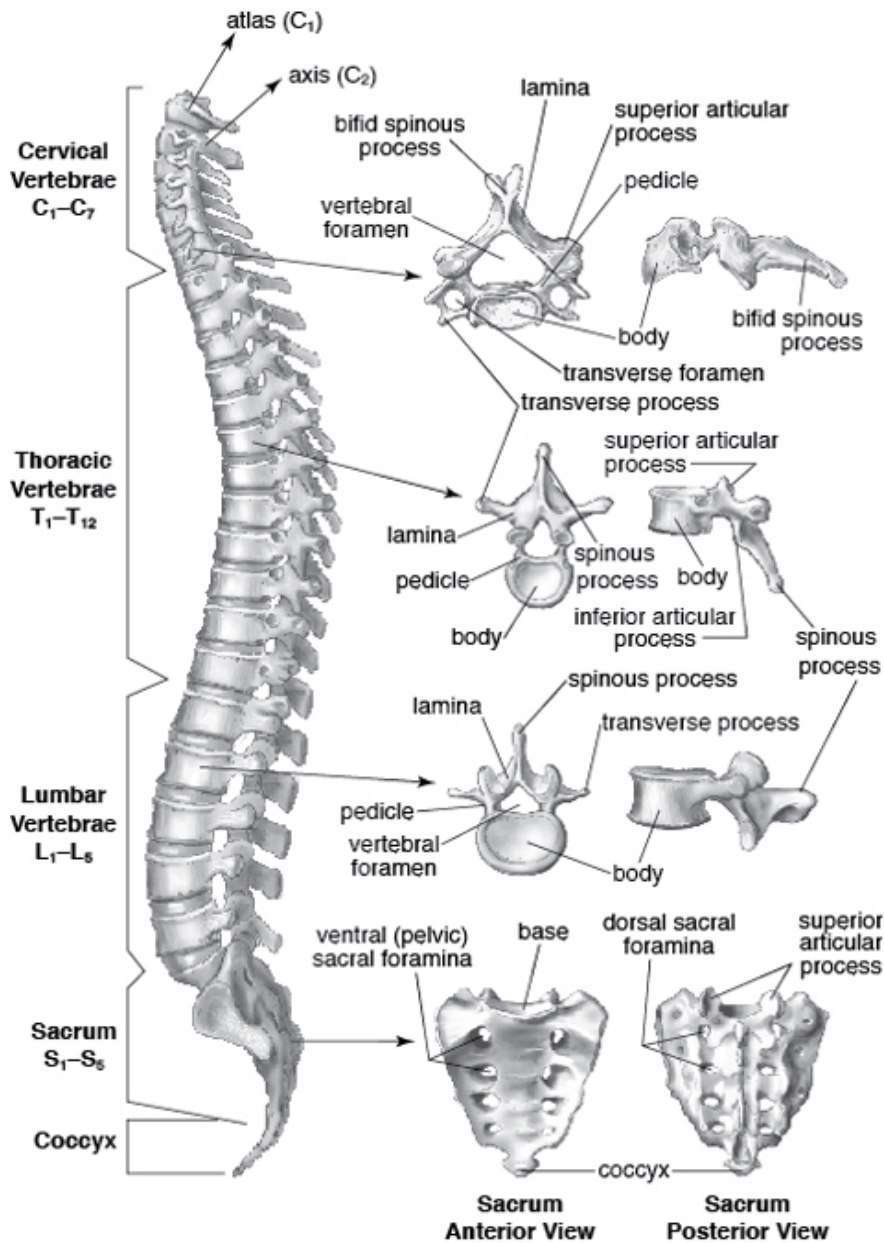
14.2 Dorsal (thoracic)

The dorsal region consists of twelve vertebrae. Each vertebra is attached to a pair of ribs by a synovial joint which permits the ribs to move up and down as we breathe. The ribs give added rigidity to the dorsal spine and so it is not very mobile. There is only a very limited degree of flexion and extension and little rotation.

The dorsal spinal region is very strong, being supported at the front by the ribs and chest muscles. Injury here is less common and wearing disease rare. If this region is fractured, paralysis caused by damage to the spinal cord almost always follows.

14.3 Lumbar

The lumbar region consists of five, although very occasionally six, vertebrae. It is a very mobile section of the spine which permits a large amount of flexion and extension and some rotation. The region carries relatively high loads and so it is very prone to injury and wearing diseases.



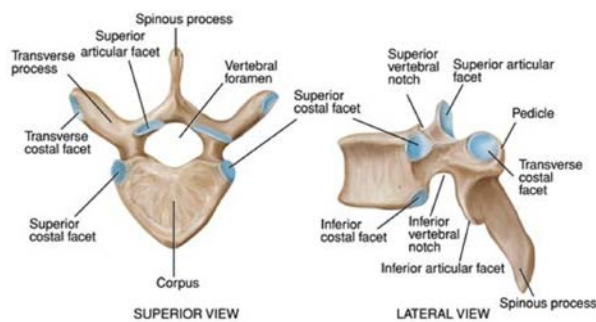
14 . 4 Sacrum and Coccyx

The sacrum consists of a triangular shaped bone which is really five vertebral segments fused to form one irregular bone. There is of course no movement at the sacrum itself because it is made of fused segments. Like the other vertebrae it also has nerves coming out of it. The junction between the sacrum and the lumbar spine is very mobile and so is a site prone to wearing diseases. The sacrum not only forms part of the spine but it also forms one of the three bones of the pelvic ring, as described in Unit 2A. Its principal role is to provide a link between the pelvic girdle and the lumbar spine. The coccyx is a primitive residue of our tail! There are no nerves associated with coccygeal segments.

15. THE VERTEBRAE

15 . 1 Typical Vertebra

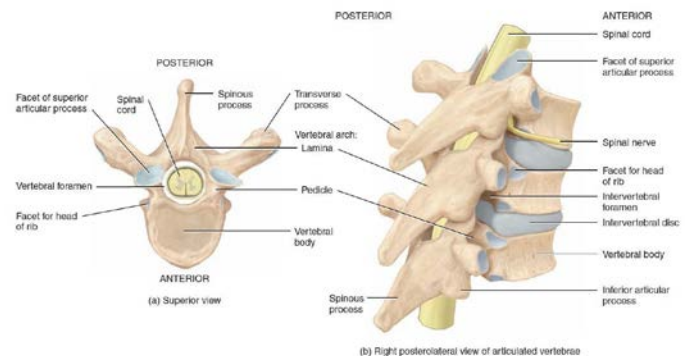
The spine is made up of a stack of vertebrae, which are irregular bones. Each vertebra consists of a cylindrical shaped bony **body**, which is separated from the adjacent vertebrae at the front by an **intervertebral disc**, which will be described in detail later.



SUPERIOR VIEW

LATERAL VIEW

www.studyblue.com



(a) Superior view

(b) Right posterolateral view of articulated vertebrae

www.jambi-jambi.com

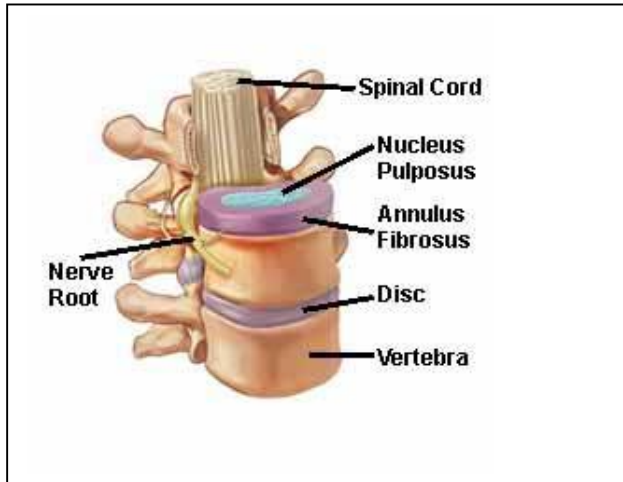
At the rear of the spine there is an arch of bone (the neural arch) on each vertebra which abuts onto similar arches on adjacent vertebrae forming a tunnel or conduit, known as the **spinal foramen**, down which the spinal cord and nerves pass.

On either side of the arch on each vertebra is a pair of synovial joints known as facet joints. The upper facet of a vertebra articulates with the lower facet of the vertebra above. The lower facet articulates with the upper facet of the vertebra below.

Each vertebra has three bony bars projecting from it. The one at the back is the spinous process and the ones on either side are the transverse processes. They are anchorage sites for ligaments and muscles which stabilize and move the spine.

15 . 2 The Intervertebral Disc

These are cylindrical discs between the vertebrae. They are very prone to disease and so it is important to understand a little about their structure and function. It is also important to realise that they do not really function in isolation but that the whole system of bones, ligaments, muscles and discs works together in maintaining the structure and mechanical function of the spine.



<http://www.pioneerhealthcare.co.uk/services/neurosurgery/back-conditions/intervertebral-disc-prolapse>

Structure

The disc is made of two layers: the inner **nucleus pulposus** and the outer **annulus fibrosus**.

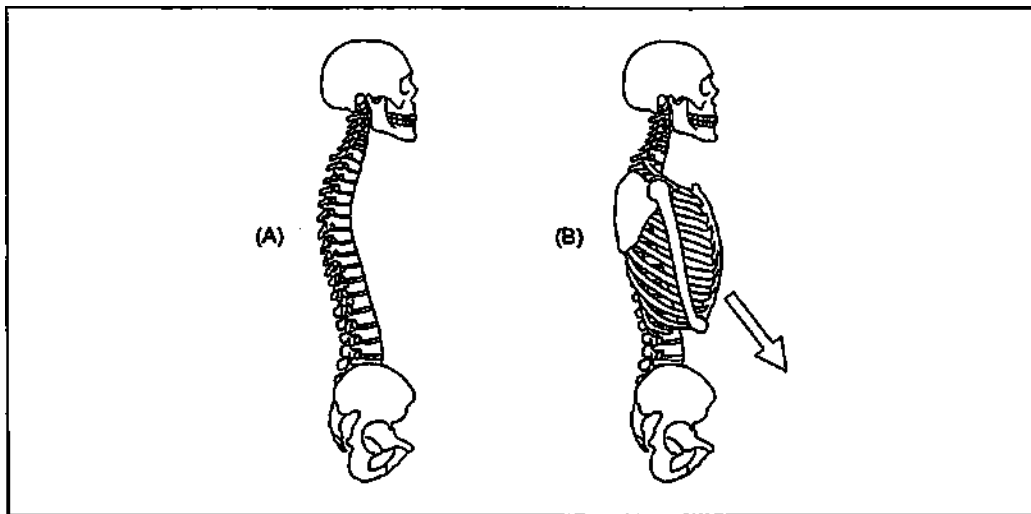
Function

The function of a disc is to absorb shock and prevent jarring of the axial skeleton. It can also distort in any direction and so, together with the synovial facet joints, allows movement of the vertebral column whilst maintaining overall stability during load bearing.

16. SPINAL STABILITY

There is no need to know about the muscles and ligaments of the spine in detail. The most important aspect of these structures is their contribution to the stability the spine.

If we draw a picture of the spine and include the curves as discussed earlier, we are aware that the" curves are balanced (see Figure 46A). However when we hang the ribs, chest contents and abdomen on the spine there is a natural tendency for the whole structure to fall forwards (see

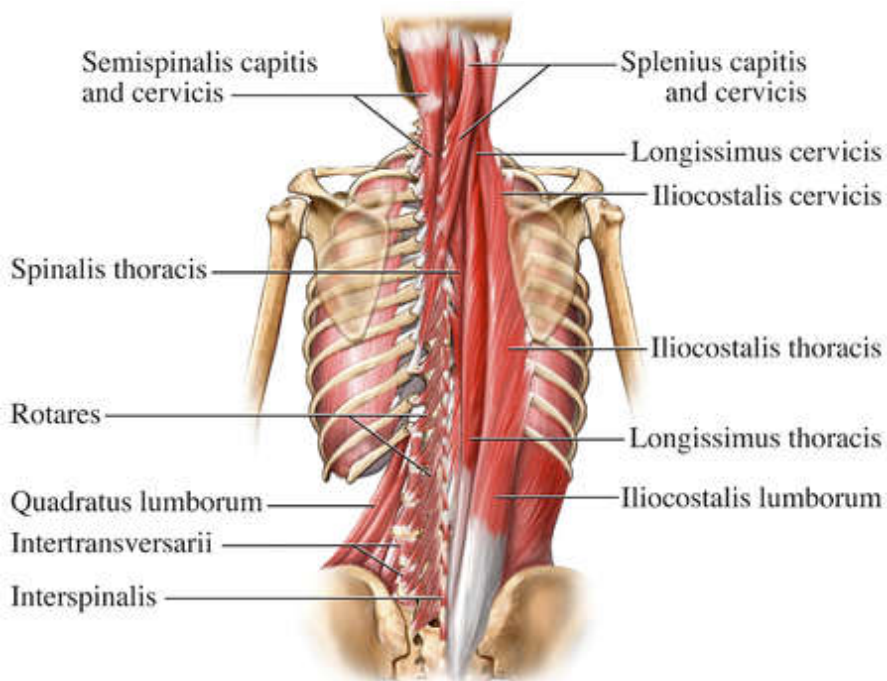


The factors which maintain spinal stability are:

- ◆ Muscles,
- ◆ Ligaments, and
- ◆ Facet joints.

16.1 Muscles

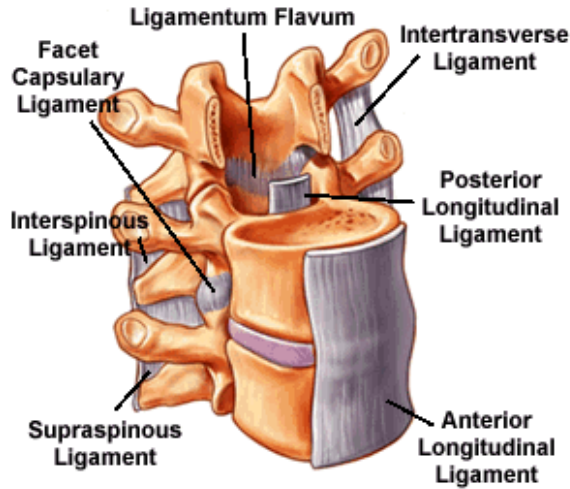
Pairs of very strong, short muscles lie either side of the vertebral column and are attached to the spines and transverse processes of each vertebra. These muscles may be called collectively the **erector spinae**. They have a rich blood supply and nerve supply which arises from the adjacent nerve roots. They are very prone to minor tears from over-exertion in manual lifting and this accounts for many episodes of acute backache.



16.2 Ligaments

The neural arches are joined by a yellow-colored ligament called the ligamentum flavum. This ligament is elasticated allowing it to stretch during flexion, when the neural arches open up a little at the back. There are other short ligaments attached around the facet joints which are very tough and very important in providing stability in the posterior of the vertebral column.

The posterior part of the vertebral bodies are held together by the intervertebral discs and a long posterior spinal ligament which runs from top to bottom of the spine.



<http://www.coloradospineinstitute.com/subject.php?pn=anatomy-ligaments-17>

16.3 Facet Joints

Facet joints have sloped surfaces which permit some movement from side to side, but generally their alignment stops one vertebra sliding forward on another. They are not in themselves sufficient to stop this happening. The ligaments are the most important stabilizing factors in the vertebral column.

17. THE SPINAL CORD

17.1 General Structure and Function

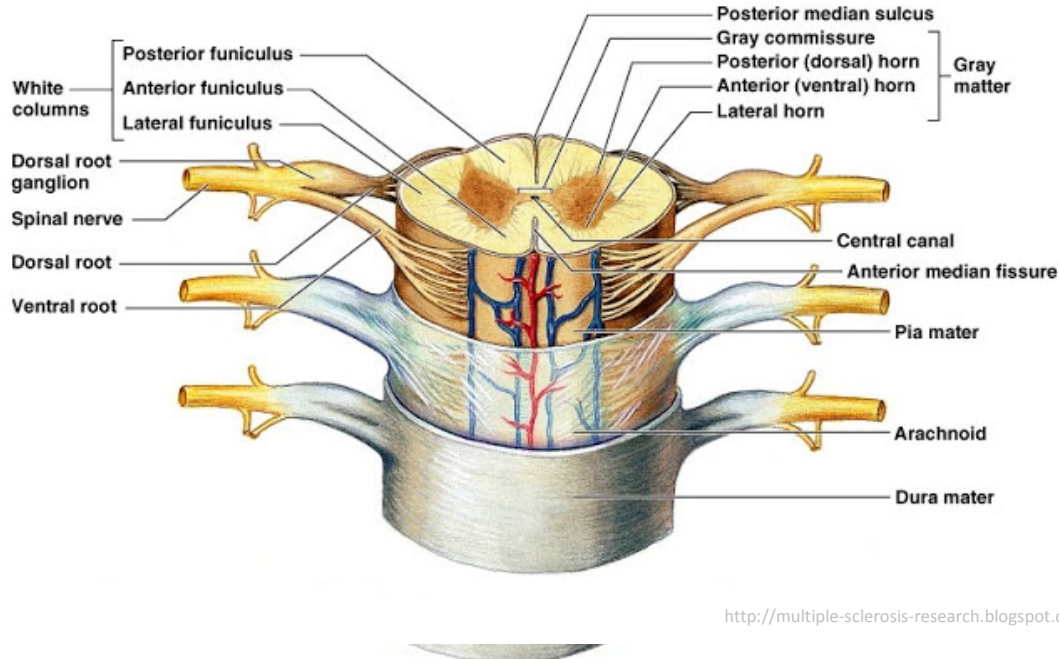
The spinal cord is part of the central nervous system. It has the following functions:

- ◆ passage of information from the brain to the peripheral parts of the body
- ◆ passage of information from the periphery to the brain
- ◆ a certain amount of processing of incoming and outgoing information - spinal reflexes

The spinal cord consists of bundles of nerve fibers. Some of these make up sensory nerves which carry sensory information from the periphery to the brain. Others make up motor nerves which carry impulses from the brain to the muscles.

Nerves carrying sensory information are grouped at the back of the spinal cord and are known collectively as the **dorsal columns**. Nerves carrying impulses from the brain to the muscles are grouped at the front and are known as **anterior columns**.

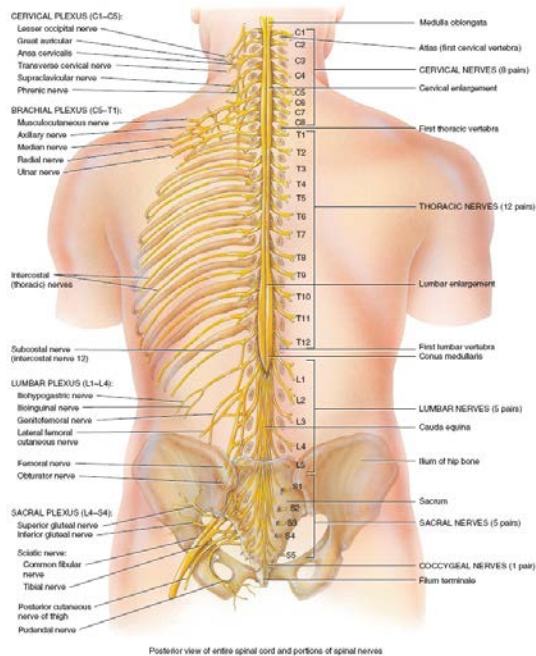
If you look at a cross section of the spinal cord you will see that there is a butterfly-shaped grey central part - the **grey matter** - surrounded by a whiter area - the **white matter**.



<http://multiple-sclerosis-research.blogspot.com/2013/09/imaging-spinal-cord.html>

17.2 Nerve Roots

Nerve roots are the connection between the spinal cord and the spinal nerves which supply the muscles. There are thirty one pairs of spinal nerves connected to the spinal cord. Once they emerge from the spinal region they form a bundle of fibers are called **peripheral nerves**.



http://higheredbcs.wiley.com/legacy/college/tortora/0470565101/hearthis_ill/pap13e_ch13_illustr_audio_mp3_am/simulations/hear/spinal_cord_and_nerves.html

SUMMARY

In this unit of the Anatomy and Physiology module you have studied anatomy in the various regions of the body. Naturally we have paid special attention to the musculoskeletal system. You will remember most of the material, which is after all a very brief summary of a very detailed and complex subject, if you try and apply it in your everyday work. When you work on an arm or a leg for example try to go through in your mind the names of the bones, muscles and joints of the part under your working fingers. If possible try and find a partner in your department who can quiz you using each other as examples. At the end of this unit you should be familiar with all the common names of the various structures we have discussed and slowly you will get used to thinking of them in a very familiar way as you build up a mental three dimensional picture of how they all fit together.

GLOSSARY

cuboid bone	lower limb	phalanges
cuneiform bone	pelvic girdle	intrinsic muscles
metatarsals	acetabulum	extrinsic muscles
phalanges	prime mover	appendicular skeleton
subtalar joint	secondary mover	axial skeleton
inversion	antagonists	vertebral column
eversion	agonists	spine
hallux	glutei	vertebra
bunion	adductor	lordosis
clavicle	quadriceps	kyphosis
scapula	hamstrings	cranium
humerus	CNS	foramen magnum
radius	PNS	neural arch
ulna	avascular necrosis	spinal foramen
shoulder girdle	patella	facet joints
sternum	sesamoid bone	spinous process
rotator cuff	femoral condyles	transverse processes
brachial plexus	collateral ligaments	erector spinae
supination	cruciate ligaments	ligamentum flavum
pronation	menisci	posterior spinal ligament
biceps brachii	quadriceps tendon	grey matter
triceps brachii	patellar tendon	white matter
pronators	dorsiflexion	
supinators	plantarflexion	
carpals	dorsiflexor	
palmar flexors	plantarflexor	
dorsiflexors	achilles tendon	
palmar flexion	navicular bone	
ulnar deviation	talus	
dorsiflexion	calcaneus	
metacarpal		

ORTHOPEDIC MEDICINE

UNIT III

Musculoskeletal Joint Conditions

SECTION 3: Joint Conditions

1. Describe the origins of orthopedics.
2. Define the terms "acute" and "chronic".
3. List the professionals involved in treating orthopedic conditions.
4. Describe the overall treatment objectives in the field of orthopedics.
5. List types of orthopedic problems both in terms of etiology and the frequency with which they occur.
6. List and classify the causes of osteoarthritis.
7. Describe how a doctor may treat arthritis before and after admission to hospital.
8. List the types of operative treatment available for osteoarthritis.
9. Describe the strategies used in planning joint surgery.
10. Discuss the reasons why goals for lower limb joint replacement differ from the goals of upper limb joint replacement.
11. Discuss, in simple terms, the principals of hip and knee joint replacement.
12. Describe the complications, both late and early, which may occur after joint replacement.
13. Describe the role of surgery in rheumatoid arthritis.
14. Describe the two common crystal arthropathies and their long term implications.
15. Define septic joint conditions and describe their basic management.
16. List the common knee problems and discuss the modern methods of managing these conditions.

SECTION 3: Joint Conditions

1 INTRODUCTION - THE SCOPE OF ORTHOPAEDICS

- 1.1 A Brief History
- 1.2 Terminology
- 1.3 The Orthopedic Management Team
- 1.4 Treatment Aims and Objectives
- 1.5 Types of Orthopedic Problems

2. OSTEOARTHRITIS

- 2.1 Cause and Classification
- 2.2 Clinical Picture
- 2.3 Management (how a doctor treats a patient)

3. ARTHROPLASTY

- 3.1 The Limitations of Joint Replacement
- 3.2 The Principals of Joint Replacement
- 3.3 Arthroplasty
- 3.4 Complications

4. RHEUMATOID ARTHRITIS

- 4.1 Cause
- 4.2 Clinical Picture
- 4.3 The Role of Surgery

5. AVASCULAR NECROSIS

- 5.1 Cause
- 5.2 Diagnosis
- 5.3 Management

6. CRYSTAL ARTHROPATHIES

- 6.1 Gout
- 6.2 Pseudogout

7. SEPTIC ARTHRITIS

- 7.1 Acute Septic Arthritis
- 7.2 Chronic

8. MECHANICAL KNEE PROBLEMS

- 8.1 Clinical Presentation
- 8.2 Meniscal Lesions
- 8.3 Loose Bodies
- 8.4 Cruciate Ligamentous Lesions
- 8.5 Dislocation of the Patella

SUMMARY

GLOSSARY

SECTION 3: Joint Conditions

1. INTRODUCTION -THE SCOPE OF ORTHOPEDICS

1.1 A Brief History

Orthopedics literally means "straight children". The title of the subject reflects its history of dealing with musculoskeletal abnormalities occurring at birth or in children as they grow and develop. Birth abnormalities are far less common now than in the past, probably due to improvements in the nutrition and general health of pregnant women. Childhood disease related to diet, such as vitamin C and D deficiency causing scurvy and rickets, is also less common, reflecting improvements in the nutrition of growing children. Other diseases such as Tuberculosis and Polio, which affected the musculoskeletal systems, were much more common in children in the past. Indeed, bone infections and tuberculosis (TB) were very frequently fatal before the second world war. These conditions are less common now because of improvements in treatment (due to the use of antibiotics) and immunization programs.

Nowadays the field of orthopedics has grown to encompass the whole range of diseases affecting the musculoskeletal system.

If you are interested in reading more about the history of orthopedics, the introductory chapter in your recommended text is useful, and "A Source Book of Orthopaedics" by Bick is fascinating (although not available for sale, it may be found in any hospital library).

1.2 Terminology

The following terms are very commonly used in the field of orthopedic medicine:

An **acute** disease is one that strikes the patient suddenly. It is characterized by a certain reaction by the body's immune system whereby the illness is counteracted by the production of a type of body cell found in the blood known as the **polymorphonuclear leucocyte** or **polymorph** for short. The polymorph is so called because its nucleus is in many sections and it is called a leucocyte because it appears white.

A **chronic** disease takes a long time to develop and may last a long time. It can be distinguished from an acute illness because the immune system reacts by producing a different sort of cell in the defense of the body. This cell is the **lymphocyte** which is produced in the bone marrow and also in the spleen (an organ in the left of the abdomen, opposite the liver).

The terms acute and chronic are strictly applied when describing the type of cell produced in response to illness.

When surgeons operate and open something up we tend to add the term "...otomy" to such an operation. For example, opening a joint is anarthrotomy. If something is removed at an operation the term "...ectomy" is added, for example, if we remove a meniscus the procedure is called it a **meniscectomy**.

Definitions of all new terms in the module units will be highlighted as key words.

1.3 The Orthopedic Management Team

When you develop pain or stiffness affecting a joint who will help you?

The answer to this question is becoming increasingly complex as treatment becomes more sophisticated and also much more expensive. The simple answer is that there is no individual who can treat you on their own! The orthopedic surgeon is dependent on theatre nurses and porters, orthopedic nurses, other doctors such as GPs, anesthetists, rheumatologists and general surgeons and paramedical specialists such as

physiotherapists, occupational therapists and technicians. These professionals make up the orthopedic management team.

To illustrate the orthopedic team in action, we can try to answer the original question:

Most people who suffer joint pain start by taking simple drugs such as aspirin and paracetamol. If this proves ineffective, they consult their GP who can prescribe stronger painkilling drugs and contact the community services to provide help. If these measures prove unsatisfactory, the GP may decide to refer the patient to an orthopedic specialist. The orthopedic surgeon would determine whether surgery was necessary and, in conjunction with an anesthetist, whether the patient was in good enough health for an operation. Junior doctors and nurses make preparations for the operation. The orthopedic surgeon is assisted during surgery, by anesthetists, specialist nurses, junior doctors and porters. Physiotherapists, occupational therapists, the GP and the community services (social workers, home helps, meals-on-wheels etc.) will make preparations for convalescence and recovery. So much for the old saying of the doctor "my patient"!

1.4 Treatment Aims and Objectives

Of course our real goal is to return people to normal. Unfortunately, that goal is seldom achieved in any branch of medicine. As described above many conditions will get better anyway and many are, at the moment, incurable.

In most cases therefore, we cannot achieve a cure but we may try to relieve the patient of their principal complaints - pain and stiffness. Most joint replacement surgery is aimed at pain relief, and it is inaccurate to think of an artificial joint being a cure. It is really a salvage operation to remove the damaged joint and replace it with a pain free substitute which will never be as good as the original. It is essential that everyone treating musculoskeletal disorders understands that relief of symptoms is our goal.

1.5 Types of Orthopedic Problems

Many illnesses or "conditions" of the musculoskeletal system are temporary and will get better. We call such conditions "**self-limiting**". Good examples of self-limiting conditions include muscle tears and ligament sprains. On the other hand, many conditions are permanent and have no specific cure. Examples of disorders of this nature include arthritis and abnormalities of birth (congenital abnormalities) which have permanent effects which the orthopedic team have to try and alleviate.

Traditionally, we may define orthopedic disorders according to the origin of the disease. This is somewhat unsatisfactory because we do not always know what causes a disorder. It is nevertheless important to know about this classification as it is still in common usage.

Congenital abnormalities - these are defects associated with development in the womb. They may have a familial or genetic cause or they may be the result of something happening to the mother or to the child whilst in the womb. For example, if the mother has German Measles during pregnancy then the child may have some birth defects. Another example is the child who may be normal until birth and then suffer a lack of oxygen during the process of being born resulting in injury to the brain. This then affects the development of nerves and muscles, causing a combination of mental and physical problems known as cerebral palsy, or more loosely "spasticity".

Inflammatory abnormalities - these illnesses may be associated with bacterial infection causing inflammation of a joint (infective arthritis) or of bone (osteomyelitis). Sometimes the cause of the inflammation is not known. An example of this is a whole body disease known as rheumatoid arthritis which leads to stiff and very painful joints. This group in this system of classification is particularly unsatisfactory because the cause of many inflammations are unknown.

Metabolic disorders - this is a term indicating a group of illnesses which usually cause inflammation, but the cause can be traced back to some abnormality in body metabolism. A good example is gout, which is an inflammation of a joint caused by crystals being deposited on the cartilaginous surface of joints. The crystals are uric acid which is a waste product of cell metabolism. Why the cell metabolism has gone wrong is not properly understood in most cases but at least the cause of the pain can be explained. Abnormalities of vitamin metabolism such as poor absorption of nutrients from the gut, or a dietary deficiency

of vitamins may affect bones and joints and these may be classified as metabolic disorders.

Degenerative disorders - this again is a group of conditions which may result in inflammations. However, in this case it usually refers to joint conditions where the normal structure of the joint has been disturbed through deterioration and wear. Osteoarthritis fits in general into this category, although often there may be a lot of associated inflammation.

Trauma - this is when the musculoskeletal system has suffered damage from an outside physical agent.

Classifications of orthopedic conditions such as this one are of course, to some degree, a matter of opinion. In order to avoid confusion in this module, I propose to present the conditions of the musculoskeletal system in 5 groupings which reflect their importance, i.e. how common they are:

- ◆ arthritis and other joint conditions
- ◆ back pain
- ◆ conditions of childhood
- ◆ common adult disorders
- ◆ common fractures

Of all the conditions treated by orthopedic surgeons, arthritis (joint pain) takes up most of our clinic and operating theatre time. Arthritis occurs in all races all over the world but is most common in the elderly. It is therefore important to understand this orthopedic condition above all others. In general terms it is a painful and distressing disorder which has profound effects on the quality of life. There is no specific cure and all treatment strategies are based around the relief of the symptoms: pain and stiffness.

2. OSTEOARTHRITIS

Osteoarthritis is a condition of pain and limitation of movement of joints associated with excessive wear of articular cartilage resulting from a breakdown of the balance between the wear and repair processes in the joint. It is more common with increasing age although it would be misleading to suggest that all osteoarthritis is an inevitable accompaniment to old age.

2 . 1 Cause and Classification

It is convenient to classify osteoarthritis according to etiology (cause). The classification starts by grouping patients into those whose arthritis has a known cause (secondary osteoarthritis) and those where the cause remains unknown (primary osteoarthritis). It is important to appreciate that the vast majority of patients fall into the latter category.

2 . 1 . 1 Primary Osteoarthritis

Despite much effort there remains little insight into the causes of this very common condition. In our previous definition we took osteoarthritis to encompass a breakdown in the balance between wear and repair. In the case of secondary osteoarthritis it is perhaps easy to argue that many cases reflect an increase in wear. So it may be assumed that in primary osteoarthritis the problem may be on the repair side of the equation.

Many cases of osteoarthritis are secondary to abnormal mechanical stresses applied to a joint as a result of an injury for example. Perhaps in retrospect therefore, it is possible to classify more and more cases as secondary rather than primary. However we are still left after a rigorous review of cases with a vast majority where the cause is obscure. If the cause was a disorder of body metabolism in general then all or most joints would be affected. In fact, the causative factor must be specific to the affected joint as, normally in an individual, not all joints are affected. There are a few cases within every clinician's experience which do appear to have generalized arthritis but these are rare.

2 . 1 . 2 Secondary Osteoarthritis

In this minority group we see obvious causative factors .which quite reasonably may be assumed responsible for secondary osteoarthritis. These are conveniently listed below with examples as they have been, or will be, discussed elsewhere.

- ◆ Congenital - congenital dislocation of the hip
- ◆ Childhood - Perthe's disease, infection
- ◆ Trauma - fracture into a joint
- ◆ Metabolic - gout, crystal arthroplasty
- ◆ Infection - TB (tuberculosis)
- ◆ Chronic inflammatory - rheumatoid

2 . 2 Clinical Picture

Osteoarthritis can appear at any age but becomes increasingly common later in life. In the younger patient there is usually a recognizable predisposing cause as indicated in secondary arthritis above, but not always so.

2 . 2 . 1 History (what the patient tells the doctor)

The patient complains of pain and associated loss of function of the affected joint and limb. Stiffness of the joint is also a feature but nearly always is secondary to pain. In other words it is unusual for arthritis to cause stiffness alone.

Usually the onset of arthritis is associated with pain during activity. If a lower limb joint is affected the patient is often left with a general feeling of tiredness because of the effort required to move about. Help is sought from the General Practitioner when simple pain relief (analgesia) no longer adequately controls the pain. Specialist help from an orthopedic surgeon or a rheumatologist (a physician specializing in joint diseases) is usually sought by the general practitioner when the patient's sleep is disturbed. The threshold for referral varies from patient to patient but in general younger patients tend to request help earlier than the elderly, who expect a degree of arthritis as they get older. Management of the problem is heavily dependent on the clinician's ability to distinguish between the degrees of severity of arthritis amongst a very diverse population, and to treat and refer the patient for surgery appropriately.

2 . 2 . 2 Examination

The symptoms of osteoarthritis are pain and an associated limitation of movement. It is important to appreciate that the limitation of movement during a routine examination will be less than any limitation observed during an examination under anesthetic. Once this is appreciated then the clinician will soon come to realize that successful results of surgery are related to adequacy of pain relief rather than to improvements in mobility of the joint.

2 . 3 Management (how a doctor treats a patient)

All management is aimed at pain relief and, through this, return of function. The ultimate way of relieving pain is surgery although there are general measures which will alleviate symptoms and postpone the need for operation.

2 . 3 . 1 Non surgical (conservative) options

These include:

- ◆ weight loss
- ◆ use of a cane

- ◆ rest and physiotherapy
- ◆ Analgesia through medication may be used subsequently or in parallel with these measures.

Weight loss: Lower limb joints in particular are subject to large loads which are the result of the leverage exerted by the muscles around the joints. The resulting joint loads may be several times the body weight they are supporting. In the hip for example, joint loading during the stance phase of walking can reach about three times body weight and during activities of greater hip muscle exertion joint loading can reach five times body weight. (This will be discussed more fully in the Biomechanics module). This means that quite modest reductions in body weight will result in significant reductions in the total loads being borne by the joint. Also, weight loss is usually accompanied by a general improvement in well-being which often affects the overall pain experienced by the patient.

Walking cane: In lower limb joint disease, particularly in the hip, the use of a stick in the opposite hand means that the shoulder girdle can help in tilting the pelvis and so help in weight bearing. Normally when we walk, when we have our weight on the right leg, the gluteal muscles on the right side contract to tilt the left side of the pelvis upward, permitting the left leg to swing forward freely to make contact with the ground. Efficient walking is highly dependent on the ability of the abductor muscles to carry out this function for every stride. The use of a stick has the effect of reducing the work required of the weight bearing abductor muscles thereby dramatically reducing the muscle induced loads on the hip.

Physiotherapy: The role of physiotherapy and rest remains controversial and a balance is required. Over-exercise cannot in the long term be beneficial but some exercise does relieve stiffness and muscle spasm and therefore pain. Young sufferers should be advised against excessive unnecessary activity and a change to a light job is useful if practicable. Total rest is however equally counterproductive, especially in the elderly where a maintenance of the activities of daily living is essential. Remember that muscles work most efficiently when they are in regular use. Stretching them in exercises helps them maintain natural tone. Excessive resting of muscles around a painful joint will make them go into a spasm which is in itself painful and inhibiting.

2.3.2 Surgical Options

For most forms of arthritis there are four surgical options:

- ◆ Nothing
- ◆ Arthrodesis
- ◆ Osteotomy
- ◆ Arthroplasty

Nothing: Doing nothing should always be borne in mind as an option. The patient must be aware that the benefits of surgery must outweigh the risks. For very disabled patients in a great deal of pain, the option to take the risks of surgery must be considered. Following a careful and full explanation of the risks and benefits of surgery by the doctor, the patient can take the decision to undergo surgery. Provided the patient has a good grasp of the risk: benefit ratio in their particular case, then they may take the lion's share in a decision to have surgery.

Arthrodesis, or surgical stiffening of a joint in a position of function, is an appropriate operation for a young person with a painful and limited range of movement in the affected joint. The more attractive option of joint replacement is not a safe choice for reasons which will be explained later. Essentially, a relatively stiff and very painful joint is cut out and the remaining raw bone ends are held together either by an external splint or screws until they heal with a bony bridge. In the hip for example, fusion in thirty degrees of flexion and some adduction produces pain free functional gait, whilst permitting sitting. It is more acceptable to the male than to the female as any hip fusion is likely to interfere with female sexual activity. Fusion is not a technically easy procedure in large joints such as the hip because the bones are difficult to hold together once the joint has been removed. The operation requires a prolonged recovery period of up to six months, often in a plaster splint.

The long term disadvantage of arthrodesis is that it puts stress on the adjacent joints. For example in the hip this means extra stress on the lumbar spine and knee as well as the opposite hip. However, this problem

may be anticipated by electing to fuse the joint until the fifth decade and then performing a second operation to "unpick" the arthrodesis and convert it to an arthroplasty. This double operation has proved to be surprisingly effective for the hip, giving good return to function.

Joints that can be usefully fused are the ankle and the wrist. They are small joints making it easier to hold the bone ends together. Also these are joints which are at present difficult to replace and which have a limited range of functional movement in any case.

Fusion is however still a difficult option for patients, however logical the procedure. This is because patients generally have unrealistic ideas of the effectiveness of arthroplasty.... "If we can go to the moon now - why do you need to fuse my hip?"

Osteotomy consists of the surgical realignment of a joint. The aim of the operation is to redirect forces across a joint so that they more evenly distribute the load to which the joint is subjected. Generally osteotomy is performed where a joint has become deformed and the loads crossing it are distorted by the deformity. A good example is at the knee where, if a person becomes bow legged, all the load passes down the medial side of the joint rather than down the middle. Try standing bow legged and feel the strain on the inside of your knees.

Where do you feel the strain when standing knock kneed?

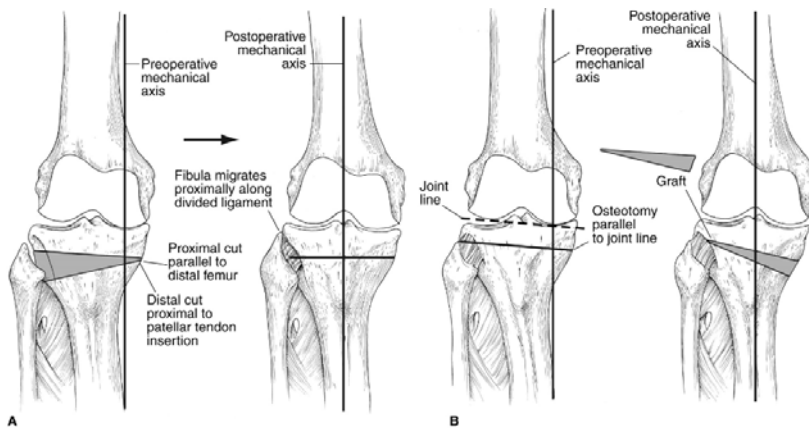


FIGURE. Proximal tibial lateral closing wedge (A) and medial opening wedge (B) osteotomy to correct posttraumatic varus deformity. Osteotomy location and wedge size are selected to optimize healing across a broad, cancellous surface and restore the native mechanical axis..

<https://www.jaaos.org/content/17/2/88/F1.expansion>

Osteotomy is an option used widely in the continent of Europe and with varying degrees of popularity in the United Kingdom and America. This difference of attitude is traditional and otherwise impossible to explain. Accurate surgical realignment is technically highly demanding and very time consuming. Perhaps the most likely reason for its varying popularity is that widely differing results are achieved. Even in the best hands osteotomy can only be viewed as a temporary measure lasting from one or two years to around ten. This is because although a degree of correction may be achieved by surgery the basic underlying abnormality, which is rarely understood, has not been tackled.

Osteotomy may be used to realign any deformity in any bone. For arthritis, osteotomy has been found valuable in the young who have maintained a good range of movement, despite the pain which is typical of the early stages of osteoarthritis. Conversely if the range of movement is severely limited then a simple re-alignment is unlikely to succeed because useful function cannot be restored.

The hip and the knee are suitable for osteotomy, and we may use the hip joint as our example again. Osteotomy may be performed on the pelvic side, either by forming a shelf or by total acetabular realignment. It may be performed on the femoral side by altering the angle of the femoral neck to change the attitude of the femoral head relative to the acetabulum.

In general terms osteotomy may be said to be a good operation in young people who have retained a good range of motion, and have a reasonable preservation of articular cartilage

3. ARTHROPLASTY

The name "arthroplasty" literally means "to reshape a joint". Before effective replacement joints were developed surgeons attempted to remodel a distorted joint by cutting it and often covering the surface with a material from the body, such as muscle. These techniques were entirely inadequate. Now arthroplasty is taken to mean the replacement of one or both surfaces of a joint.

Patients should understand the limitations of joint replacement surgery - it can relieve pain and the restriction of movement which pain brings, but is not likely to alleviate disability due to stiffness caused directly by the disease within the joint.

3.1 The Limitations of Joint Replacement

The reason why arthroplasty of the hip is held in such high regard is due to the success of the operation. The current level of 50,000 cases per annum in the UK was achieved largely through the work of Sir John Charnley. For the majority, artificial joints work very well indeed and well in excess of ninety percent will still be in situ after ten years. However, the majority of cases are older patients who are not naturally as active as the young and because of retirement from work can regulate their activities to protect their new artificial joint.

It is not always appreciated that the consequences of the operation failing early can be devastating. This will be discussed below, but in broad terms it is important to appreciate that a hip replacement is an artificial joint, not a transplant. From the moment it is put in, it begins to wear out, whereas a natural joint has the capacity to regenerate. The strategy of replacement should be to provide a joint which outlasts the likely life-span of the patient. At our current level of knowledge this cannot be guaranteed for the younger patient, and so alternatives are still required.

3.2 The Principles of Joint Replacement

The same basic rules discussed above apply to all joints and provided that they can be obeyed, arthroplasty may be performed. The replacement of the knee joint now is a very successful operation, although like the hip it is more successful in older patients. In the United Kingdom osteoarthritis of the knee is the most common disabling form of the disease and the emergence of a successful prosthetic joint is very encouraging.

In the upper limb, the relationship between pain relief and function is quite different from that observed in the lower limb. In the case of the arm, the loads involved are quite low but the range of motion required for normal function of the elbow and shoulder joints is large. Remember that arthroplasty tends to improve pain related loss of function but does relatively less for intrinsic stiffness. This is because soft tissue distortion of the capsule and ligaments tends to remain after replacing the articular surfaces. In the upper limb this poses a problem if arthroplasty is contemplated. For example, the elbow must flex to ninety degrees to permit eating (try reaching your mouth with an arm fixed at a greater angle) and must extend more or less fully to reach the anus for cleansing. Therefore any surgery must cater for these two fundamental activities of daily living.

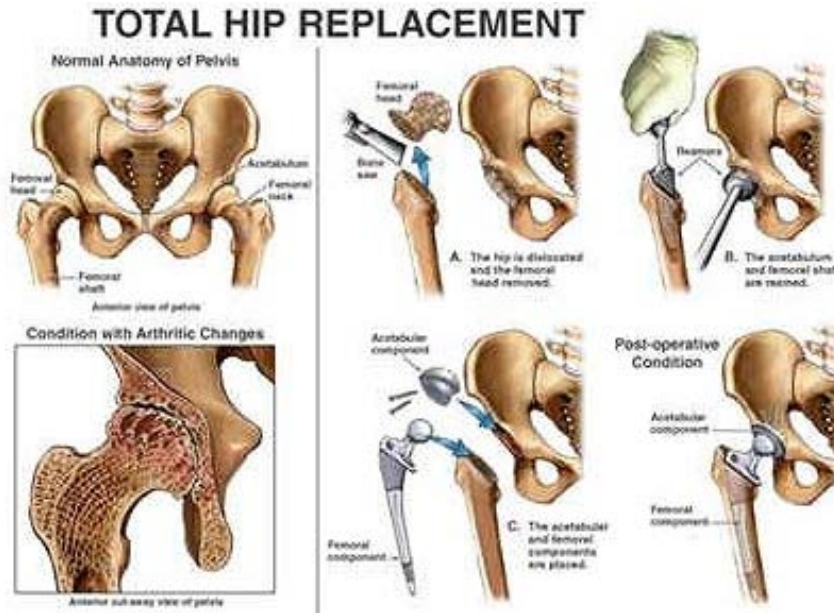
Slowly we are seeing elbow and shoulder joint replacements approaching these high functional requirements but not so for the fingers or the wrist.

3.3 Arthroplasty

The key to understanding joint arthroplasty is to appreciate the requirements of an artificial joint. The new joint must be capable of a functional and pain free range of motion, but be able to withstand the significant forces placed upon it without undue wear and without working loose. It must achieve all this whilst having the same stability as the natural joint.

On first reflection it is perhaps surprising that the hip joint proved to be the first really successful replacement as this joint has tremendous demands placed upon it. However, although the loads are large this is offset by the generally stable configuration of a ball and socket and the fact that the functional range of hip motion is in

practice fairly limited. In practical terms if we retain ten or fifteen degrees of extension and thirty to fifty degrees of flexion with a few degrees of abduction and rotation, particularly in extension, then useful hip function in daily living is maintained.



<http://www.orthopedicsurgerybook.com/hip-replacement-surgery-pain-resurfacing.php>

In the case of the knee the functional range of movement is surprisingly small, although ideally ninety degrees of flexion must be achieved in order to get up and down stairs. In the knee, stability in extension is essential so that we can support the full weight of the body whilst standing on a single straight leg. To achieve this the surgery must achieve an accurate soft tissue balance through dissection of the capsule and the ligaments. The modern knee replacement consists of two new, smooth surfaces but this is only half the operation. The surgeon must balance the collateral ligaments by cutting tight parts of the ligaments and then putting in artificial surface replacements of sufficient thickness to re-tighten the ligaments so that the medial and lateral collateral ligaments are under equal tension. This is best explained in the diagrams below.

3.4 Complications

Complications of arthroplasty may be divided into those which are common to any major surgery and those which are specific to the operation.

3.4.1 General

Most patients undergoing surgery for arthritis are elderly. While being old is unlikely to be a risk, it is true to say that older people are more likely to have medical conditions predisposing them to risk. If these are not recognized then problems may arise.

Anyone undergoing major surgery is prone to problems such as chest infection and urinary tract infection. They are also prone to developing pressure sores if they are not nursed carefully. There are also the risks of deep vein thrombosis (a blood clot in the veins of the leg and pelvis). This is dangerous because the blood clot may dislodge from the leg and become lodged in the lungs causing a pulmonary embolism (a blood clot in the lung), which is frequently fatal. Those undergoing hip and knee surgery are especially at risk. This is true in general for any surgery in and around the pelvis.

3 . 4 . 2 Specific complications

These may be further classified into early (soon after the operation) and late (months or years afterwards) complications.

3 . 4 . 2 . 1 Specific early

Dislocation

In the immediate post-operative period the prosthesis will not be fully supported by the surrounding soft tissues. The muscles and their proprioceptors may be temporarily out of action, through surgical trauma and pain inhibition. A capsule of scar tissue will not yet have formed around the prosthesis. The hip in this period is at risk from dislocation, particularly before the effects of anesthesia wears off. The risk of dislocation is reduced as time passes but even years after, an injudicious move such as, in the case of the hip, twisting the leg into extreme flexion with adduction and internal rotation may result in a painful dislocation. For this reason the patient will need advice about dressing and may need aids to help in fitting stockings and may also benefit from having a raised toilet seat.

Deep vein thrombosis

As stated above, the patient is at risk from deep vein thrombosis and therefore some sort of protection (prophylaxis) is probably justified. The exact type of the prophylaxis is controversial. Blood clots may be reduced in size and frequency by using drugs such as heparin which slightly inhibit clotting. The wearing of support stockings is thought to help blood flow by preventing blood pooling in the legs as this effect is known to increase clotting. It must be accepted however that this is by no means a clear cut issue and even if prophylaxis is thought advisable, the best agent or technique is by no means universally agreed.

Infection

Infection is always a risk and this can be early or late. Many factors make an artificial joint prone to infection, not only from recognized hospital bacteria such as staphylococcus aureus but also from organisms normally regarded as natural inhabitants of the human body (commensals), such as staphylococcus albus, universally found on the skin. It would appear that the presence of foreign material inhibits the body's ability to kill bacteria. The reasons why this is so are not fully understood. Infection of a prosthesis is such a disaster, that every effort must be made to avoid it. Techniques include antibiotic prophylaxis and the provision of an ultra-clean air operating environment.

If all these precautions are taken then immediate infections should be eliminated and long term infections reduced to less than 0.1%. Unfortunately in the United Kingdom, NHS resources do not always provide the ideal operating environment and this figure is often exceeded, with rates of one to three percent being not uncommon. Certainly anything greater than this is entirely unacceptable.

3 . 4 . 2 . 2 Specific late

Problems with joint replacement may occur as late as ten years after surgery or longer. The principal problems are late infection, loosening and wear.

Infection

The causes of infection have already been discussed and it is probable that most cases of infection are caused at the time of insertion of the prosthesis. Why they only become apparent later is not understood. It is also suggested that infection may be blood borne as a consequence of contaminations of the blood stream (bacteriaemias) commonly encountered in normal life. For example, there is circumstantial evidence that some infections may follow tooth extraction which is known to cause significant bacteriaemias and is a cause of heart valve infections.

Loosening and wear

Loosening to some degree is probably inevitable, from the simple passage of time, though the aim of surgical technique is to delay this as long as possible. It is for this reason that we still need the alternative procedures described above and why research must continue to find better materials and methods of prosthetic fixation.

4. RHEUMATOID ARTHRITIS

4.1 Cause

Rheumatoid arthritis is a disorder of many systems of the body and its cause is unknown. It has some clear links with abnormalities of the immune system and there is growing evidence that there may be a genetic abnormality which causes an abnormal reaction to certain types of bacteria. It seems that persons of a certain genetic make up do not react in a normal way to particular bacteria and the result is a disease process which we call rheumatoid arthritis.

4.2 Clinical Picture

The most obvious symptoms are severe pain, swelling and deformity of the joints. The principal joints affected are the small joints of the hands and feet - only in a minority are the larger joints affected. The small joints are affected symmetrically (both hands or both feet) but there is no pattern in the larger joints. There is no known reason for this.

The disease may strike at any age and again, for no obvious reason, women are more frequently affected than men. The patients first notice stiffness, worse in the mornings and improving through the day, in contrast to osteoarthritis, where stiffness tends to be worse after activity.

4.3 The Role of Surgery

The role of the surgeon is to ensure that the patient is as comfortable as possible whilst retaining as much function as possible. Rheumatoid arthritis is a disease to be tackled by a medical team which includes a rheumatologist (a clinician who specializes in joint diseases) who will be responsible for prescribing drugs.

4.3.1 Soft tissue surgery

The disease may result in damage to tendon sheaths and the tendons themselves. Damage may be limited by removing diseased synovial tissue by removing the synovium (synovial membrane) using a procedure called synovectomy. This is a good operation at the wrist for clearing up damage around extensor tendons. Sometimes tendons about the wrist actually rupture and some sort of repair is needed.

4.3.2 Joint surgery

In early disease it is sometimes possible to reduce pain and stiffness by synovectomy. This is of value in the younger patient who retains movement, but who has pain. It is useful at the elbow and wrist where it may be combined with a limited excision of the joint - excision arthroplasty. This relieves pain but because some of the joint has been removed there can never be a full return of function.

Most of the surgeon's role is salvage. The goals are pain relief and return of function, just as in osteoarthritis. The surgeon must be sure that the control of the rheumatoid process by drugs is adequate otherwise doctor and patient may be disappointed. The surgeon should also be sure that it is function he or she is aiming to improve and not deformity. This is particularly true in the hands where even very distorted hands may have excellent function.

5. AVASCULAR NECROSIS

5.1 Cause

Bone tissue death through loss of blood supply can occur in certain circumstances throughout the body. In some cases the cause is clearly traceable to an episode of trauma occurring in an area where the blood supply is particularly vulnerable. Quite often avascular necrosis occurs spontaneously, or for no apparent reason.

5.1.1 Post traumatic avascular necrosis

Areas at risk following trauma include:- the femoral head, the proximal part of the scaphoid in the wrist and the proximal part of the talus. In these situations the trauma can cut the blood supply. In femoral neck fractures the damage to the capsular blood vessels puts the femoral head at risk and in the other two sites a distal blood supply is severed from the proximal part of the bone.

5.1.2 Avascular necrosis of unknown cause

In other areas such as the lunate (one of the small carpal bones in the wrist) and the femoral head, avascular necrosis occurs in less obvious circumstances. Avascular necrosis of the head of the femur is seen following chronic alcohol abuse, high dose steroid therapy and in deep sea divers (Caisson's disease). The cause and effect in these diverse situations remains a mystery. The patient presents with acute and often severe joint pain which is made worse by movement and to some degree relieved by rest. With the passage of time symptoms become indistinguishable from osteoarthritis and then it may be treated as such. Unfortunately many patients with avascular necrosis are young.

5.2. Diagnosis

Diagnosis can be very difficult initially as there are no changes to be seen on an X-ray. Later the bone appears dense, reflecting the absence of blood vessels.

Avascular necrosis may be reversed if a blood supply can be re-established naturally. However, in the re-vascularizing phase the bone is very soft and prone to distort, with secondary arthritic changes. The surgical restoration of bone blood supply is not possible at the moment.

5.3 Management

Treatment is non-specific. If possible the affected joint should be rested. Surgery is of no value in treating the underlying condition and often the surgeon is left to salvage the situation with a joint replacement. As such patients are often young this is, as explained above in the management of osteoarthritis, highly problematical.

6. CRYSTAL ARTHROPATHIES

In these conditions, crystals of the by-products of body metabolism are deposited in the joints, on the surface of the articular cartilage and within the synovial fluid. This occurs either because of some abnormality of metabolism resulting in excess production, or because the kidneys are failing to eliminate them.

They cause a chronic degenerative change in the joint and may be a cause of secondary arthritis. They also cause acute inflammations which tend to settle spontaneously although it is common to reduce the painful effects with drugs.

6.1 Gout

Gout is caused by **urate** crystal deposition. Urate is a waste product of cell metabolism. It becomes deposited in circumstances such as dehydration (particularly post-surgery), and after chemotherapy for cancer. Probably the commonest cause in the west is the injudicious over-use of diuretics, which are drugs used to treat high blood pressure and mild heart failure.

It presents with a hot, tender and swollen joint. Any joint can be affected but it is seen commonly in the knee and less commonly in the first metatarsophalangeal joint. It is important to exclude infection early as this condition tends to mimic gout. If infection is missed it can do a lot of damage to the articular cartilage before treatment is started.

Diagnosis is made by detecting the presence of a high level of uric **acid** in the blood. Normally this waste product is passed out in the urine. A diagnosis is more accurately made by extracting joint fluid through a syringe and testing for the presence of urate crystals.

Gout may be treated using anti-inflammatory drugs which, as well as reducing inflammation, also help the kidneys eliminate urate.

6.2 Pseudogout

Pseudogout may mimic gout but usually has a less acute presentation. In this case the cause is the deposition of a crystal known as **pyrophosphate**, the origin of which is unknown, on the articular surface of the joint. Chronic crystal arthroplasty of this kind causes calcification of joint surfaces and the menisci in the knee. Symptoms may be controlled with anti-inflammatory drugs but long term degeneration is likely.

7. SEPTIC ARTHRITIS

7.1 Acute Septic Arthritis

7.1.1 Etiology

Acute septic arthritis is an infection caused by bacteria which have spread to the joint via the blood from a site of trivial infection, such as a boil. It may occur very rarely from direct penetration of the joint by a sharp object. In adults joint infection is rare unless the joint is already damaged, or the immune defense system is abnormal.

7.1.2 Clinical picture

In children it usually presents with a very unpleasant acute illness during which the child is unwell with a high temperature. The affected joint is stiff and is hot and tender.

In contrast, adults often have a much less acute illness. The chronically abnormal joint may give the false impression of a minor upset. The patient remains unwell for many days before presenting with blood poisoning. Many of these patients die because of the delay in recognizing the condition.

In the relatively rare instance of a young adult presenting with a septic arthritis, often with little constitutional upset, the most likely cause is gonococcus, which is a type of bacteria commonly associated with venereal disease.

7.1.3 Management

Treatment consists of surgery and intravenous antibiotics. The joint should be opened and washed. Antibiotics should be given according to the type of organism causing the infection. The "first guess" antibiotic should be an anti-staphylococcal agent in children as this is still the most likely infecting organism. If this treatment is inadequate then, apart from the risk of a poisoning of the blood stream (septic anemia), the articular cartilage is at great risk and may disintegrate, leading to fibrous or even bony fusion of the joint.

7.2 Chronic

7.2.1 Etiology

Joint tuberculosis (TB) is a bacterial infection resulting in chronic septic arthritis. It is found world-wide although mainly in underdeveloped countries. AIDS patients are particularly prone to this chronic illness. The TB bacteria spread to the joints via the blood. Kidney and joint TB are often found together.

7.2.2 Clinical presentation

The clinical picture is of chronic ill health, weight loss and considerable muscle wasting around the affected joint. The radiographs, (produced from X-rays) show marked thinning of the bone.

7.2.3 Management

Treatment is by drugs and only rarely is surgery necessary. Combinations of antibiotics such as streptomycin, ethambutol and rifampicin are given for many months.

8. MECHANICAL KNEE PROBLEMS

8.1 Clinical Presentation

Knee problems may present as chronic discomfort, or acutely following injury. The patient complains of symptoms:

- ◆ swelling
- ◆ locking
- ◆ giving way
- ◆ pain

8.2 Meniscal Lesions

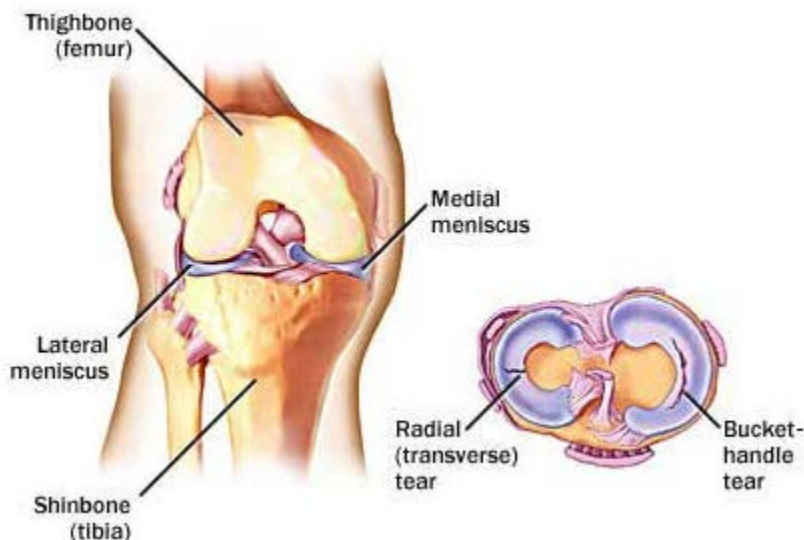
8.2.1 Clinical presentations

Although seen in both sexes meniscal lesions are relatively rare in women, probably because they are not as frequently involved as men in vigorous contact sports. Although not common, they can occur in adolescents and occasionally children are born with an abnormal lateral meniscus. The symptoms are pain, excess fluid in the joint (effusion), and sometimes locking and/or giving way. The abnormality is poorly localized on examination (i.e. there is not a single tender spot), although generalized discomfort may be elicited by gently but forcibly extending the knee.

8.2.2 Etiology and patterns

The principal cause of meniscal lesions is twisting injury, often associated with skiing, or games where studs are worn on shoes or boots. In these situations the foot gets stuck on the ground and then the femur twists over the stationary tibia causing a wrench to the meniscus which may be torn or pulled off the bone.

The medial meniscus is generally more frequently torn than the lateral. The meniscus may be torn at its peripheral attachment to the joint capsule or actually within its substance. The meniscus may split horizontally - a **cleavage lesion**, which is very common in old age. Occasionally these cleavage lesions act like flap valves and allow a buildup of synovial fluid within the meniscus, forming a fluid filled cavity known as a cyst.

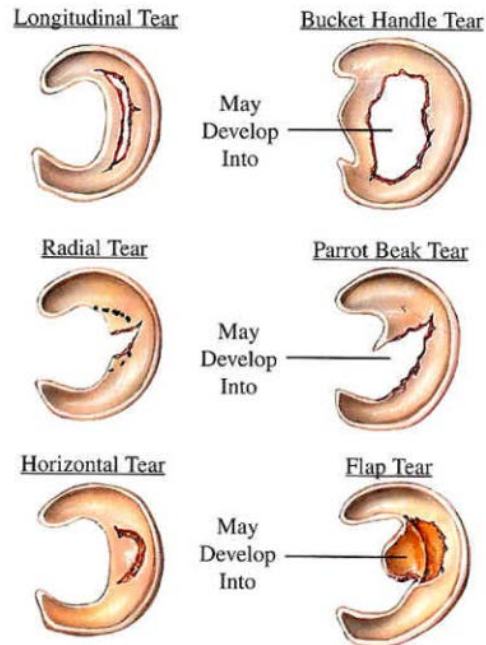


Common pathological tears within the substance of the meniscus are in the vertical plane and can be:

- ◆ a split off one end of the meniscus - the **parrot beak**, and
- ◆ a vertical split, which is anchored at both ends - the **bucket handle**

The consequence of meniscal tear is that the torn part becomes jammed in the joint, stopping it extending.

MENISCUS TEARS

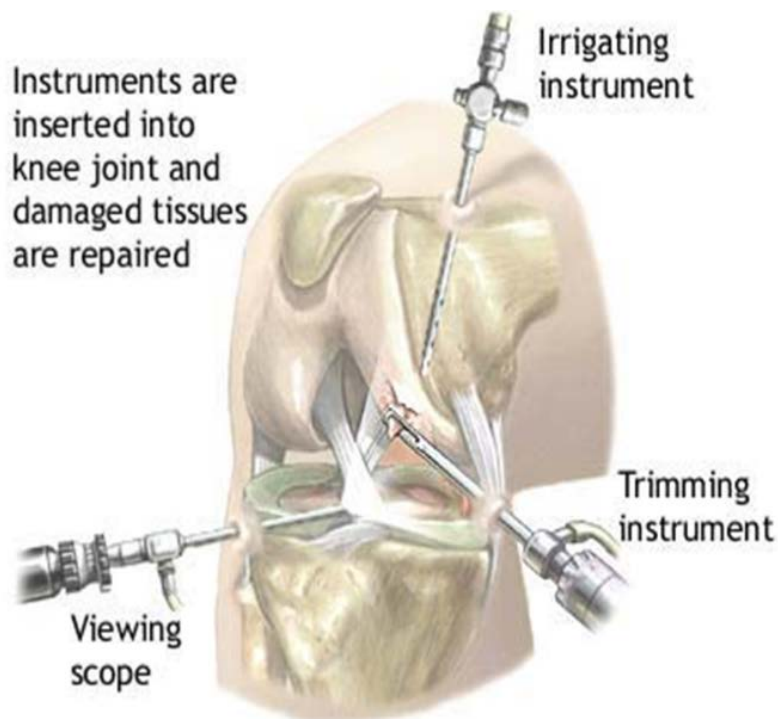


<http://imgbuddy.com/bucket-handle-meniscal-tear.asp>

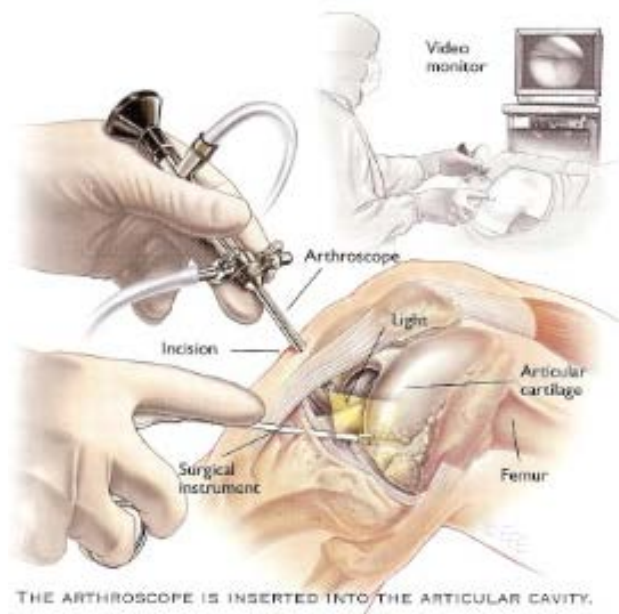
8.2.3 Management

The meniscus is an important structure and as much of it as possible should be preserved during surgery to help in distributing the load between femur and tibia. Peripheral tears can be reattached with sutures. Tears within the substance of the meniscus have no apparent capacity to repair and so the torn peripheral part should be removed.

Once clinical suspicion is aroused, patients should be subject to examination by arthroscopy. This is a technique where a small optical instrument like a telescope, illuminated by a fiber light, is introduced into the knee joint (Figures 9 and 10).



<http://kneeandshoulderclinic.com.au/knees/surgical-conditions/knee-arthroscopy/>



w.orthosurgeon.co.za/content/dr-peter-smith-orthopaedic-knee-arthroscopy-procedures-milnerton-medi-clinic-cape-town

FIGURE. THE VIEW DOWN THE ARTHROSCOPE.

Most meniscal lesions can now be removed via the arthroscope (an **arthroscopic meniscectomy**), although some require a small opening to be made in the joint (arthrotomy). The principal advantage of arthroscopic meniscectomy is that most patients recover from it quickly (within days). Open meniscectomy has a much longer period of rehabilitation.

8.3 Loose Bodies

8.3.1 Etiology

Small fragments of cartilage and bone (osteochondral fragments) may be sheared off in an injury. The knee subsequently swells up from the associated bleeding into the joint (**hemarthrosis**). The osteochondral fragment is called a loose body and is often not resorbed but lives floating free in the synovial fluid. The bulk of the loose body, if not **all** of it, is cartilage and so may be invisible on X-rays.

8.3.2 Clinical presentation

The first incident may settle but months or years later the patient presents with locking, pain and giving way, often with effusion.

8.3.3 Management

Such loose bodies are a nuisance and should be removed, preferably using the arthroscope. Very rarely, in adolescents, osteochondral fragments occur spontaneously. This condition is known as osteochondritis dissecans. Such a condition tends to settle spontaneously but loose bodies may require removal.

8.4 Cruciate Ligamentous Sprains

Soft tissue injuries to the collateral ligaments of the knee heal spontaneously. This is because they have an excellent blood supply. Cruciate ligament tears are quite different for the reasons described below.

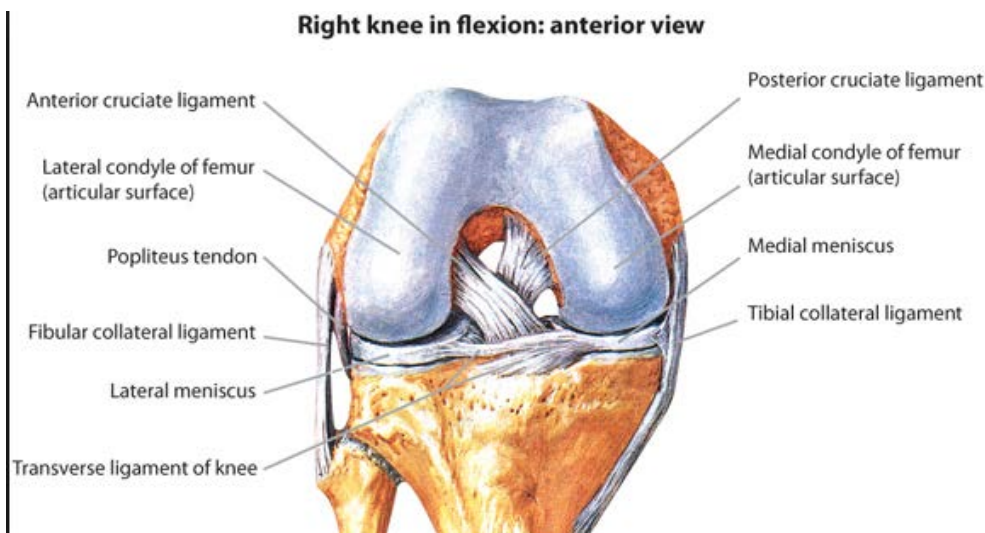


FIGURE. Right Knee Anterior View

http://www.donjoy.eu/en_US/ACL_Knee_Injuries.html

8.4.1 Etiology

The cruciate ligament is commonly injured by either hyperextension or a twist, often in association with the foot being anchored by a studded boot or a ski.

The cruciate ligaments are not capable of spontaneous healing because if torn, the blood supply is lost. In rare circumstances the cruciate ligament may be pulled off with a fragment of bone at one end. If the fragment and associated ligament are put back within a few hours then the whole ligament may survive with its blood supply relatively undamaged.

8.4.2 Clinical presentation

In an acute injury the knee swells quickly, indicating a hemarthrosis brought on by active bleeding from the artery in the cruciate ligament. Sometimes the patient reports feeling a "pop" which is the ligament tearing. The swelling eventually resolves and it is only after a few weeks that the chronic problems that are described below arise.

Loss of a cruciate leads to loss of antero-posterior stability, particularly in flexion, and loss of rotatory stability when twisting and turning. This injury, therefore, is particularly disabling for sportsmen and women. Some patients, however, have no symptoms and there is no explanation for this at the moment. Many patients only experience symptoms when descending stairs or when twisting or turning.

Rotatory instability and pivot shift which follow some cruciate ligament injuries are described in Unit 2a of the Skeletal Anatomy & Physiology module.

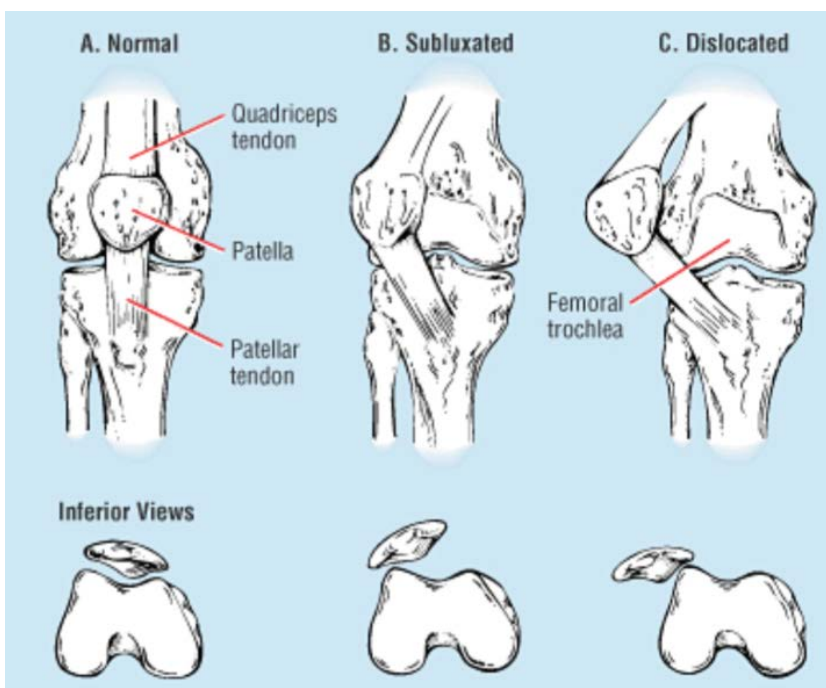
8.4.3 Management

In general the ligament should be left untreated for a while and the knee muscles rehabilitated. Treatment should be offered only if symptoms interfere with daily life or if the patient wishes to return to sport. Treatment consists of replacing the torn ligament with a synthetic one. These replacement ligaments are new and they have an unknown life span. If patients persist in vigorous activity the prosthetic ligament is more likely to fail because, unlike a natural ligament, it has no sensory receptors in it to let the brain know if the ligament is being overstretched. The brain is therefore unable to initiate muscle action to protect the joint.

8.5 Dislocation of the Patella

8.5.1 Etiology

This condition is usually associated with a malformation of either the patella or the lateral femoral condyle. This leads to the patella moving abrasively on the femur (mal-tracking) which is painful because of the associated muscle spasm.



8 . 5 . 2 Clinical presentation

In some people this leads to spontaneous dislocation of the patella and failure of the quadriceps muscle group to act as an extensor, so the person falls to the ground. This can be very dangerous as it happens without warning and predominately dislocate in the lateral direction.

8 . 5 . 3 Management

Minor degrees of mal-tracking are dealt with by surgical splitting of the vastus lateralis muscle insertion into the patella, allowing the patella to fall back into a normal relationship to the femur. If it is recurrent and severe then a medial tightening (plication) of the vastus medialis muscle may be required. In adulthood, the patellar tendon may be re-sited more medially.

This condition should not be confused with anterior knee pain often seen in adolescence, particularly in girls. This condition is poorly understood and is best left alone as most cases settle spontaneously.

SUMMARY

This unit has given you a brief introduction to joint conditions and the role of orthopedic surgery in their treatment. Joint conditions, however, do not always have a surgical solution and the surgery which is carried out does not address the disease but rather the symptoms. There is no cure for arthritis.

In the future, we may look forward to the discovery of the causes of osteoarthritis and rheumatoid disease. The development of joint disease may then be prevented, reducing the need for major surgery. This is at the moment a pipe dream and within this author's working life he can look forward to a busy time adjusting or replacing diseased joints.

In the immediate future we can expect changes in the materials which are used to make joint replacements. This author predicts the end of the use of metal and the widespread use of non-metallic composites by the end of the century. This should lead to less problems of wear and loosening. If artificial joints could be made which lasted the lifetime of the youngest recipient then this would be progress indeed.

GLOSSARY

Orthopedic Joint Conditions

acute

chronic

lymphocyte

arthrotomy

meniscectomy

self-limiting

osteoarthritis

etiology

secondary osteoarthritis

primary osteoarthritis

analgesia

arthrodesis

fusion

osteotomy

arthroplasty

deep vein thrombosis

bacteriaemias

rheumatologist

synovium

synovectomy

exision arthroplasty

diuretics

uric acid

pyrophosphate

gonococcus

anti-staphylococcal

septic aemia

effusion

cleavage lesion

parrot beak

bucket handle

arthroscopy

arthroscopic meniscectomy

osteochondral fragments

hemarthrosis

osteochondritis dissecans

plica

ORTHOPEDIC MEDICINE

UNIT IV

Other Orthopedic Conditions

UNIT 4 – Section Objectives

At the end of this unit you should be able to:

1. Describe the anatomy of the spine.
2. Relate simple anatomy of the spine to common clinical conditions.
3. Discuss the difference between referred and nerve root pain.
4. Describe the cause, features and basic management of disc prolapse and bony root entrapment neuropathy.
5. Describe the simple treatment of spondylosis.
6. Discuss the similarity between neckache and backache syndromes.
7. Describe the causes and simple management of simple walking problems and difficulties in posture.
8. List causes of knee pain in adolescence and discuss the principles of treatment.
9. Discuss the general principles in the management of major disorders to the hip, foot and spine.
10. Discuss the importance of a limp as a symptom of serious disorders in children.
11. Define the term enthesopathy and give two examples in the upper limb.
12. Recognize the signs and management of four common nerve entrapments.
13. Define bursitis and tenosynovitis.
14. Describe common adult foot disorders and how they are managed.
15. Understand the term "painful arc" in the shoulder and describe up to five causes.
16. List common shoulder disorders.

UNIT 4 – Other Orthopedic Conditions

A. LOW BACK AND NECK PAIN

1. INTRODUCTION

2. ANATOMICAL CONSIDERATIONS

3. PAIN IN SPINAL DISORDERS

- 3.1 Local Pain
- 3.2 Referred Pain
- 3.3 Nerve Root Pain

4. CLASSIFICATION OF VERTEBRAL CONDITIONS

- 4.1 Backache and Neckache Related to the Spondylitides
 - 4.1.1 Back sprains
 - 4.1.2 Mechanical backache
 - 4.1.3 Spondylolisthesis
- 4.2 Backache and Neckache Related to the Nervous Tissue
 - 4.2.1 Prolapsed intervertebral disc
 - 4.2.2 Bony root entrapment

5. CERVICAL SPINE

- 5.1 Cervical Spondylosis
- 5.2 Cervical Disc Disease

B. ORTHOPAEDIC CONDITIONS OF

CHILDHOOD

6. INTRODUCTION

7. MINOR PROBLEMS

- 7.1 Walking and Posture Problems
 - 7.1.1 Knock knees
 - 7.1.2 In-toeing
 - 7.1.3 Flat foot
 - 7.1.4 Curly toes
- 7.2 Pain around the Knee

8. MAJOR PROBLEMS

- 8.1 Congenital Dislocation of the Hip (CDH)
- 8.2 Club Foot - talipes equino varus
- 8.3 Neurological Conditions
 - 8.3.1 Spina bifida and meningocele
 - 8.3.2 Cerebral palsy
- 8.4 Scoliosis
- 8.5 Limp in Childhood
 - 8.5.1 Perthe's disease
 - 8.5.2 Slipped Capital Femoral Epiphysis (SCFE)

C. MINOR ADULT DISORDERS

9. INTRODUCTION

10. ENTHESOPATHIES

11. NERVE ENTRAPMENTS

- 11.1 Diagnosis
- 11.2 Management

12. TENOSYNOVITIS

13. BURSITIS

14. ADULT FOOT DISORDERS

- 14.1 Introduction
- 14.2 Flat Feet
- 14.3 Bunions and Corns
- 14.4 Hallux Valgus and Hallux Rigidus
- 14.5 Claw Foot and Hammer Toes
- 14.6 Neuromas
- 14.7 Ingrowing Toe-nails
- 14.8 Plantar Fasciitis
- 14.9 Neuropathic Feet
- 14.10 Achilles Tendinitis and Rupture

15. SHOULDER DISCOMFORT

- 15.1 Introduction
- 15.2 Clinical Presentation
- 15.3 Management
- 15.4 Frozen Shoulder

SUMMARY

GLOSSARY

UNIT 4 – Other Orthopedic Conditions

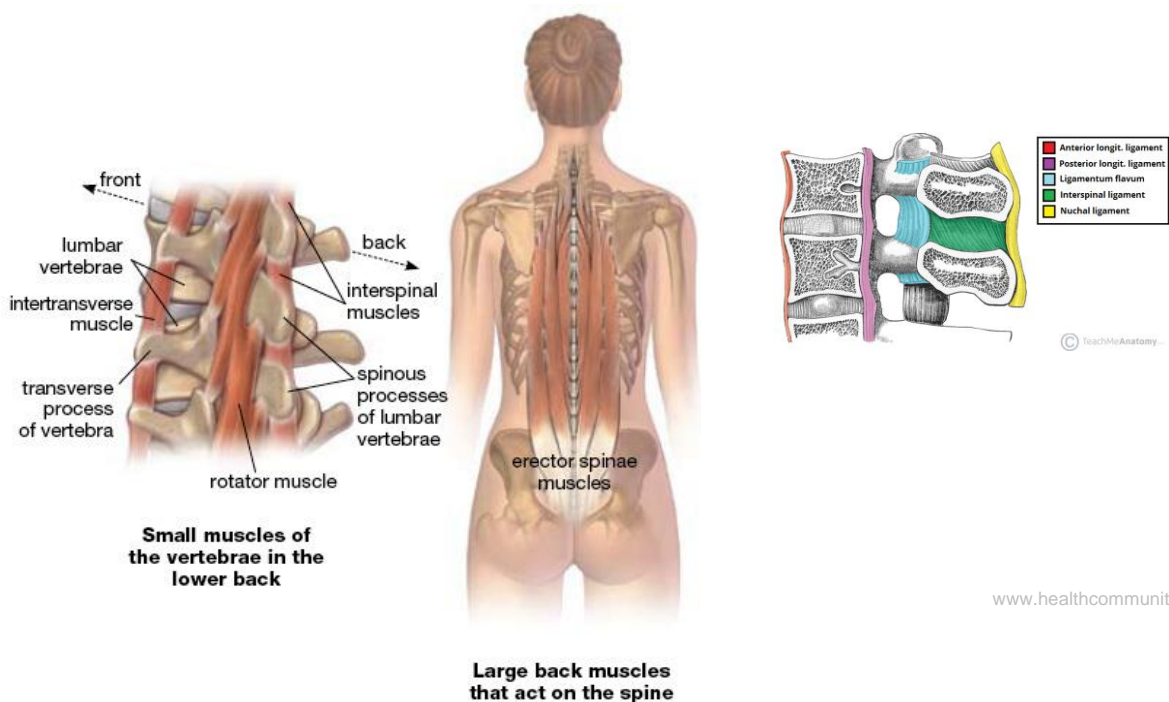
A. LOW BACK AND NECK PAIN

1. INTRODUCTION

It is no exaggeration to suggest that everyone will get backache or neck pain at some time in their life. Although common, most backache is usually self-limiting (i.e. it eventually goes away "by itself") and requires little treatment. Many people have backache caused by minor aches and sprains but a small number of people have serious back problems which may require extensive treatment, including surgery. It is often difficult to distinguish between the minor and the serious problems without extensive investigations.

2. ANATOMICAL CONSIDERATIONS

The anatomy and physiology of the spine was dealt with in detail in Skeletal Anatomy and Physiology Unit 2. The spine consists of bones (the vertebrae), muscles, ligaments and nervous tissue (nerves and spinal cord). The non-nervous tissues together are called the spondylitides and abnormalities occurring in these tissues are rather crudely called spondylitis. Structural abnormalities can occur locally in the spondylitides and sometimes may lead to compression of the spinal cord or, more commonly, the nerve roots. Very rarely abnormalities may occur in the nervous tissue.



www.healthcommunities.com

www.teachmeanatomy.info

3. PAIN IN SPINAL DISORDERS

Pain may occur:

- ◆ locally (at the site of an injury/abnormality)
- ◆ in another part of the body - referred pain
- ◆ along the length of the nerve arising from an affected nerve root

3.1 Local Pain

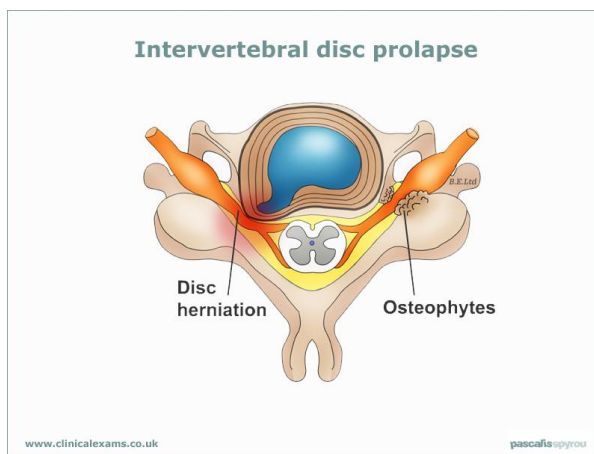
In general, people with backache find it difficult to pin-point the pain in their back. Pain tends to be related to a whole region, such as the lumbar or dorsal regions, and it is relatively unusual for it to be located more specifically.

3.2 Referred Pain

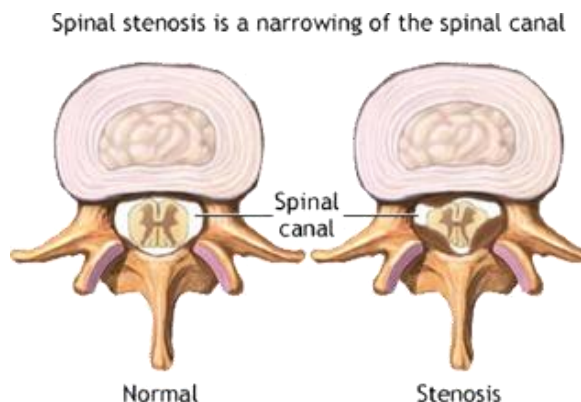
Pain occurring in the back may be "referred" from the back to the buttock, thigh and leg, descending as far as mid-calf, but rarely below this. Pain may also be referred from the neck to the shoulder and upper arm.

3.3 Nerve Root Pain

The nerve roots emerge from the vertebrae through the vertebral foramina, which are surrounded by the facet joints behind and the intervertebral disc in front. Diseases affecting the facet joints and the discs may cause direct pressure on, or inflammatory reactions and swelling of, the nerve roots (Figure 2 shows examples). The brain interprets such disturbances as pain in the spinal nerve originating from that particular nerve root.



www.uchspine.com



<http://www.europeanmedicaltourist.com/herniated-disc>

This commonly happens in the foramina of the lower lumbar region of the spine and so the pain is perceived in the sciatic nerve, hence the term sciatica. Sciatica is characterized by pain in the leg, mainly down the back of the leg but almost always into the foot. It may be exacerbated by coughing. In the cervical region of the spine the mid to lower foramina are commonly affected and so hand and forearm pain, often associated with tingling is characteristic. Nerve root pain may be associated with loss of sensation or muscle weakness. Such features are referred to as "localizing signs".

It is often difficult to distinguish between referred pain and nerve root pain.

4. CLASSIFICATION OF VERTEBRAL CONDITIONS

In such a short unit it is impossible to be comprehensive so I will classify back and neck pain into the following two groups of common conditions:

1. Related to the spondylopathies:
 - (a) Aches and sprains
 - (b) Mechanical back pain
 - (c) Spondylolisthesis
2. Related to the nervous tissue:
 - (a) Disc prolapse
 - (b) Bony root entrapment

4 . 1 Backache and Neckache Related to the Spondylopathies

4 . 1 . 1 Back sprains

Etiology

As mentioned above almost everyone will suffer from an episode of back pain at some time in their lives. Most back pain is associated with awkward twisting, or poor lifting, causing muscle or ligament injuries. Figure below shows a poor and a good lifting posture. Reducing the distance between the back and the weight results in less leverage and reduced spinal loading. These injuries are called sprains and this type of backache can be distinguished from that which has a neurological cause by the absence of signs of nerve compression.



<http://www.nbchiro.com.au/general/how-to-minimise-the-risk-of-low-back-injury>

Management

Such injuries require a brief period of rest followed by a gradual return to normal activities. **AjQti-inflammatory drugs** are said to help relieve symptoms, although simple analgesia is usually sufficient. These conditions are common but a careful investigation should be carried out to exclude the possibility that a more serious condition may exist.

4 . 1 . 2 Mechanical backache

This is an ill-defined condition but really may be considered as recurrent back sprains.

Etiology

The cause of mechanical back problems is unknown although, as the name implies, it is non-neurological.

Possible causes are:

- ◆ spondylosis - degeneration of the intervertebral disc leading to increased loading of the facet joints which then develop secondary osteoarthritis.
- ◆ primary osteoarthritis - the facet joints are likely to be as prone to primary osteoarthritis as any other synovial joint.

However, there are probably many other causes, still to be determined, which involve the ligaments and muscles.

Clinical presentation

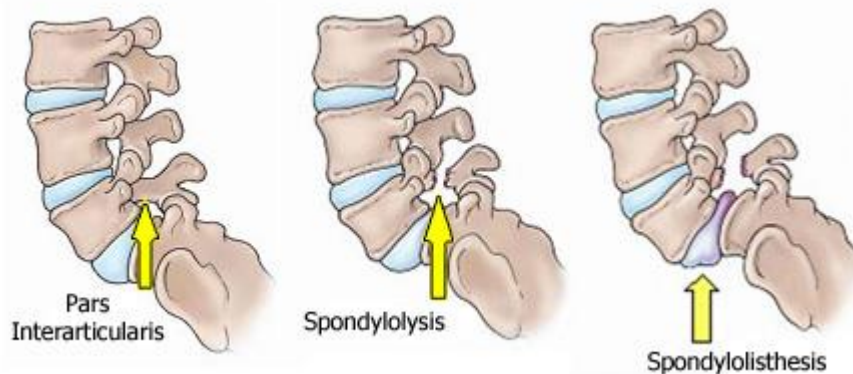
Mechanical back pain tends to recur but this does not necessarily indicate that the condition is deteriorating. There is no known cure for mechanical back pain but the judicious use of rest, physiotherapy and medication will help the sufferer through a bad episode.

Management

Most people must learn to live with their bad back and learn how to try to prevent recurrences. Support should be provided by general practitioners with assistance from physiotherapists and orthopaedic specialists. Alternative medical practitioners such as osteopaths and chiropractors can provide some easing of the condition by manipulation. It is important however that everyone concerned, including the patient, is clear that the cause of most backache is unknown, is mostly not serious, and will get better with time.

4.1.3 Spondylolisthesis

This is a not uncommon finding in association with low back pain. The term refers to the slippage of one vertebra relative to the one below and is commonly seen in the lumbar spine. It is caused by a bony abnormality which interferes with the stability of the facet joints and their associated bony and ligamentous elements.



<http://orthoinfo.aaos.org/topic.cfm?topic=a00053>

Etiology

The condition may be congenital or it may be acquired, so it may occur at any age including infancy. There is no need to know the detail of congenital conditions at this stage.

Adult forms of this condition are thought to be acquired, although some may be mild congenital abnormalities which have gone unnoticed previously. It appears to be acquired following an acute or, more likely, a fatigue fracture of the pars interarticularis.

Clinical presentation

Someone with this condition experiences low back pain which is almost identical to mechanical back pain. Diagnosis is nearly always made using X-ray techniques, although in severe slippage a step may be felt at the affected area. The condition very rarely causes neurological problems, even when the slippage is major. In the case of congenital spondylolisthesis, which is rare, the movement between the two vertebrae may be sufficient to damage nerve tissues.

Management

A spinal corset may help to relieve pain, otherwise management strategies are similar to those for the mechanical back pain sufferer. Most sufferers do not require surgery unless they are experiencing severe pain, when surgical fusion of the two affected vertebrae may be required. A pars interarticularis defect such as a fracture, as described above, may be seen on a radiograph without a forward slipping of the vertebra. This is known as spondylolysis and this defect can exist without causing pain. If pain is experienced, conservative measures are usually successful, but if the pain is severe, spinal fusion may be required.

4 . 2 Backache and Neckache Related to the Nervous Tissues

It is essential from the outset to allay the commonly held view in the general population that most back and leg ache is caused by a "slipped disc". The intervertebral disc does not "slip", the disc contents prolapse, and in fact this is a relatively rare condition.

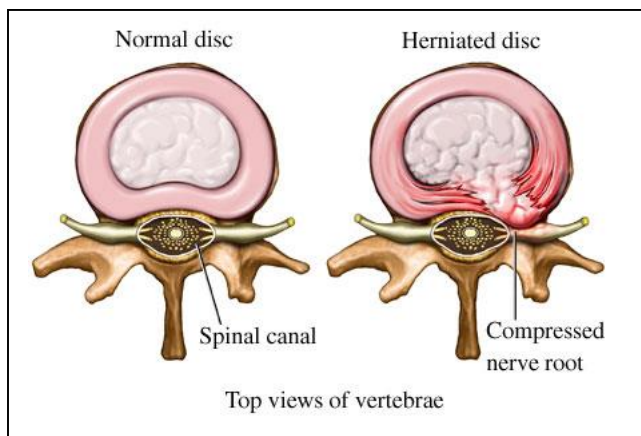
4 . 2 . 1 Prolapsed intervertebral disc

Disc prolapse was first described in the late nineteen forties but first became a popular diagnosis in the early sixties. It is true to say that since then the diagnosis has become somewhat overused. Disc prolapse may occur in the lumbar or cervical spine but the description below relates to the lumbar spine.

Clinical presentation

The classical symptoms occur in people under forty, more commonly in men. They are acute backache and legache, or sometimes legache alone with backache developing later. Sufferers may describe a single event of lifting or strain, but there is not necessarily a correlation between this and the condition; it may arise spontaneously.

The characteristic symptom is of legache passing down the back of the thigh and leg to the foot. This is in contrast to referred backache which usually goes no further than the knee or upper calf.



http://physioworks.com.au/injuries-conditions-1/bulging_disc

Etiology

The cause is an abnormality in the intervertebral disc which leads to prolapse (extrusion) of the nucleus pulposus material through the annulus fibrosus. If it extrudes backwards and laterally it

usually impinges on the nerve root. If it extrudes posteriorly it may press on the spinal cord or, more commonly, on the cauda equina. The discs between the sacrum and the fifth lumbar vertebra are most commonly affected and the condition occurs with decreasing frequency further up the lumbar spine. This explains why prolapsed discs are often called "sciatica". Nerve roots emerging beneath the fourth and fifth lumbar, and the first sacral vertebrae are commonly compressed by discs. The brain interprets pressure on a nerve root as occurring in the peripheral nerve arising from it. The peripheral nerve arising from the nerve root mentioned above, is the sciatic nerve - hence the term sciatica.

Occasionally the peripheral nerve to a specific muscle or group of muscles, or to a specific area of skin is affected. This may cause weakness in the muscle or numbness. When the pattern of symptoms is so specific, clinicians talk of the clinical examination revealing localizing signs.

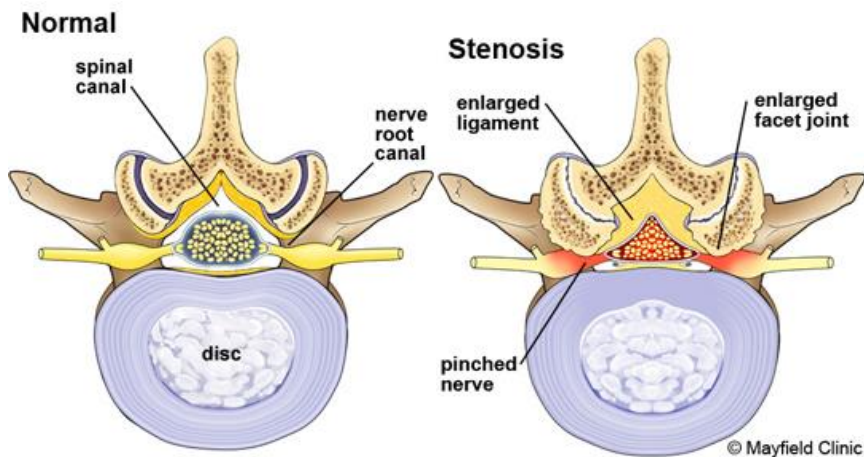
Management

It is essential to make sure that nerves supplying the bladder and bowel are not damaged. The patient may be treated by a combination of rest and gentle, progressive mobilisation. Analgesics and anti-inflammatory drugs may help to relieve symptoms. Bedrest should be for a short period and traction only used to enforce rest - it will not materially alter the condition.

Most disc prolapses recover spontaneously as the disc material is absorbed by cells released from the bloodstream. If pain persists or localizing signs get more severe then surgical intervention to remove the disc material is required. Before undertaking such an operation, the site of the disc prolapse is confirmed by injecting a radio-opaque material into the spinal fluid (the fluid which surrounds the spinal cord and nerve roots) then taking an X-ray. The radiopaque fluid will not be able to flow where the prolapsed disc presses on the nerve. Such a technique is called myelography and the "picture" which results from it is called a myelogram.

4.2.2 Bony root entrapment

In contrast to disc prolapse this condition has been ignored until fairly recently. It has come to significance through the improved imaging techniques described above.



Clinical presentation

The sufferer is typically a person of either sex usually over forty who has a previous history of backache of a mechanical type. These patients are usually known back sufferers who develop new symptoms of leg pain radiating to the foot, usually made worse by exercise. Such a syndrome is rather poorly named spinal claudication, (spinal cramp) as it is similar in effect to a vascular disease which does cause cramps in the calves during exercise.

Episodes are usually acute and recurrent against a chronic history of back pain. The episodes may remain mild or may progress to affect the patient's lifestyle. Physiotherapy is unlikely to help and should pain be severe then surgery may be necessary.

Etiology

The cause of the condition is commonly due to bony overgrowth around the vertebral foramina where the nerve roots emerge. The cause of the bony overgrowth would appear to be secondary to degenerative changes in the adjacent facet joints. These may degenerate from primary osteoarthritis or as a result of disc degeneration (not prolapse!).

Management

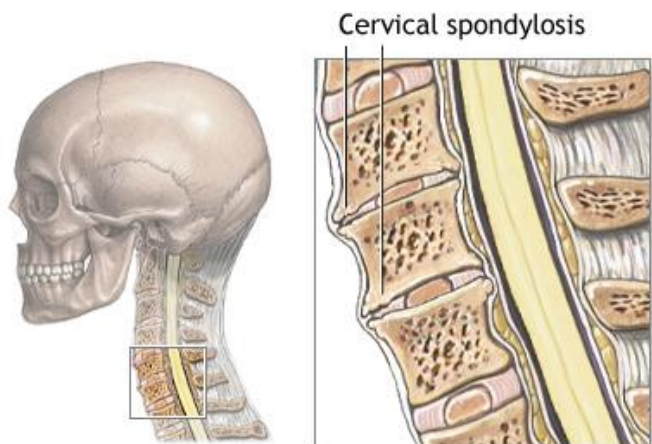
Removal of the disc in such patients may make the condition worse and removal of bone is needed to free trapped nerve roots. This may result in disturbance in spinal stability and lead to a need for fusion of the affected vertebrae. The decision to operate is entirely determined by the severity of the patient's symptoms.

5. CERVICAL SPINE

The cervical spine is a very mobile part of the vertebral column and it is no surprise to find that it is prone to disease and injury. Most conditions are exactly analogous to those found in the lumbar spine.

5.1 Cervical Spondylosis

This is very like the degenerative disc and joint disease seen in the lumbar spine and the etiology.



ADAM.

Clinical presentation

The condition occurs typically in people who are over forty and is more frequent in females than males. They have with dull neck ache which is often referred to the shoulders and upper arms. They also may experience tingling in the arms which is often assumed to be an entrapment of nerve roots, but this is not always confirmed on investigation. The spondylitic process can however be progressive and bony root entrapment may occur, with localizing neurological signs.

Management

If there are no localizing neurological signs, treatment consists of analgesics, **non steroidal** anti-inflammatory (**NSAI**) agents, the use of a soft collar, and physiotherapy to relieve muscle spasm. Patients need counselling and a good explanation of the condition. They need to be warned that it is usual, as in the lumbar spine, for recurrent attacks to occur.

If nerve root entrapment is confirmed, surgical fusion of the vertebrae and decompression of the nerve root may be necessary.

5 . 2 Cervical Disc Disease

Clinical presentation

Although not as frequent, cervical disc disease has a similar pattern to that found in the discs of the lumbar spine. The lower cervical discs are most likely to cause the problem. Symptoms of pain and referred pain are similar to those caused by spondylosis. Differentiating between the conditions can be difficult, although sufferers from disc disease tend to have no previous history of neck trouble. Also, following disc prolapse, the neck muscles may be in spasm and the movement of the neck is severely restricted.

Management

Most people recover with resting, gentle traction and wearing a supporting collar. If localizing signs are marked, or symptoms do not regress, then surgery and fusion of the affected vertebrae may be necessary.

B. ORTHOPAEDIC CONDITIONS OF CHILDHOOD

6. INTRODUCTION

Some childhood conditions of the musculoskeletal system are common and are not serious. Other conditions, which fortunately are rare, are serious and have very major consequences for the child and the family.

7. MINOR PROBLEMS

7.1 Walking and Posture Problems

Children are often sent to an orthopaedic clinic because of parental anxiety about how, or when, children walk and stand. During normal development we expect children to reach a certain milestone at a certain age. The average child normally sits independently by the age of nine months, stands by a year and walks by twenty months. However, there is a lot of variation in normal development, and parents should be reassured that if their child does not reach a certain milestone by a certain age, this is not a sinister sign. Very occasionally failure to achieve milestones will portend a serious problem but these are rare cases.

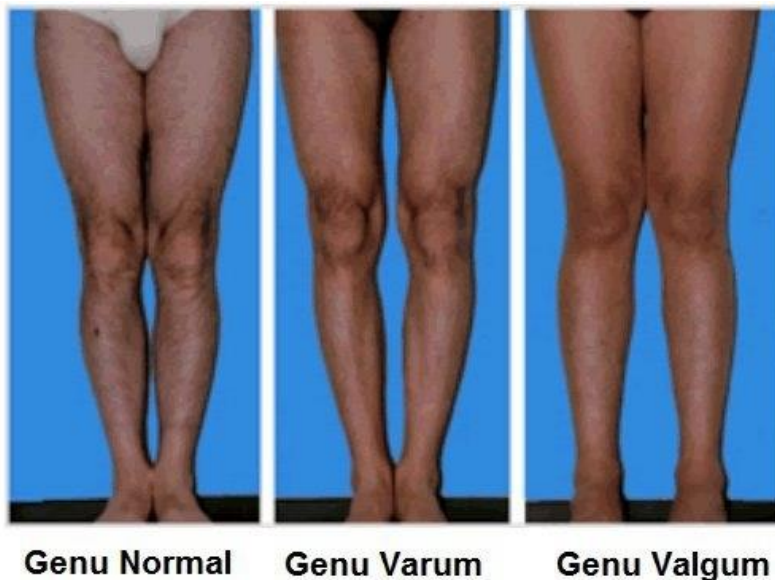When children start to walk their gait takes many months to mature and so minor variations are to be expected.

Common, but minor, abnormalities include:

- ◆ Knock knees and bow legs
- ◆ In-toeing
- ◆ Flat feet
- ◆ Curly toes

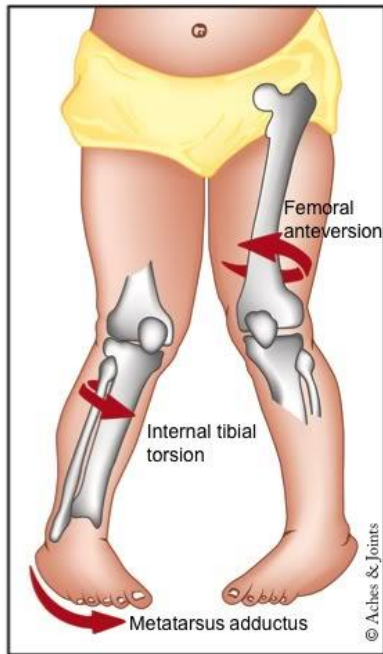
7.1.1 Knock knees

Knock knees or **genu valgum** and **bow legs** or **genu varum** are frequently seen. These conditions are rarely, if ever, serious. The normal alignment of the knee is in valgus and when a child stands to attention there is normally a gap of 4cm or so between the feet. If this gap is diminished the knees are in varus, and if it is increased they are in valgus. By the age of seven, nearly all children with these conditions will have developed a normal knee alignment.



7.1.2 In-toeing

In-toeing is a frequent cause of parental anxiety. In this condition, children stand with their feet pointing inwards ("pigeon-toed"), and this is often exaggerated when they run. Children are often referred to the orthopaedic specialist because of clumsiness, but a careful enquiry may suggest that they are no more prone to falling than other children. Parents also often complain bitterly because shoes tend to wear down at the heels.



<http://www.massgeneral.org/ortho/services/pediatrics/intoeing.aspx>

The causes of in-toeing are:

- ◆ **Femoral neck angle variation.** During the later stages of the normal development of the fetus, the leg rotates on the pelvis so that the acetabulum points almost backwards and the femoral head on the neck is orientated forwards. Sometimes this rotatory process is not completed by birth and so the femoral neck is more anteriorly orientated (i.e. it is **anteverted**) than normal. This means that children born like this can internally rotate their femur a lot and externally rotate it only a little. This is reflected in their posture and they have an in-toed gait. This delayed development will correct by itself by the age of ten, although some are left with a little residual deformity. This is seldom, if ever, severe enough to warrant surgery.
- ◆ **Tibial torsion** or twisting (where the bone is literally distorted or warped along its vertical axis) is a normal variation and should be ignored.
- ◆ **Abnormal forefeet**, particularly the hooked (adducted) forefoot are commonly seen. It is dubious whether surgery to correct this is ever justified, and it certainly should not be considered before the age of seven. The vast majority correct spontaneously by men and any residual hooking rarely causes functional difficulties. There is no evidence that special shoes make any difference.

7.1.3 Flat foot

Flat feet are abnormal only in the minds of the public of the western world - a flat foot is a normal variation which very rarely causes functional abnormalities apart from uneven shoe wear. In some human races, a flat foot is the norm.

There are two kinds of flat foot - rigid and mobile. The vast majority are mobile and entirely innocuous. All children's feet are flat at birth and the normal arch of the foot may not form until the child is seven. Parents must be reassured about this, and all pressure to intervene should be resisted. Referral to hospital for mobile flat foot is not really required.

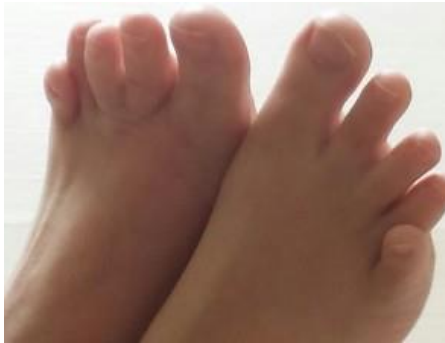A rigid flat foot is rare at any age and usually implies an underlying bony abnormality of the foot. Occasionally it is a sign of a serious disease such as rheumatoid arthritis.

7.1.4 Curly toes

Minor overlapping, or crossing of the toes, particularly of the fifth toe are common. Most correct spontaneously and should be left alone. Occasionally the crossed fifth toe causes discomfort in shoes. *If fixed it requires surgical correction. Surgery on other curly toes should be discouraged despite often heavy parental pressure.



<http://pafootdoctors.com/crossover-toe/>



<http://quietfurybooks.com/blog/category/general-nonsense/>



<http://pafootdoctors.com/crossover-toe/>

7.2 Pain Around the Knee

A very common cause of the referral of children is pain around the knee. This is seen in both sexes from about ten to twelve years of age, and is more common in girls as they develop secondary sexual characteristics.

Osgood Schlatter's disease

Osgood Schlatter's disease is an inflammation of the attachment of the patellar tendon to the growing tibial epiphysis, caused by excess traction by the quadriceps. The cause is unknown but it may be an overuse injury as it is commoner in very active children who are often involved in organized sport.

The condition causes tenderness and discomfort, which are worse after exercise. There may also be swelling. The condition is episodic and usually can be treated by rest. Only rarely is it necessary to enforce rest with a plaster. The child will cease to have symptoms in middle adolescence when the epiphysis fuses.

Adolescent knee pain

Adolescent knee pain occurs most commonly in girls and is of unknown cause. It is not the same as dislocation of the patella. Rarely, on arthroscopy, an area of patella cartilage is seen to be eroded - chondromalacia patellae. Most, but not all girls grow out of the condition and a watching brief should be kept. If symptoms persist, an arthroscopy may be necessary, but speculative surgery is to be avoided.

8. MAJOR PROBLEMS

8.1 Congenital Dislocation of the Hip (CDH)

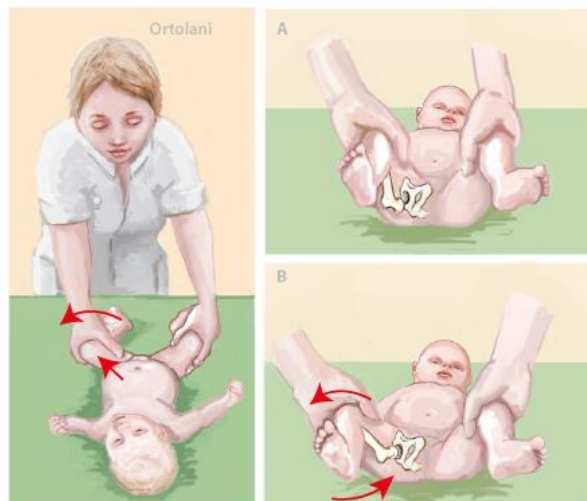
Introduction

CDH occurs in one or two live births per thousand. It is a badly named condition because the hip is rarely completely dislocated at birth, but it is abnormal and is likely to become irretrievably dislocated if ignored. A better name would be congenital hip dysplasia, reflecting the underlying abnormality of the femoral head, the acetabulum, or both. The condition is more frequent in girls than boys and there is a familial and racial tendency. In a significant number of children the condition is bilateral (both hips).

Clinical presentation

All children should be screened at birth and checked again at three, six and twelve months. At birth it is diagnosed using a technique in which the examiner either tries to dislocate the hip or tries to relocate it if it is dislocated. This test may produce a slight click, which is a suspicious sign, or a definite clunk as the hip dislocates or relocates.

Occasionally the test will fail to find an abnormality and the condition goes undetected at birth. It becomes apparent later, either before weight bearing (sitting), or after weight bearing (standing) or even walking has been established. Clinical signs include shortening of the limb, asymmetrical skin creases, limited abduction and a limp.



Management

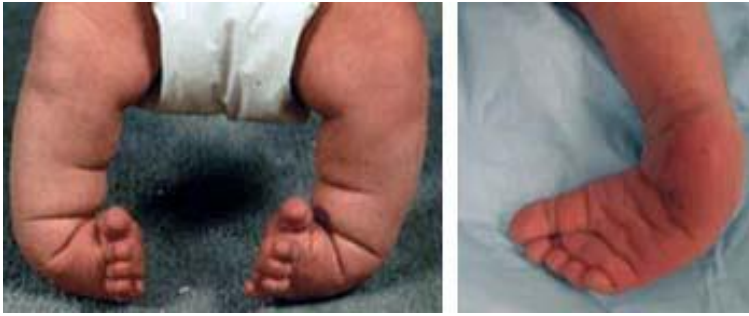All children - in whom the test produced a "click" should be re-examined in a specialist clinic at three months old when a radiograph is usually justified. All "clunks" should be treated from birth. If the femoral head is relocated and maintained in the acetabulum using splintage then the vast majority will settle and give no further trouble as the hip starts to develop normally.

If discovered late, but before weight bearing, the condition may be treated by a period of gentle traction followed by open or closed manipulation. It is then splinted in plaster for three months. If discovered late and walking has commenced, major surgery is required to deepen the undeveloped acetabulum and re-angle the femoral neck to stabilize the hip. The results of this are at best moderate, and secondary arthritis is highly likely. This is why early diagnosis is so important.

8 . 2 Club Foot - talipes equino varus

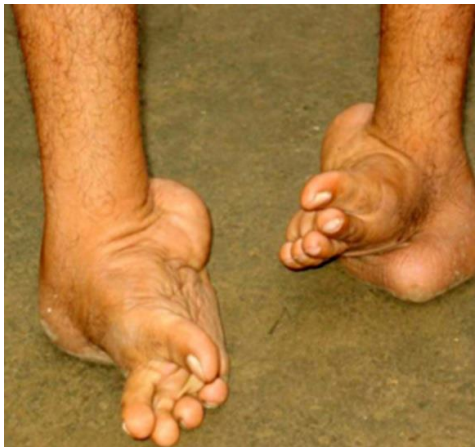Introduction

This is a deformity of the foot which makes it look like a golf club. If treated early, mild cases can be fully corrected and major cases can be much improved to give a functional foot.



<http://orthoinfo.aaos.org/topic.cfm?topic=a00255>

FIGURE. CLUB FOOT -TALIPES EQUINO VARUS



Etiology

The condition is relatively common and is seen in a mild, postural form and a fixed form. The mild form is seen after a breech birth and is probably related to the baby's position (posture) while in the womb. The fixed form is associated with developmental abnormalities of nerves and muscles of the leg. In both cases the condition can be bilateral.

Management

The mild form is usually easily corrected at birth by manipulation. The severer forms require surgery.

In both forms the initial treatment consists of gentle stretching in two phases. The first phase corrects the hindfoot equinus and the second phase corrects the mid and forefoot varus. In the mild cases, six weeks of stretching and strapping in a corrected or over-corrected position is all that is required. In severe cases, after six weeks of stretching the deformity should be reassessed and if correction is incomplete or cannot be maintained, then surgery is necessary.

The children all need to be followed up until their feet stop growing, at around the age of fourteen, as late relapse requiring further surgery is not uncommon. The affected foot is often significantly smaller than the normal foot which can give difficulties in shoe fitting.

8 . 3 Neurological Conditions

Conditions affecting the neurological structures at birth lead to abnormalities of the muscular and skeletal system during growth and development.

8 . 3 . 1 Spina bifida and meningomyelocele

Abnormal developments of the spine during the first three months of the development of a newly forming baby may result in the abnormal formation of the spinal cord and vertebrae.

Spina bifida occulta

This may be a minor bony abnormality which affects 2% of the population. It is usually of no significance, although some people who are affected develop mechanical backache and a very small number may get tethering of the spinal cord to the higher lumbar vertebrae during growth -**diastatomy elia**.

Spina bifida cystica

A small and decreasing number of babies are born with the neural plate tissues open with little or no skin or bony cover. This is spina bifida cystica. The nerve tissue may be covered by a cyst (a meningocele) or the nerve tissue may be incorporated in the cyst wall (a meningomyelocele). Many children also have an abnormal increase in the amount of fluid in the brain, hydrocephalus, which leads to mental retardation and an increase in the size of the head.

Many children suffering from this condition die at, or soon after, birth. Some survive and undergo surgery to close the lesion on their back. These children have formidable problems: paralysis; growth deformities through muscle imbalance; and incontinence. Many, but by no means all are mentally retarded. All this is a major burden for the child and the family, who need support from a team consisting of surgeons, therapists and social workers.

Many of the children need early surgery to their feet to maintain a functional shape. Others develop joint contraction resulting in a fixed flexed position of their knees and dislocation of their hips. Every effort should be made to keep the children mobile until adolescence so that they may grow to

a reasonable size. Many children manage to walk aided by splints and hand-held aids until then. As they reach adolescence many go into a wheelchair as they find this easier for themselves socially. The care of such children and adults is the responsibility of a team of specialists in which the doctor's contribution is minor. The care team must support the family as a whole.

8 . 3 . 2 Cerebral palsy

Cerebral palsy is a condition caused by an abnormality of the brain. This is often caused by damage to the brain at birth and results in delayed, or arrested development of the nervous and musculoskeletal systems. The spinal tissue develops normally and such children have uninhibited spinal reflexes but lack the co-ordination and purpose of movement normally controlled by the brain. This results in a spastic type of paralysis. Some muscles contract strongly in an uncoordinated way (spastic) whilst others are very weak and flaccid. This imbalance leads to abnormal muscle and bone growth, with secondary deformities of joints.

Some patterns of this condition are common. When one arm and the leg on the same side are affected this is called hemiparesis. Two legs are often affected (paraparesis), and sometimes all limbs are affected (quadraparesis). Most, but not all, spastic children are mentally retarded and some are blind and/or deaf. Occasionally affected children do not suffer mental and sensory impairment and tragically this may go unrecognised, to the utter frustration of the individual.

It is important to recognize that some people have very minor degrees of spasticity which may only affect one muscle group. A common sign is toe-walking in adolescence. Examination reveals a calf muscle spasticity and some sufferers may need tendo-achilles lengthening before growth ceases.

Orthopaedic problems for children with this condition during growth and development are similar to those with spina bifida but often much more severe. Deformities can be minimized by careful physiotherapy. Splintage should only be used with caution as overzealous splintage can lead to increased muscle spasm and, ultimately, deformity. Careful use of surgery, to either lengthen tight muscles or to denervate them or (occasionally) to move them, may maintain acceptable posture and help maintain some function.

Again there is a need to recognize the need to be part of a much wider supportive team who will provide regular day to day contact.

8 . 4 Scoliosis

Curvature of the spine with a rotatory abnormality of the vertebrae is known as scoliosis. It is a three dimensional deformity based on an abnormal lordosis of the spine which leads to buckling and twisting of the vertebral column as a result of the action of muscles and gravity.

Etiology

It may be caused by congenital abnormalities of the vertebrae or by neuromuscular imbalance but most cases have no known causes (i.e. they are idiopathic).

Most cases of idiopathic scoliosis occur in adolescence although it may occur in infants and, rarely, in adults. It is far commoner in girls than boys. Its principal effects are cosmetic (poor appearance due to spinal contracture), but this must not be underrated as a cause of distress. It rarely causes physiological disturbances.

Clinical presentation

The child usually complains of the twisting of the ribs which causes a hump on one side of the shoulder. Girls may also complain that their skirts hang crookedly. It may be painful although this is usually secondary to the anxiety and distress caused by what is commonly known as a sinister condition.

Management

Not all curves progress (get worse) and this should be emphasised to parents. If the curve is progressive, or is causing distress, treatment should be offered early. Braces have no benefit and should not be used as they add to the stigma of the disease.

If treatment is demanded due to the progress of the curve or the distress caused by it, then surgical correction is essential. The rotatory element of the deformity must be corrected, to remove the hump as this is the cause of most distress to the patient. This is very complex surgery which is only carried out in a handful of regional spinal centres. All children with scoliosis should be referred for a specialist opinion if treatment is demanded or if the curve is progressive. The earlier the referral the better.

8.5 Limp in Childhood

Introduction

A limp at any age must be taken seriously. Quite often the cause will be obscure and the condition settle. However, when there is a serious cause it demands treatment and so the conditions below, which occur within characteristic age bands, must be excluded.

From birth - CDH

- Infection of the hip

Between four and ten - Perthe's Disease

From ten to fifteen - Slipped upper femoral epiphysis

8.5.1 Perthe's disease

This is an osteochondritis (fragmentation of the bone and overlying cartilage) of the femoral head epiphysis. It is commoner in boys than girls and in 20% is bilateral. The cause is unknown but it has an incidence of up to 5 per thousand children.

Clinical presentation

The natural history is for the child to present with a painful limp which is followed by a slow recovery. Radiologically the femoral head may be normal on first presentation but it fragments to a greater or lesser degree. Radiographs repeated after a month may show previously unrecorded changes. Ultrasound reveals excess fluid in the hip joint.

The condition is thought to be an avascular necrosis of the growing femoral head. The cause, nevertheless, is obscure. Eventually the head will re-vascularize and re-ossify but it may be enlarged and deformed.

Management

The strategy of treatment is to maintain the head concentrically within the acetabulum until the natural process of the disease runs its course. Minor degrees of the condition, involving up to half of the femoral head, need no treatment as the prognosis in such children is good. In older children, when the condition affects the femoral head, the prognosis is less good. The child will return to normal in the short term, but will be prone to secondary osteoarthritis in early middle age.

In the severe case, splintage to achieve containment may help. There is a belief that osteotomy, to either enlarge the acetabulum, or redirect the femoral head, helps. All these treatments are of dubious value. Careful follow up with periods of traction to alleviate symptoms of pain and limp is probably all that can be done to help these children.

8.5.2 Slipped Capital Femoral Epiphysis (SCFE)

This is a condition seen in boys of around twelve years old who are sexually immature for their age and in girls who are a little older and have recently undergone an adolescent growth spurt. It consists of a slippage of the epiphysis of the femoral head on the femoral neck so that the head is abnormally tilted.

Clinical presentation

In this condition the child has a limp which may not be particularly uncomfortable, but there may be pain radiating to the knee (following the sensory distribution of the obturator nerve). Any child with knee pain must have their hip examined. The slip may occur acutely or it may be preceded by many months of discomfort without clinical or radiological signs. All young adolescents with a painful hip must be regarded as having this condition until it is clinically and radiologically excluded. Radiographs must include a lateral view or minor degrees of slippage may be missed.

Management

Treatment is surgical. If the slippage is minor, the hip should be pinned in its new deformed position. If the slippage is major, a gentle attempt to replace the head on the neck by manipulation may be attempted although the risk of avascular necrosis is high. The other hip should be observed, using radiography at regular intervals, and pinned if any suspicion of slippage arises. The pins are best removed after fusion of the epiphysis at around eighteen years of age.

C. MINOR ADULT DISORDERS

9. INTRODUCTION

In many ways the term "minor" does some injustice to the conditions discussed below. It is important to appreciate that, although these conditions are common, they are often of sufficient severity to cause considerable inconvenience and discomfort to the sufferer and they may have important social and economic consequences. They are "minor" in the sense that many are self limiting in their natural history, and many have non-surgical solutions. They all need great care in assessment and in management as it is possible to worsen the condition by casual or inaccurate management.

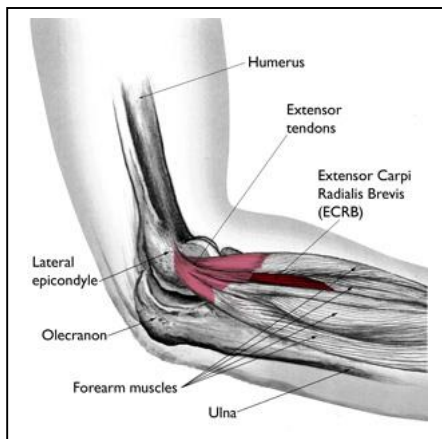
10. ENTHESOPATHIES

The enthesis is the term given to the short fibrous origin of a muscle and so an "enthesopathy" refers to an inflammation of a muscle origin.

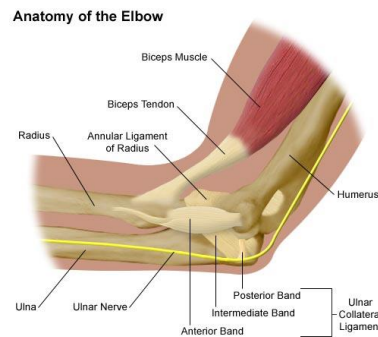
Common sites of enthesopathies include:

- ◆ The common origin of the flexor muscles of the forearm - Golfer's elbow
- ◆ The common origin of the extensor muscles of the forearm - Tennis elbow

A person suffering from tennis or golfer's elbow complains of quite severe discomfort on using the affected muscle.



Lateral epicondyle: <http://orthoinfo.aaos.org/topic.cfm?topic=a00068>



Medial epicondyle: <http://www.nationalsportsmed.com/images/m1/elbow.jpg>

It is possible that many entheses may be inflamed at one time giving rise to many aches and pains. These general conditions are encountered principally by the rheumatologist and the causes remain obscure. The common enthesopathies around the elbow may arise spontaneously although they are commonly associated with repetitive movements or overuse. The prognosis is generally favorable, especially if there is a clear cause, and rest will result in a spontaneous recovery.

Occasionally the condition may become chronic, or be severe enough to warrant intervention. Recovery may be speeded up with a course of anti-inflammatory agents. Local steroid injections into the point of maximum tenderness also can be of value. Care must be taken to ensure that the steroid is injected into the enthesis with no leakage into the subcutaneous fat or skin, as this results in the pain being exacerbated and the patient is left with an unsightly dimple.

A very small number of patients require surgery. This consists of scraping the origin of the muscle from the bone and permitting it to slide distally thus "decompressing" the area. If possible patients should be encouraged to wait as, in the long term, spontaneous recovery is highly likely.

11. NERVE ENTRAPMENTS

All nerves are sensitive to compression and stretching. Such an injury is known as a "neuropraxia". Continued pressure will lead to atrophy of the nerve which, at best, takes a very long time to recover and usually is permanent (at least in part). Therefore early diagnosis and management is likely to give the best results.

Nerve entrapments may be extrinsic to the body or intrinsic. Extrinsic causes include accidents where consciousness is lost and the victim inadvertently presses on a nerve. Patients in bed or in plaster casts are at risk from pressure on nerves in exposed sites. The most common site at risk is the common peroneal nerve as it winds around the head of the fibula. Most cases are intrinsic, caused by structural local anatomical variations or inflammatory swelling. Common sites are: the median nerve at the wrist, the ulnar nerve at the elbow, the ulnar nerve at the wrist and the posterior tibial nerve at the ankle

11.1 Diagnosis

Any numbness or tingling in the area supplied by the nerve should be taken seriously. Weakness and real sensory loss are diagnostic. If in doubt nerve conduction studies should be performed.

11.2 Management

Obvious causes such as bandage or cast must be removed. If symptoms persist then surgical relief of pressure may be required. This involves cutting the skin and fascia.

12. TENOSYNOVITIS

Inflammation of tendons and their associated synovial sheaths is a common problem. It is often associated with rheumatoid arthritis where it is part of a multi-system disease. In other situations it may arise spontaneously, often with no known cause but usually it is precipitated by unusual levels of activity, or overuse. It is an important condition to be aware of as it is often associated with worker compensation and litigation

13. BURSITIS

Bursae are common structures around joints. A bursa is a small sac of fibrous tissue lined with synovial membrane and filled with fluid. It acts as a natural form of "bearing" aimed at improving muscle and joint function by reducing friction, usually where tendons and ligaments pass over bones. However, they may also form in response to pressure. Bursae are prone to disorders resulting from repetitive movement or strain, or from being subject to abnormal loads. Bursae around the shoulder are commonly affected and these are dealt with in a separate section on shoulder discomfort. Commonest sites of bursitis are around the knee and the elbow, and the greater trochanter at the hip may also be affected.

Those affected generally complain of chronic discomfort over the bursa, usually associated with the causative element, such as movement or pressure. There may be swelling of the bursa, such as is seen in housemaid's knee when the pre-patellar bursa swells.

Occasionally there may be an infection of the bursa. This results in a tense swelling associated with infection of the skin (cellulitis) and general ill health (malaise).

Chronic bursae with no symptoms are benign and need no treatment unless the patient demands it either for convenience or appearance. For instance, the swellings may interfere with dressing. If tender they may be excised, although the patient should be encouraged to remove the underlying cause (for example by using a kneeling mat).

Infected bursae should be incised and drained as this often leads to a spontaneous recovery through scarring and fibrosis.

14. ADULT FOOT DISORDERS

14.1 Introduction

Abnormalities of the feet are relatively common in the western world and this must relate in many ways to our shodden state. Also, our perceptions of abnormality are very varied, as varied in fact as our feet. The only foot abnormalities that matter are those which cause symptoms - usually of pain. Treatment or surgery is seldom, if ever, justified in the absence of functional abnormality and disaster will likely follow if operations are carried out in order that people might wear their preferred footwear. Foot shaped shoes are the order of the day - not shoe shaped feet.

14.2 Flat Feet

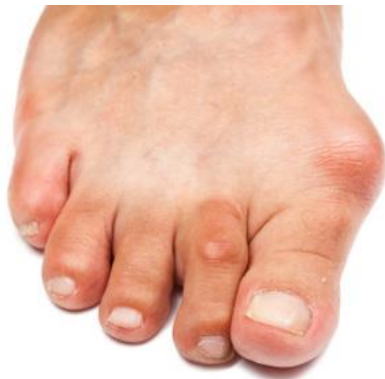The painful flat foot is a rare entity. Symptom free flat feet are a normal variation and are very common in certain races.

Rarely, a very painful spasmodic flat foot may be associated with infection or chronic inflammatory disease. Occasionally it occurs acutely in middle age and examination reveals a painful and tender swelling over the insertion of tibialis posterior. This may indicate acute or impending degenerative rupture and warrants early intervention.

Mostly the condition is benign and if pain-free should be ignored. If associated with pain, a medial heel lift will correct the deformity of the hind part of the foot and stabilize the medial arch. If pain is a persistent problem, fusion of the subtalar joint will help, although this is not something to be undertaken lightly as it disturbs foot and ankle function profoundly.

14.3 Bunions and Corns

Bunions are fluid filled bursae which are found around bony prominences, commonly over the distal part of the first metatarsal and occasionally over the fifth. They form as a natural response to pressure and indicate an underlying abnormality which should be treated rather than the bunion. Occasionally they become infected and need drainage, followed a few weeks later by treatment of the cause or a review of the footwear. Corns are another way in which the body reacts to areas of high pressure. The painful excessive corny skin may be superficially removed but in the long term it will recur unless the underlying cause of the high pressure is removed.



14 . 4 Hallux Valgus and Hallux Rigidus

The hallux refers to the big toe and really these conditions are disorders of the first metatarsophalangeal joint. Hallux valgus refers to the turning away of the phalanges of the big toe from the mid-line, usually because of a deformity at the joint line. Hallux rigidus refers to osteoarthritis of the metatarsophalangeal joint. The two conditions can occur separately or together. Treatment depends upon whether one or both conditions are present, and the age of the patient.

Hallux rigidus alone - can occur in adolescents and adults.

In adolescents it is said to be as a result of osteochondral fracture, although this is not always easy to prove. Conservative treatment includes the use of a metatarsal bar to provide a rocker at the front of the foot so that the toe need not bend in normal walking. This usually fails because youngsters do not accept the cosmetic consequences on their shoes and so the same surgical treatment given to adults is required.

In adults the condition may present at any age, although in the elderly it rarely occurs without hallux valgus. Conservative measures are rarely sufficient and surgery is required.

Surgical removal of the osteophytes with an osteotomy of the proximal phalanx is often sufficient for minor cases. Surgical fusion in a neutral position is most reliable and despite the folklore this rarely gives women problems with shoe heel height. Interposition arthroplasty with a silicone plastic (silastic) spacer is an alternative which gives mixed results.

Hallux valgus alone - may occur at any age.

This gives more problems in women than men although there is no evidence that shoes cause the condition. Many, but not all, sufferers have a short first metatarsal, often in varus. The cause of this common and troublesome condition is unknown.

Management depends on age. Realignment of the first metatarsal to a more lateral position and excision of any bony prominence (an exostosis) over the first metatarsal head gives satisfactory results at almost any age. Excision of the metatarsophalangeal joint - the Keller's procedure is to be avoided in the young and is probably unnecessary if the joint is not painful.

Hallux valgus with rigidus - is seen in older people where joint degeneration is usually secondary to the valgus deformity.

These older patients may well be satisfied by having their pain relieved by well fitting, extra-depth shoes. If this fails, Keller's arthroplasty is a safe and rapid way of giving some relief. This operation severely disrupts normal foot mechanics and should be reserved for the older, less active patient.

14 . 5 Claw Foot and Hammer Toes

These are common conditions. The terms "claw foot" and "claw toes" describe a condition of the foot where wasted muscles make the bones and the toe nails appear more prominent - like a dog's foot. Clawing implies muscle weakness or deficiency. Indeed on close analysis many of these patients do indeed have weak or denervated small muscles of the feet. This is often associated with minor spinal abnormalities such as spina bifida occulta. This means that claw toes should be approached with caution as far as surgery is concerned.

The term "hammer toe" is a description of the toe which, on the top, looks like the end of a hammer. Hammer toes are secondary to the disruption of the metatarsophalangeal joints. Abnormalities of the foot leading to prolapse of metatarsal heads and joint disruption are not understood. The patient may present with generally sore forefeet - often called rather grandly metatarsalgia. The cause of the primary lesion is unknown and treatment is often unsatisfactory. Surgery to hammer toes includes fusion of the interphalangeal joints in a straight position, so that they do not rub on the shoes. Often a good pair of soft and comfortable shoes is all that is required.

14.6 Neuromas

The cutaneous nerves to the toes may become trapped or irritated between the metatarsal heads giving rise to a neuroma (Morton's neuroma). The cause is uncertain except that it is almost certainly secondary to repetitive trauma and may be therefore associated with metatarsal head prolapse as described above.

The condition is difficult to diagnose with certainty although the pain is characteristically dull and throbbing, often with sharp exacerbations which are accompanied by tingling of the toes. It is equally difficult to localize. Classically, sideways compression of the foot produces a palpable click, reproducing the symptoms.

Treatment by excision may be accompanied by subsequent sensory disturbance to the affected toes. Recurrence is common even with care and patients should be warned about this.

14.7 Ingrowing Toe-nails

Although a minor disorder this very uncomfortable or painful condition causes much distress. The cause is unclear but is often associated with poor nail care. The curved nail grows into the nail fold and digs in. The trauma to the nail fold skin may lead to a secondary infection. This then becomes a self-perpetuating and long-term nagging infection with acute and very painful flare-ups. It can also lead to secondary blood-borne infections, which can have serious consequences if the sufferer has prosthetic joints or heart valves.

Careful nail care and straight cutting usually will control the condition. However, it may be necessary to remove the nail to clear up chronic infection. Definitive treatment can be problematic as the condition tends to recur. Wedge resection of the nail bed may retain the toe nail and remove the problem. The surest way of relieving the problem is to remove the nail bed using phenol after removing the nail, but some cosmetic surgery may also be necessary.

14.8 Plantar Fasciitis

The plantar fascia is a tough layer of fibrous tissue which runs from the os calcis to each toe base. The term plantar fasciitis includes a number of vague, but nevertheless very incapacitating painful disorders of the foot. The cause is entirely obscure and it originates spontaneously with a fairly sudden onset.

Patients characteristically complain of a soreness of the instep, often worse first thing on rising, or after sitting for a few hours. The symptoms are minimally relieved by walking but then persist as a debilitating ache, often exacerbated by a change of direction, or walking on rough ground. Most cases settle spontaneously (i.e. they are self-limiting) although the symptoms may last a few months or even years. On examination there may be tenderness at a point on the hindfoot, at the origin of the plantar fascia medially. Discomfort is often more diffuse.

There is no specific cure and the many, varied methods of relieving symptoms are less than satisfactory. Patients should be reassured that the condition will tend to get better. Insoles that are hollowed out under the tender area may help, but may cause discomfort around the edge of the hollow. Soft shoes and insoles, particularly modern sports trainers, can be of considerable value in relieving symptoms.

If there is a marked tender point, a local injection of steroids and long-acting local anesthetic can be very effective, although rather painful to administer. Some sufferers demand a surgical solution, and surgical stripping of the fascia from the os calcis is practiced. The results of this are entirely unpredictable.

14.9 Neuropathic Feet

Feet without sensation (sensory neuropathy) are prone to developing sores caused by the inability to perceive minor trauma from rubbing or treading on objects. Such problems are most common in areas where leprosy is normally seen, particularly in the far east. In the western world the

commonest cause of neuropathy is diabetes, and all diabetics need to be aware of the potential risk. They should regularly inspect their feet and be sure the nails are tidy. Footwear must be chosen with care and if necessary extra-depth shoes which are very soft on the uppers may be prescribed. This is essential as, once established, ulcers are difficult to heal and secondary infection may lead to amputation.

14 . 10 Achilles Tendinitis and Rupture

Pain around the Achilles tendon where it inserts into the os calcis is seen in two groups of people:

- ◆ **Young athletes:** signifying over-use. The area may be tender or even swollen. Rest is usually adequate to recover, but if it is recurrent, a surgical decompression of the tissue surrounding the tendon will often eradicate the symptoms. An injection of steroids is to be avoided as penetration of the tendon may lead to rupture.
- ◆ **Middle aged men:** a phase of discomfort may precede rupture of the Achilles tendon and this indicates degeneration within the tendon tissue. The cause is little understood, although we know that the lower part of the Achilles tendon has a poor blood supply and is often a point of weakness in some people who keep particularly active into middle age.

If the tendon ruptures it will heal if the ankle is kept in an equinus position for a minimum of eight weeks. The tendon can be sutured either by a closed technique or by open suture. The latter technique has a high risk of complication. Whatever method is chosen there is a significant risk of re-rupture, although this decreases with time. Wearing a felt raise inside the heel of the shoe, for as long as possible, will help.

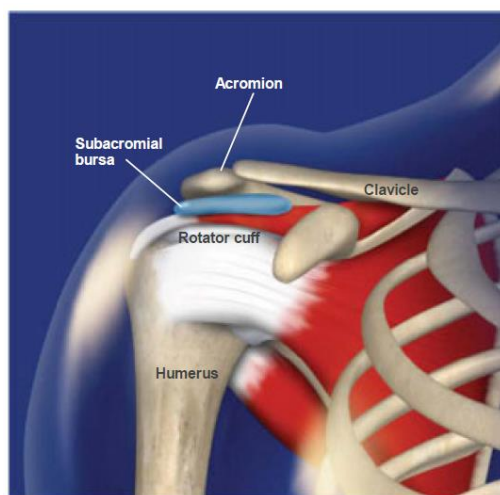
15. SHOULDER DISCOMFORT

15.1 Introduction

The shoulder joint (see Skeletal Anatomy - Unit 2) consists of the articulation between the scapula and the chest wall and between the scapula and the humerus. There are of course other joints to consider, particularly the acromioclavicular joint (the joint between the acromion process of the scapula and the clavicle). Good shoulder function relies on the bones and joints of the shoulder and the associated ligaments, muscles and tendons. All of these structures are frequently injured, particularly in people who are involved in heavy, repetitive work and/or contact sports.

15.2 Clinical Presentation

One symptom of shoulder discomfort is pain, particularly on movement. The pain may be limited to a particular range of movement. Symptoms quite frequently are associated with a recent incident such as a pull, or a period of unusual activity such as DIY.



The following structures commonly are involved in pathological conditions causing shoulder discomfort:

- ◆ the subacromial bursa
- ◆ the supraspinatus tendon
- ◆ the acromioclavicular joint
- ◆ the biceps tendon
- ◆ the rotator cuff as a whole

Unfortunately it may difficult or impossible to localize which of these structures gives rise to the symptoms. Fortunately most of the minor conditions settle with rest and time. To resolve the differential diagnosis may require specialist examination including arthrography or arthroscopy.

15.3 Management

If rest, gentle exercise and anti-inflammatory drugs do not help, a careful examination may reveal a point of tenderness. Tenderness under active movement within a painful arc is suggestive of a supraspinatus tendon inflammation or a subacromial bursitis. A steroid injection into the bursa or around the tendon, but not into it, can be very effective. Whether this is reasonable or not (and this remains controversial), it certainly should only be done with care.

Occasionally the sufferer may have very severe pain and a radiograph will show calcified material within the supraspinatus tendon. Injection or even surgery to remove the calcified material in this case is well justified for the pain relief achieved.

Unfortunately many people only respond temporarily to the injection. Further investigation often shows degenerative change, and osteophytes in the acromioclavicular joint. This may lead to rupture of the supraspinatus muscle which is part of the rotator cuff (see Skeletal Anatomy and Physiology module Unit 2b). Such rotator cuff tears can become large rents and even small ones cause a lot of discomfort and pain. Surgery to relieve the cause and repair the rotator cuff, will bring effective pain relief and some return of function. Repetitive injections in such patients can result in further degeneration of the rotator cuff and should not be practiced.

15.4 Frozen Shoulder

This is a poor term and is a very rare condition. Most so called "frozen shoulders" are sore shoulders caused by one of the conditions outlined above. Frozen shoulder is a condition in which there is little or no gleno-humeral movement. It occurs rarely, in those who have had a specific trauma incident, such as an epileptic fit or an electric shock. Often the cause is obscure.' Such people eventually recover in eighteen months to two years. They require a lot of psychological support and physiotherapy. The condition may be helped by manipulation under anesthetic.

SUMMARY

After studying section A, we may conclude that backache, although common, consists of a number of conditions which may be difficult to distinguish from each other. Fortunately mechanical backache and acute sprains, which are common, usually get better in time and the doctor's role is in helping to relieve the pain. The clinician must however be vigilant as there are some spinal problems which do need intervention (for instance surgery). These conditions include disc prolapse, although it must be emphasized that this condition is very rare.

The ability to tell these similar spinal diseases apart relies heavily on careful examination on the part of the doctor. In the last few years our understanding has been considerably enhanced by new imaging techniques including computerized axial tomography and magnetic resonance imaging. As these techniques allow us to check the accuracy of the diagnosis then the number of poorly understood clinical problems will diminish and so our ability to treat backache accurately will improve.

Section B has discussed in very simple terms the conditions which affect the musculoskeletal system in childhood. It is important to remember that the so called commoner conditions still affect only the minority of children and that the rare ones are very rare indeed. Birth abnormalities occur only once or twice per hundred births and acquired abnormalities are even less common.

The section will help you place the conditions of childhood in perspective. Many of the conditions discussed are not likely to be treated by surgery but many may require temporary or permanent disability. Nevertheless it is important to have a broad knowledge and awareness of these conditions.

Section C has dealt, in a very simple way, with a lot of common conditions. Although common, and thankfully mostly self-limiting, these conditions are not always simple and their treatment is often very restricted, largely because we do not know what causes them.

GLOSSARY

spondylitides	cervical disc disease	idiopathic
spondylitis	genu valgum	limp
pain	genu varum	osteochondritis
local pain	in-toeing	SUFE
referred pain	anteverted femoral neck	enthesopathy
nerve root pain	tibial torsion	prognosis
sciatica	abnormal forefeet	neuropraxia
localizing signs	flat foot	tenosynovitis
back sprains	curly toes	bursitis
anti-inflammatory drugs	Osgood Schlatter's disease	bursa
analgesia	adolescent knee pain	fiat feet
mechanical backache	chondromalacia patellae	bunions
spondylosis	CDH	corns
osteoarthritis	congenital hip dysplasia	hallux
spondylolisthesis	club foot	hallux valgus
pars interarticularis	talipes equino varus	hallux rigidus
spinal corset	spina bifida	claw foot
spondylolysis	meningomyelocele	hammer toe
fusion	spina bifida occulta	metatarsalgia
disc prolapse	diastamatomyelia	neuroma
nucleus pulposus	spina bifida cystica	ingrowing toe-nails
annulus fibrosis	hydrocephalus	plantar fascia
cauda equina	cerebral palsy	plantar fasciitis
myelography	hemiparesis	sensory neuropathy
myelogram	paraparesis	Achilles tendinitis
bony root entrapment	quadraparesis	shoulder discomfort
cervical spondylosis	spasticity	frozen shoulder
analgesics	scoliosis	

cervical disc

disease

genu valgum

genu varum

in-toeing

anteverted femoral

neck

tibial torsion



abnormal forefeet

flat foot

curly toes

Osgood Schlatter's

disease

adolescent knee

pain

chondromalacia

patellae

CDH

congenital hip

dysplasia

club foot

talipes equino

varus

spina bifida

meningomyelocele

spina bifida occulta

diastatomyelia

spina bifida cystica

hydrocephalus

cerebral palsy

hemiparesis

paraparesis

quadraparesis

spasticity

scoliosis

ORTHOPEDIC MEDICINE

UNIT V

TRAUMA

UNIT 5 – Section Objectives

OBJECTIVES

At the end of this unit you should be able to:

1. Describe a fracture in terms of its type and the position of the bone fragments.
2. Make inferences about how a fracture was caused.
3. Discuss how the cause of a fracture affects the treatment.
4. Describe the initial management and investigation of an injured patient.
5. List the four major methods used to treat a fracture.
6. List the early and the late complications of fractures.

UNIT 5 – Trauma

1. INTRODUCTION
 2. HISTORY TAKING AFTER TRAUMA
 - 2.1 Clinical Aspects
 - 2.2 Medico-legal Aspects
 3. CLINICAL EXAMINATION
 - 3.1 The Signs of a Fracture
 - 3.2 Injury to Other Tissues
 4. INVESTIGATING FRACTURES
 - 4.1 X-rays
 - 4.2 Tomograms
 - 4.3 Computerized Axial Tomography
 - 4.4 Ultrasound
 - 4.5 Radioisotope Scanning
 5. DESCRIBING FRACTURES
 - 5.1 Fracture Architecture
 6. IMMEDIATE MANGEMENT
 - 6.1 Pain Relief
 - 6.2 Blood Loss
 - 6.3 Open Fractures
 7. DEFINITIVE MANAGEMENT OPTIONS
 - 7.1 Definitive Management
 - 7.2 The Injured Person
 - 7.3 Basic Rules
 - 7.4 Reduction
 - 7.5 Holding
 8. HOW FRACTURES HEAL
 9. A PRACTICAL GUIDE TO FRACTURE MANAGEMENT
 - 9.1 Low Energy Injuries
 - 9.2 Fractures Involving Joints
 - 9.3 High Velocity Injuries
 - 9.4 The Injured Person
 - 9.5 Choices
 10. COMPLICATIONS OF FRACTURES
 - 10.1 Introduction
 - 10.2 Infection
 - 10.3 Fat Embolism
 - 10.4 Renal Failure
 - 10.5 Compartment Syndrome
 - 10.6 Immobility
 - 10.7 Delayed and Non-union
 - 10.8 Mal-union
 - 10.9 Growth Arrest
 - 10.10 Arthritis
- SUMMARY**

TRAUMA

1. INTRODUCTION

Trauma is an injury to the body, usually resulting from an external force. Trauma results in damage to body tissues in muscles, blood vessels, nerves, ligaments and bones. In this module we will concentrate on skeletal trauma. Skeletal trauma is injury of the skeletal system, usually resulting in broken bones (fractures).

Broken bones are a common phenomenon. Most people have either broken one of their own bones or know someone who has broken a bone.

Some of us think of bones as dead, inert things but in reality they are very much alive. They have a very rich blood supply and the periosteum (the membrane which covers the outside of bones) has a nerve supply. Therefore the immediate consequences of breaking a bone (fracture) are severe pain and blood loss. The early management of a fracture must concentrate on minimizing the effects of blood loss and reducing the pain.

In the longer term the rich blood supply to the bone must be re-established before the bone will heal. From the outset, therefore, the condition of the soft tissues containing the blood vessels will be considered by the surgeon when choosing the most appropriate treatment.

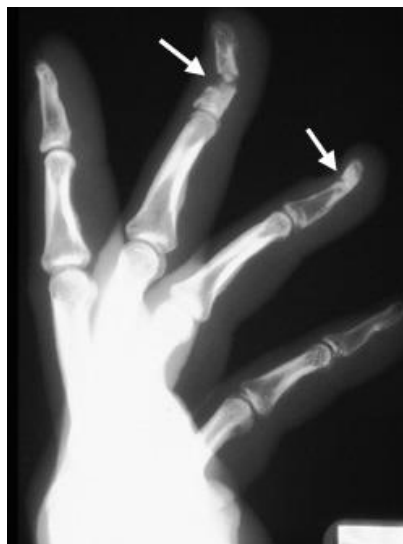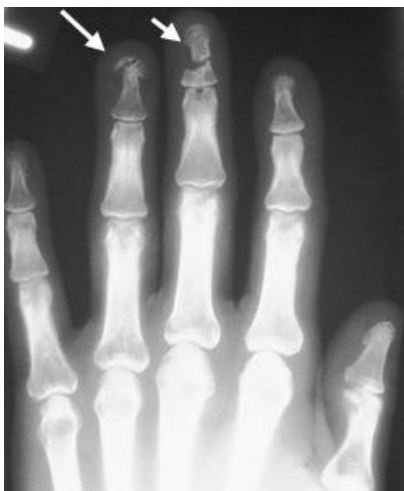Finally it must be remembered that, although fractures are serious injuries, other injuries received in the same incident (head, chest and abdominal injuries) may be more serious. So, although fractures may be obvious, they are not the surgeon's first consideration when treating an injured person.

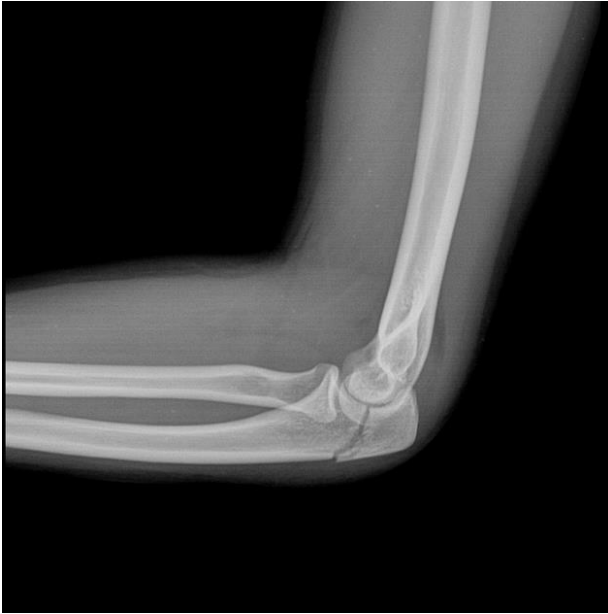2. HISTORY TAKING AFTER TRAUMA

After trauma, a careful history (information about the person and the circumstances before, during and after the injury) must be taken. There are two principal reasons for this: clinical and medico-legal.

2.1 Clinical Aspects

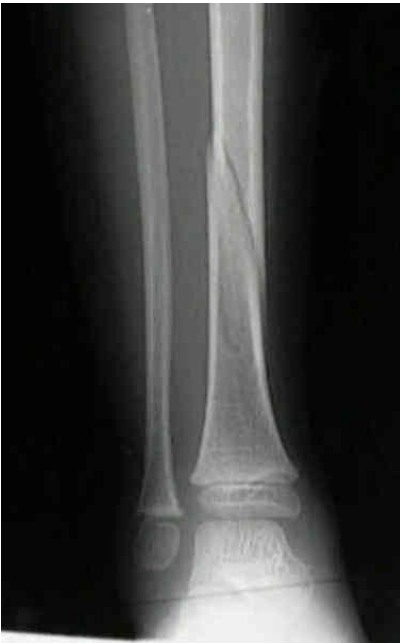Bones may be fractured (broken) in many ways, from simple accidents in the home (which are the most common) to high velocity transport accidents or, more rarely, in battle. See Figure 1A (a crashing injury), Figure 1B (a direct fall causing a fracture), and 1C (a fracture caused by a twisting or indirect force).





*FIGURE. A DIRECT FALL
CAUSING A FRACTURE.*

<http://radiopaedia.org/articles/elbow-radiograph-an-approach>



*FIGURE. A FRACTURE CAUSED BY A
TWISTING OR INDIRECT FORCE.*

<http://www.wheelsonline.com/image4/i1/tib34.jpg>

The following questions about the injury must be answered:

- ◆ What happened?

Fractures at a particular site can look the same. The appearance of a fracture on a radiograph may not give much of a clue to the severity of an injury. There is a world of difference, however, between gaining a fracture from slipping off a step and from being hit by a car. In these two extreme examples the first involves little energy transfer to the affected part of the body and the second usually involves quite a lot. The amount of energy transferred to the body in an accident determines not only the injury to the bone, but also the soft tissue damage and the extent to which the blood supply is disrupted. Therefore it is important to find out what happened from the victim, any witnesses available and members of the ambulance and rescue services.

- ◆ How did it happen?

Finding out how the accident happened can also help because injuries tend not to occur randomly, but in some sort of pattern. For example, a pedestrian hit by a car tends to receive leg injuries from the bumper, pelvic and abdominal injuries from the bonnet and head injuries from the door

pillar. Knowing something about these patterns permits the examiner to predict potential injuries and she/he is therefore less likely to miss them.

◆ Where and when?

It is also useful to know when and where the accident happened, as a long delay between injury and treatment may limit the options for treatment.

◆ What was the injured person like before it happened?

Once the circumstances of the injury are appreciated, the injured person should have a full history taken. This is, of course, secondary to essential treatment required to protect the passage of air into the lungs and to control any bleeding. It is important to establish as much information as possible

about the injured person's previous general medical state. Often, medical conditions may be associated with an injury. For example, the injured person may have had a fit or may have collapsed with a hypoglycemic attack because she/he is diabetic. In the elderly in particular, a fracture may have occurred as a result of a fall during a heart attack or a stroke.

Many patients with fractures may need an anesthetic and so the condition of the cardiovascular and respiratory system must be established. The last time the injured person ate or drank must be ascertained so that surgery can be delayed, if possible, until the stomach is empty to reduce the risk of breathing in vomit.

◆ Who is the person?

Finally, when circumstances permit, a social history is important. The status of the injured person before the injury must be established. Where do they live and with whom? Do they have stairs to climb into the house or flat or within the home? Can the older injured person go to relatives after any hospital stay to rehabilitate? The planning of recovery starts with admission to hospital and not as an afterthought just before discharge. Sending an old person home to a cold top floor flat with no heating and no relatives on a Friday night, with no social provision, is of no benefit to the injured person, no matter how well the fracture has been treated in hospital.

2.2 Medico-legal Aspects

Accidents have all sorts of consequences. They will affect the victims personally, and their families. They will also, depending on the circumstances, have effects relating to insurance and litigation.

Therefore it is important to keep meticulous notes and to make them at the time of examination and treatment, or as soon afterwards as possible. Legible and complete notes are essential as it is often months or even years before a doctor may be called to give an account of an accident.

3. CLINICAL EXAMINATION

Suspicion of a fracture may have arisen from the history of the accident. This diagnosis can first of all be tested by clinical examination for the signs of a fracture. The signs of a fracture are described below.

3.1 The Signs of a Fracture

3.1.1 Pain

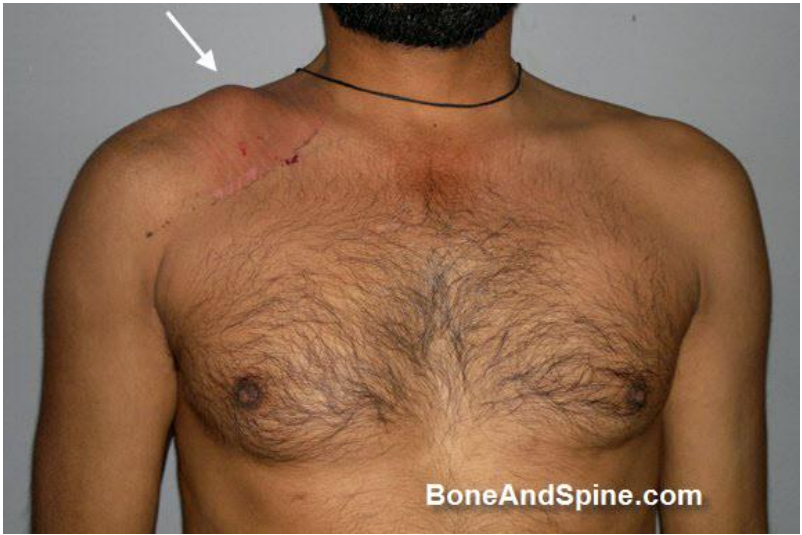
As we have already stated, a fractured bone is painful. The injured person will be able to tell the doctor if she/he is experiencing pain. A limb with a suspected fracture should never be moved suddenly and never without support from a splint. The doctor should ensure that the injured person has adequate pain relief.

3.1.2 Deformity

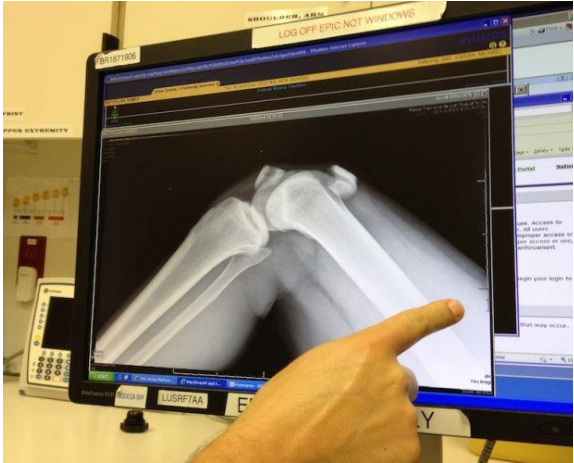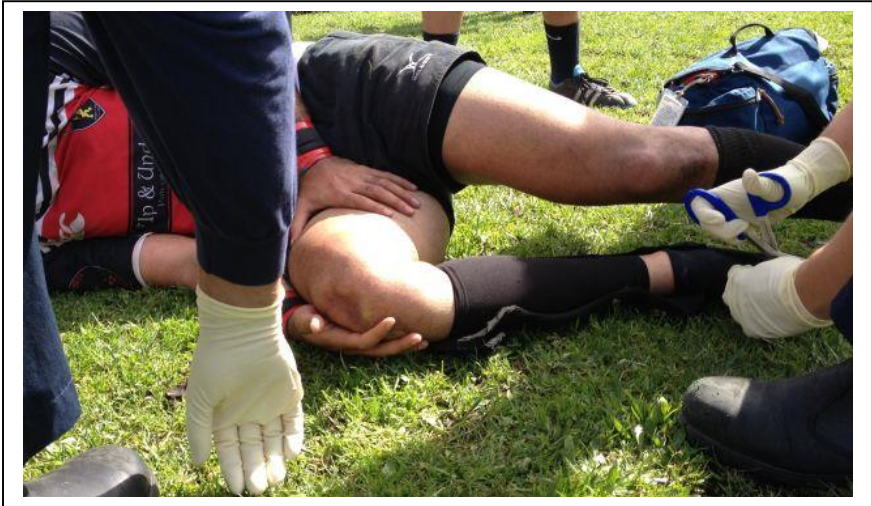A fractured bone may result in a change in the normal appearance of the injured part. The position of the distal fragment of a fractured bone is determined by gravity, this is to say it can move under its own weight. The position of the proximal fragment is determined by the muscles. Sometimes the deformity is influenced by the direction of the force which caused the fracture. **3.1.3**

Tenderness

As well as being painful, the area around a suspected fracture is tender - it hurts when touched or pressed as in Figure 3.



www.boneandspine.com



<http://deadspin.com/todays-horrific-rugby-injury-exploded-patella-1542792624>

3.1.4 Swelling

Swelling is a natural reaction to injury, but excessive swelling is painful and makes treatment and recovery more difficult (Figure 4). To reduce swelling, the injured part can be elevated. An injured arm should be raised above the level of the heart as this will help fluid to drain. In the case of an injured leg, the injured person should be lying down with the leg raised above chest level. No single act is as important as mis in the first aid treatment of fractures.

3.1.3 Tenderness

As well as being painful, the area around a suspected fracture is tender - it hurts when touched or pressed as in Figure 3.

3.1.4 Swelling

Swelling is a natural reaction to injury, but excessive swelling is painful and makes treatment and recovery more difficult (Figure 4). To reduce swelling, the injured part can be elevated. An injured arm should be raised above the level of the heart as this will help fluid to drain. In the case of an injured leg, the injured person should be lying down with the leg raised above chest level. No single act is as important as mis in the first aid treatment of fractures.

3.1.5 Discoloration or bruising

Loss of blood and swelling causes changes in color which can help in diagnosis. It is possible to age an injury according to the discoloration present. At first it is dark because of the deoxygenated blood loss into the soft tissues. Then, as the hemoglobin in the red blood cells is broken down and carried away to the liver by scavenger cells, the color changes to green and then to yellow.

3.1.6 Loss of function

Breaking a bone is most likely to result in the loss of normal function in the injured part of the body.

3.1.7 Crepitus

Crepitus may be perceived as a grating feeling when examining an injury but, to deliberately look for this sign will not be appreciated by the injured person!



www.orthopedicarizona.com

FIGURE. CREPITUS: WHEN A BROKEN BONE IS MOVED THE TWO ENDS GRATE TOGETHER • SO BE CAREFUL!

3.2 Injury to Other Tissues

During clinical examination, as well as looking for signs of a fracture, the clinician makes an assessment of the injury to other body tissues such as: the skin, the fat, the muscle, the blood vessels, and the nerves.

If a fracture is suspected from the history and the clinical examination, it can be confirmed using investigative techniques. The most commonly used of these techniques are described in the following section.

4. INVESTIGATING FRACTURES

4.1 X-rays

The mainstay for investigating a fracture is of course the X-ray. The radiograph (an X-ray picture) confirms the diagnosis and helps in planning the management of the injury. Usually, two X-ray views are taken of the injury - one in the sagittal plane and one in the coronal plane in order to reduce the chances of missing any injury.

4.2 Tomograms

A tomogram is a view of "slice" through a part of the body. The earliest tomograms were obtained using a narrow beam of X-rays which were moved, with the X-ray film, round the part of the body to be investigated. By modern standards, this technique did not produce very clear pictures, and gave the injured person an undesirably large dose of X-rays. X-ray machines use electronic detectors in place of X-ray film. This technique is very useful where an area is difficult to distinguish because of many structures overlapping. For instance the axis bone in the cervical region of the spine is often difficult to see on a radiograph amongst confusing shadows at the base of the skull and from the jaw and teeth.

4.3 Computerized Axial Tomography

Using modern tomographic techniques, computers can be used to generate tomograms on a video screen, and to print out the results on paper. This technique is known as Computer Aided Tomography (or Computerized Axial Tomography), hence the term "CAT scanner".

4.4 Ultrasound

When investigating a fracture, ultrasound scanning can show the resulting accumulation of fluid (especially blood).

4.5 Radioisotope Scanning

This technique involves injecting a very small quantity of a radioactive substance into the bloodstream of the injured person. The radioactive substance attaches to phosphate molecules which are actively taken up by bone. The radioactive substance therefore ends up in the bones. An X-ray plate is then exposed under the affected part of the body and a radiograph of the bone is obtained. The more metabolically active the bone is, the faster it takes up the radioactive substance. The sites of unusual metabolic activity (i.e. at the site of the fracture) can be clearly seen on the radiograph.

Where there is clinical doubt, radioisotope bone scanning can help in determining whether a bone is fractured or not. This is more useful in situations which are not acute, at about two weeks from the time of injury. It is a highly sensitive test but does not tell us anything about the fracture except that it is there. This technique is often used when a scaphoid (a bone in the wrist) fracture is suspected, as this is not easily seen on a first X-ray.

5. DESCRIBING FRACTURES

It is important to describe the shape and degree of fragmentation of a fracture because these features indicate the amount of energy which has caused the injury, and so help us to understand it and how we may treat it.

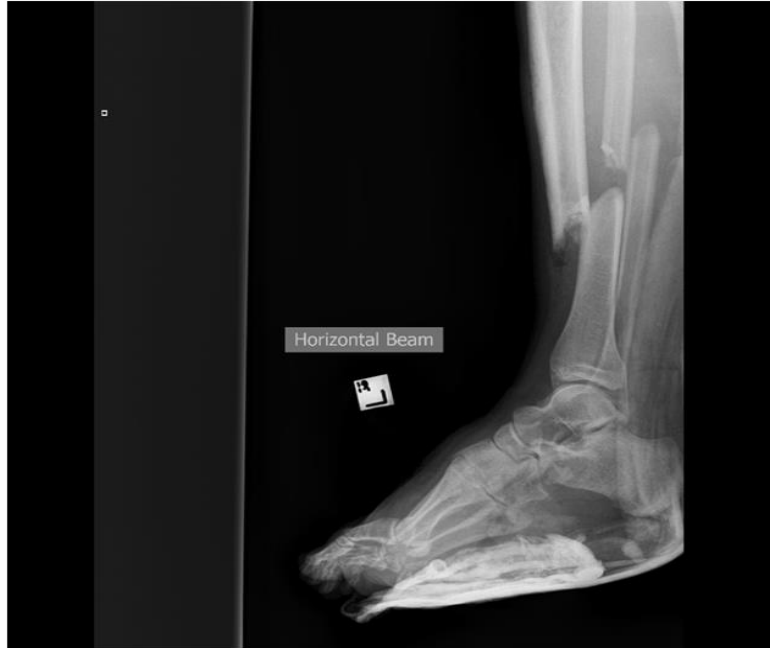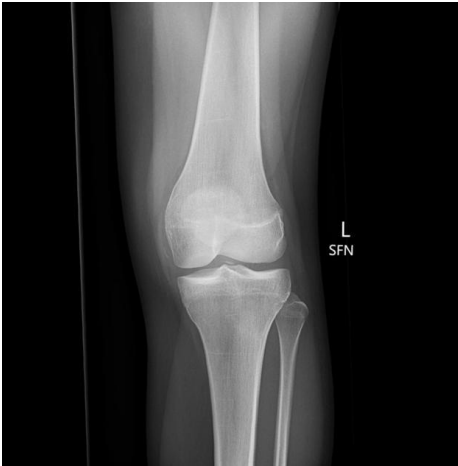5.1 Fracture Architecture

Once the fracture has been diagnosed, a description of the fracture must be noted.

It is useful to have a convention to describe injuries. A descriptive convention which is universal and relevant to subsequent management may be achieved by obtaining the answers to the questions below:

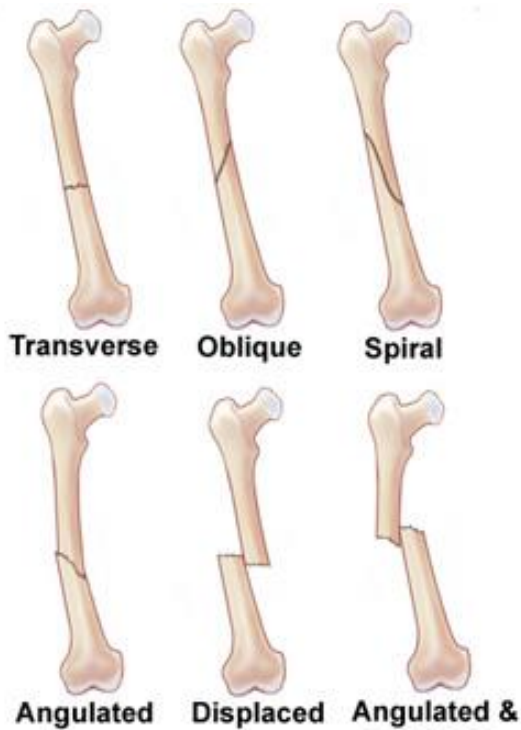
- ◆ Which bone is broken and on which side?
- ◆ Is the fracture open or closed?
Is the skin broken? - open fracture. Is the skin intact? - closed fracture
- ◆ Where on the bone is it broken?

Intra-articular (in the joint)? Mid-shaft? Proximal, middle or lower third?



www.radiopedia.org

◆ What shape is the fracture? Spiral? Oblique? Transverse?

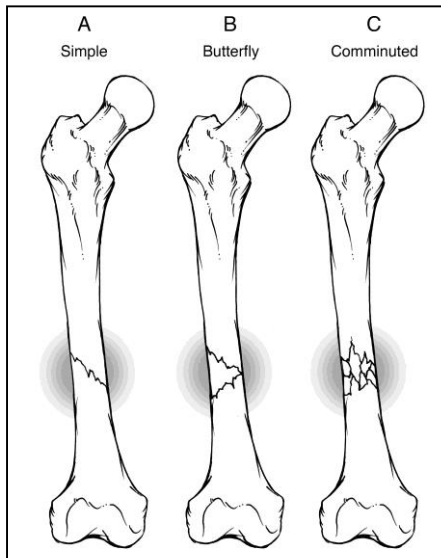


www.yoursurgery.com

Spiral fractures occur through twisting, which is a common, low energy mode of injury. Such injuries are usually associated with little soft tissue damage, so the blood supply to the bone is preserved and healing is unlikely to be a problem.

In contrast, oblique and transverse fractures are caused by buckling or direct injury to the bone. This involves a lot of energy, resulting in soft tissue stripping and damage to the blood supply. Such injuries will require a lot more consideration when the choice of treatment is being made and usually take longer to heal.

- ◆ How many fragments? Simple? Butterfly? Comminuted?



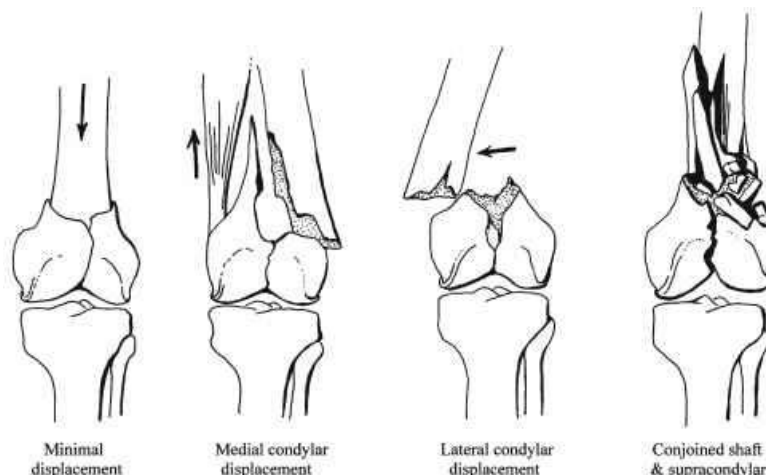
www.ebooks.cambridge.org

- ◆ What is the position of the distal fragment?

All fractures must be described in three dimensions with the position of the distal fragment being described relative to the proximal one. This is logical because the proximal fragment takes up a position determined by the new muscle balance and so treatment must be aimed at repositioning the distal fragment.

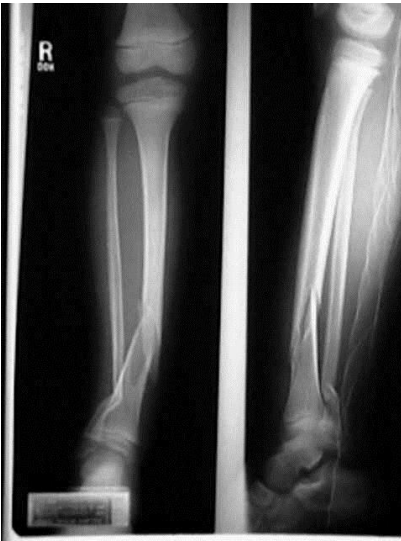The fragment is therefore described in terms of:

Displacement: which may be anterior, posterior, medial or lateral.

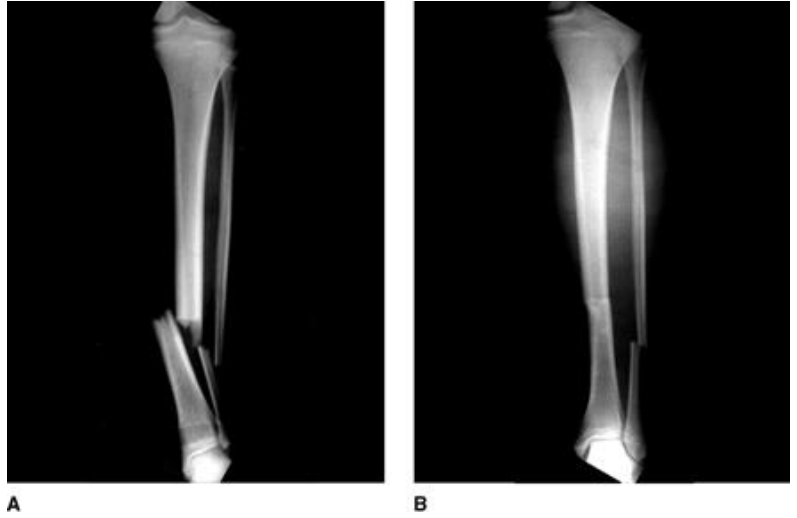

www.arthritisresearch.us

Angulation: which may be anterior, posterior, varus or valgus.

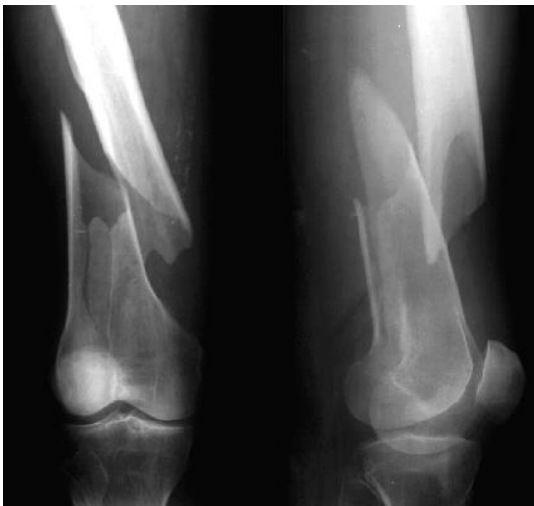

<http://www.wheelsonline.com/images/tibfx1.jpg>



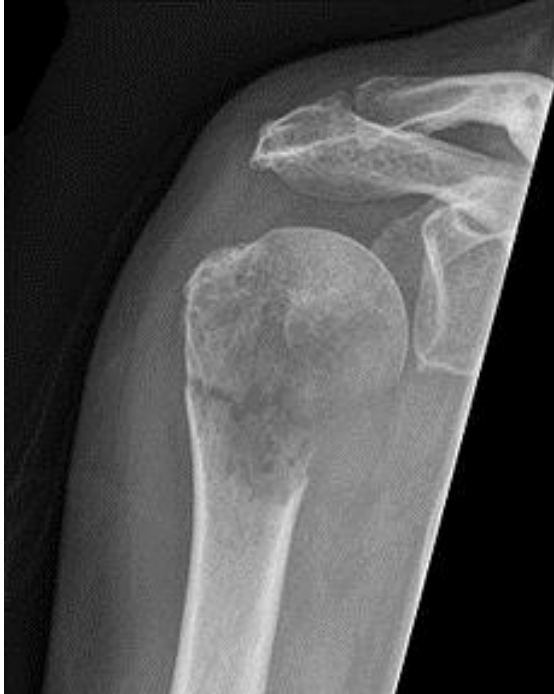<https://www.jaaos.org/content/13/5/345/F1.expansion>

Rotation: which may be internal or external



www.klinikaikozpont.u-szeged.hu

- ◆ Could it be a pathological fracture?



http://en.wikipedia.org/wiki/Pathologic_fracture

FIGURE. PATHOLOGICAL FRACTURE OF THE HUMERUS CAUSED BY A TUMOUR DEPOSIT.

A pathological fracture is one in which the fracture seems out of proportion to the violence of the injury. This suggests that the bone is weak as a result of osteoporosis or other diseases such as cancer.

6. IMMEDIATE MANAGEMENT

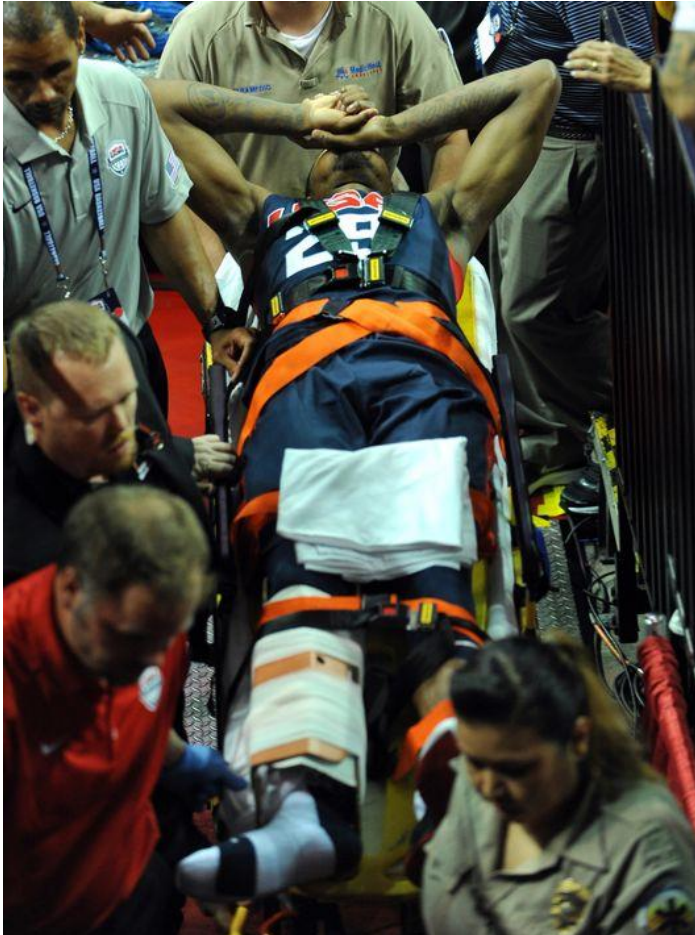
6.1 Pain Relief

This may be achieved in two ways.

- ◆ Use of pain-killing drugs.

Strong pain-killing injections of morphine or pethidine are usually necessary.

- ◆ Splintage (a splint is a device which holds a fracture steady).



<http://www.usatoday.com/story/sports/nba/pacers/2014/08/02/paul-george-surgery-compound-fracture-tibia-fibula-team-usa/13505781/>

FIGURE. EXAMPLES OF SIMPLE SPLINTS APPROPRIATE IN FIRST AID AND AS INITIAL TREATMENT IN HOSPITAL.

A splint (Figure 14) can be applied to most fractures before arriving at hospital. This alone can relieve pain. In general a splint should encompass the joint above and below an injury. Simple expedients such as binding the arm to the chest, with or without a sling, or simply binding the legs together are often sufficient.

Even in the Accident and Emergency department, splints may be simple; for example two bits of wood knocked together with nails and then padded may be used in an emergency as a splint. The splint may need to be removed for definitive examination and radiographs, but repeated removal for innumerable doctors to examine the injured person should be avoided as this simply compounds the discomfort.

An alternative to splintage is traction, which may be used early in treatment to relieve muscle spasm, which is a major component of post-fracture pain. This is particularly useful for fractures

of the femoral neck where splintage is almost impossible to apply.

6.2 Blood Loss

For most upper limb and peripheral lower limb fractures, blood loss is in itself not too serious and is tolerated even by an elderly person. In major long bone fractures, particularly of the femur and to a lesser extent the tibia, blood loss is significant. In general, an injured person with a femoral fracture will lose between two and three units of blood (one unit is about 450ml or one pint) into the soft tissues. A tibial fracture may result in the loss of one unit which is in itself tolerable, but combined with other injuries may become significant.

Major pelvic fractures, particularly if unstable, are associated with major venous bleeding from the pelvic plexuses. The blood loss can be considerable, amounting to six units or so. If it is combined with other skeletal injury, this level of loss is potentially lethal unless the fluid is replaced, preferably with blood, as soon as possible.

In general, all patients with major long bone injuries should be cross-matched for blood and a good sized venous line for blood transfusion should be established as soon as possible. For pelvic fractures two lines may be needed and a central venous line should be established to ensure that transfusion is keeping up with loss.

6.3 Open Fractures

Open (also called compound) fractures are serious injuries in which the skin is broken. They tend to occur in more violent injuries and result in the bone being contaminated by bacteria from the environment. All wounds are contaminated, and the treatment strategy is to clean them out and remove all dead tissue as soon as possible, to prevent a contamination becoming an infection.

An open fracture is a surgical emergency, and provided that the patient's general condition permits, should be taken to the operating theatre as soon as possible. There the wound can be extended surgically and all debris and suspected dead tissue removed. Even in small wounds, bits of clothing which (inevitably have bacteria on them), dirt and fragments of wood or metal can be found. These will only be discovered if a wide incision is made and exploration down to the bone is performed.

Wounds are better left open if there is any doubt that closure can be achieved without any tension on the skin. This means that the vast majority of wounds should be left open and closed either as a secondary procedure after a few days or left to heal spontaneously. Such patients all need supplementary broad spectrum antibiotics and some form of tetanus protection, but all these are secondary to cleaning out the dirt debris and dead tissue.

7. DEFINITIVE MANAGEMENT OPTIONS

7.1 Definitive Management

The essential strategy of long term fracture management must be to return the injured person to their pre-injury level of function by the safest means possible. The factors which will determine the tactics used to achieve this aim will depend on the injured person, the injury and the surgeon. Definitive management is defined as the technique used (after bleeding and pain have been controlled) to restore normal function to the injured part of the body (usually a limb), after a fracture.

7.2 The Injured Person

Functional requirements vary from individual to individual depending on many factors including the age, physical health and occupation of the injured person.

For instance, older individuals with a fractured bone may also have poor bone quality due to osteoporosis (Skeletal Anatomy and Physiology Unit 2) and may have medical problems such as heart disease or diabetes. This would present a difficult managerial challenge, so in this situation the clinical manager may opt for a less than perfect result, as long as this would not significantly affect the daily activities of the individual concerned. An example of this is how fractures of the

wrist are treated in the elderly. The fracture may be treated under local anaesthesia in the Accident and Emergency department. Although this might not achieve the perfect result, the injured person can then be discharged home to an environment where they may function satisfactorily without further extensive treatment, which could lead to unnecessary complications such as bedsores, pneumonia or urinary infections.

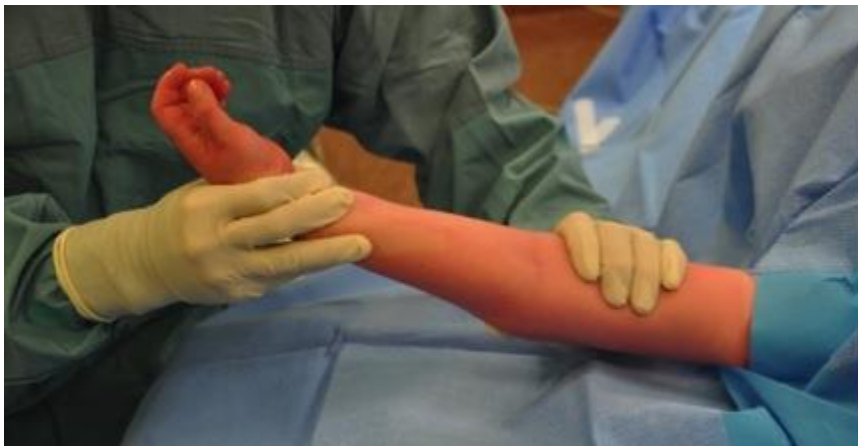On the other hand a young fit, right handed craftsman or woman who injures his/her right wrist joint may be prepared to spend many months undergoing treatment to ensure a perfect result because that is what is required for his/her long term health and employment security.

As always, the benefit must outweigh the risk in the treatment strategy and the psychological effects of injuries on all patients, irrespective of age, should not be underestimated. A young and well person will tolerate long term treatment and surgery with no physical detriment, but in the older patient, perfect function may sometimes only be achieved at the expense of the risk of complications. These examples illustrate some of the diverse problems facing the fracture surgeon.

7.3 Basic Rules

In order to achieve acceptable function, the anatomy of a fracture should be returned to as near normal as is safely and practically possible. If the fracture passes into a joint then the anatomy should be restored accurately if acceptable function is to be achieved. If a fracture occurs through the shaft of a long bone then the margin for error is much greater and something less than perfect is acceptable. However, some injuries are so severe that normal restoration is impossible.

Restoration to normal position is achieved by a process which is called reduction. The fracture must be reduced to the normal position and then held there until the bone heals naturally.



<http://www.orthopaedicsone.com/display/Main/Closed+Reduction+and+Percutaneous+Pinning+of+Supracondylar+Fracture+of+the+Humerus>

7.4 Reduction

Closed reduction may be achieved by traction on the distal fragment and then a relocation of that distal part back onto the proximal fragment by manipulation. In order to achieve a reduction, adequate analgesia is necessary and general or regional anesthesia may be used. The manipulative procedure usually involves reversing the direction of the deforming force.

If such a maneuver is unsuccessful then open reduction may be required whereby the fracture site is opened surgically and the fragments are relocated directly under vision.

7.5 Holding

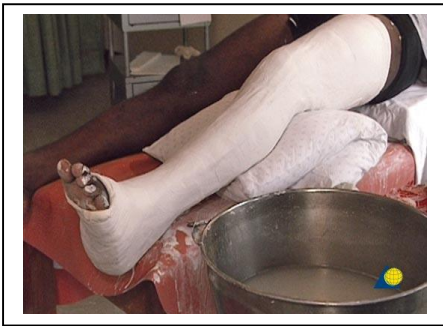Once the fracture is adequately realigned, it must be held in the desired position until the bone has become strong enough to support itself (united) and then protected until it is strong enough to bear some load (consolidated).

Fractures may be held in place by:

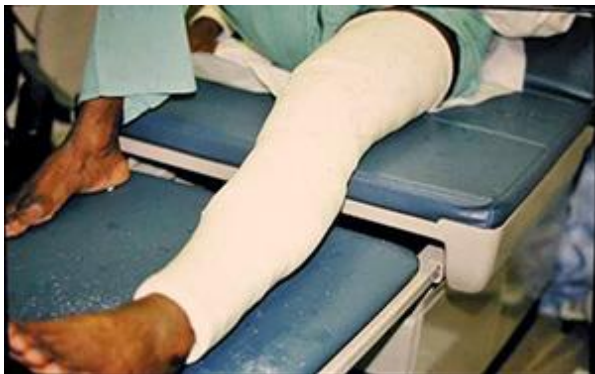- ◆ casting - surrounding the broken limb with a hard 'coat' which holds the fracture steady,
- ◆ external fixation - an external 'bar' outside the body attached to pins sited in the broken bones,
- ◆ internal fixation - holding broken bones together using screws and plates inside the body,
- ◆ traction - pulling on a broken limb to align the bones

7.5.1 Casting

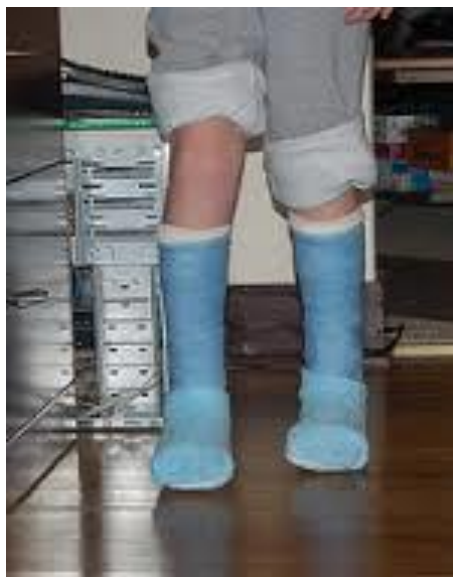Once the fracture is manipulated, the holding exercise may simply involve placing the limb in a plaster of paris cast until union. The fracture must be held in the correct position by the cast and it must be maintained at the proper length, neither too short nor too long as the latter position may delay union. In order to ensure complete control of all dimensions of the fracture the cast must also immobilize the joints above and below the fracture site, as joint movement may result in distortion in one or more dimensions. There are other techniques for achieving this and they will be discussed later.



https://www2.aofoundation.org/wps/portal/!ut/p/a0/04_Sj9CPykssy0xPLMnMz0vMAfGjzOKN_A0M3D2D_Dbz9_UMMDRyDXQ3dw9wMDAzMjflULsh0VAbWjLW0!/?bone=Femur&classification=33-A2&method=Long%20leg%20cast&segment=Distal&showPage=redfix&treatment=Non%20operative



<http://nurse-practitioners-and-physician-assistants.advanceweb.com/Columns/Case-Files/Axial-Loading-as-a-Cause-of-Tibial-Plateau-Fracture.aspx>



www.flickr.com

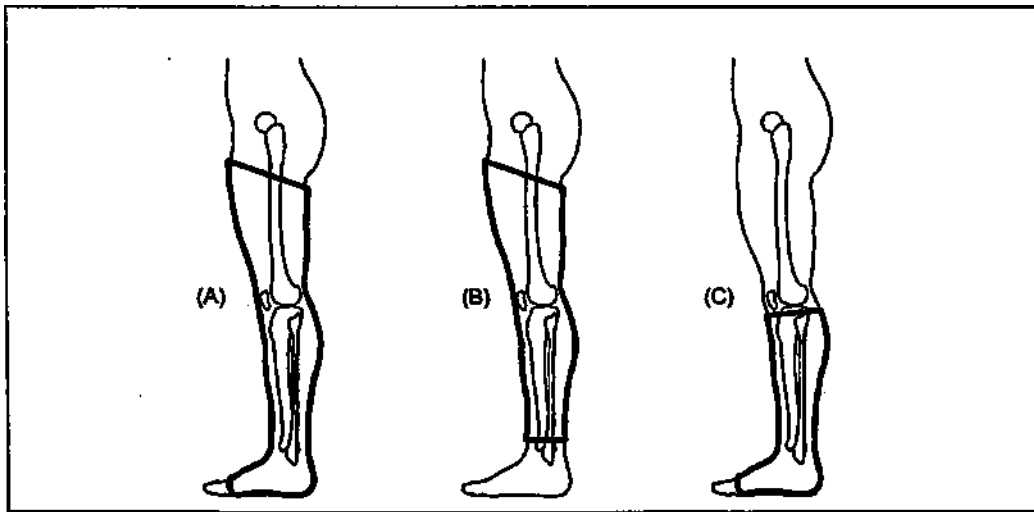


FIGURE. (A) FULL LENGTH CAST (B) LEG CYLINDER CAST (C) BELOW KNEE CAST.

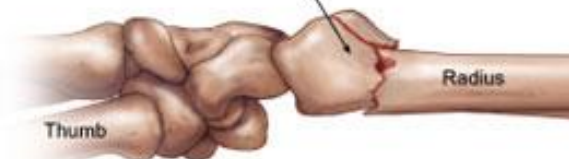◆ How does a cast work?

A cast acts as a splint. By controlling joint movement and position it may be used to control posture. The plaster cast is molded so that the pressure is exerted at three points, (see Figure below), molding the fractured bone in the correct position until it has healed.

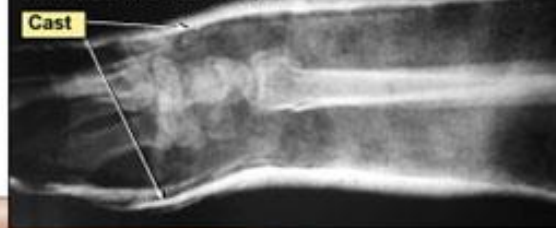11/14/98 Reduced Right Wrist Fractures

11/14/98 Medial View

Anatomic re-alignment at the distal radius with application of cast

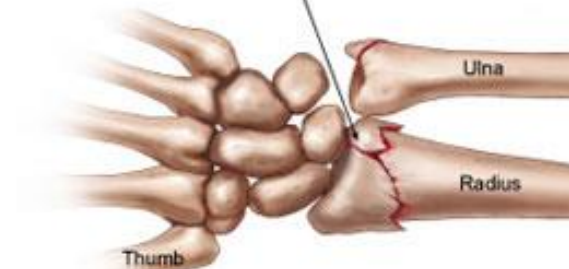


11/14/98 Medial X-ray

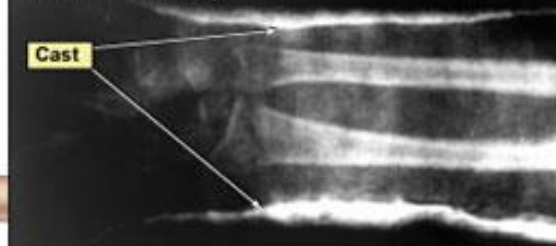


11/14/98 Dorsal View

Anatomic re-alignment at the distal radius with application of cast



11/14/98 AP X-ray



THESE IMAGES ARE COPYRIGHTED BY AMICUS VISUAL SOLUTIONS. COPYRIGHT LAW ALLOWS A \$150,000 PENALTY FOR UNAUTHORIZED USE. CALL 1-877-303-1952 FOR LICENSE.

© 2006, Amicus Visual Solutions

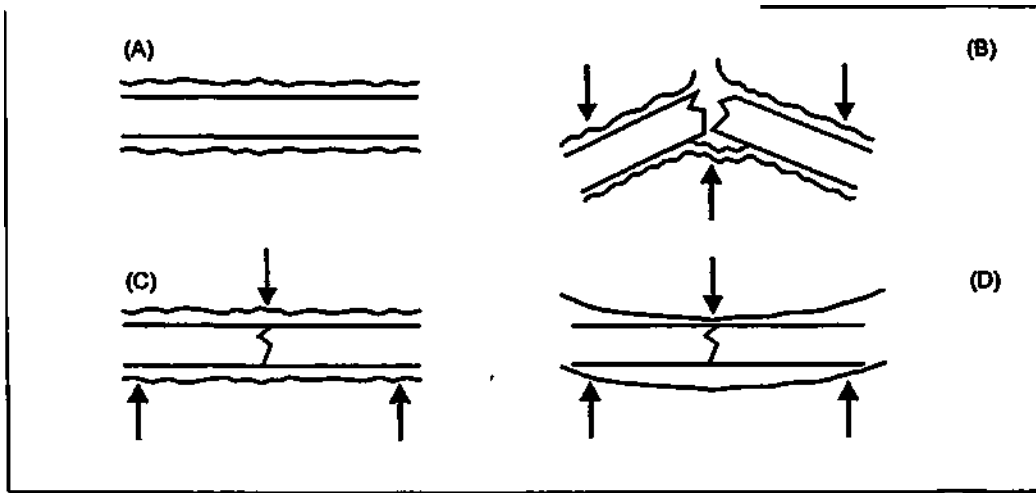


FIGURE. (A) THE BONE and ANDURROUNDING PERIOSTEUM
 (B) WHEN A BONE IS BROKEN IT SNAPS ABOUT A POINT WHEN AN EXCESSIVE FORCE IS APPLIED • LIKE BREAKING A STICK OVER YOUR KNEE (C) REDUCTION INVOLVES REVERSING THE DIRECTION OF THE DEFORMING FORCE (D) A PLASTER IS MOULDED TO MIMIC THE DIRECTION OF THE REDUCING FORCE SUFFICIENT TO HOLD THE REDUCTION.

Casts have many disadvantages. They are heavy and they immobilize the joints. Clinicians cannot examine the covered part, or use investigative techniques such as X-ray. Apart from the cost and inconvenience in having to remove them during treatment to assess progress, the immobility imposed on a limb results in muscle wasting and limited mobility due to joint stiffness.

Functional braces

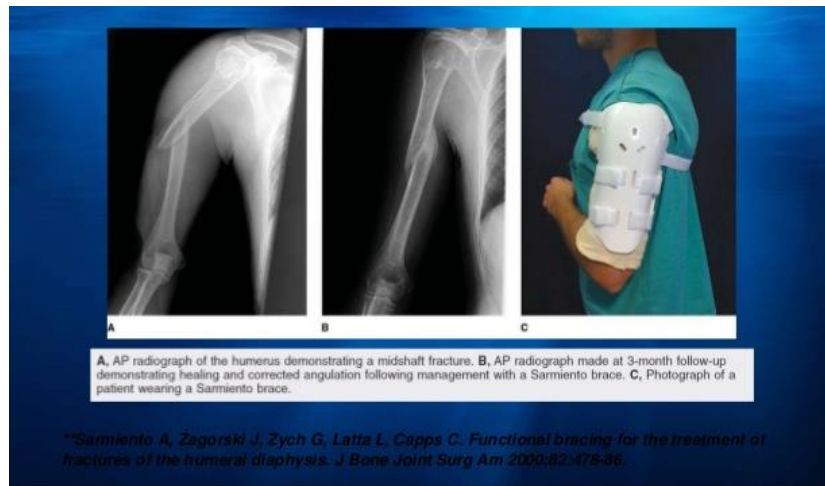It is possible to overcome the disadvantages of a plaster cast (outlined above) by freeing the joints. In order to maintain three dimensional control of the fracture it is necessary to support the cast at the joints by a combination of accurate molding and the provision of hinges, which permit motion in one direction, usually flexion and extension.

These braces are highly dependent on a very accurate fit and so they tend to be used after a few weeks, when pain and swelling have settled).



www.imgarcade.com

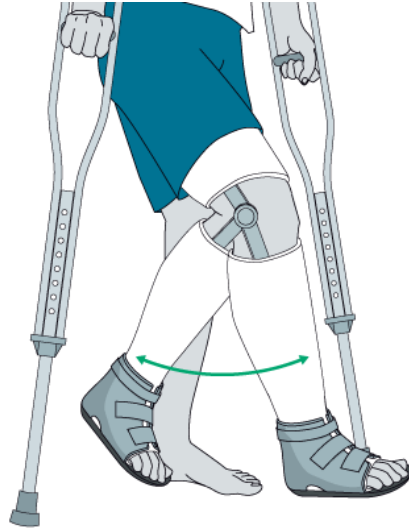
www.slideshare.net



Modern casting materials

Plaster of Paris is relatively brittle, is messy and is very difficult to apply well! It is heavy and awkward particularly for an elderly person and, as it takes up to three days to dry, it can be very inconvenient. For these reasons stronger and lighter new materials have been developed.

These are based on glass fibers and polyurethane resin combinations. They are not so versatile as plaster of Paris and so are used as secondary casts a week or two after the injury, once swelling has settled. They make ideal cast braces (Figure 20).



https://www2.aofoundation.org/wps/portal/ut/p/a0/04_Sj9CPykssy0xPLMnMz0vMAfGjzOKN_A0M3D2D Dbz9_UMMDRyDXQ3dw9wMDAwCTfULsh0VAXc5EIM!/?basicTechnique=Fracture%20management%20with%20limited%20resources&bone=Tibia&segment=Shaft&showPage=redfix

FIGURE. DIAGRAM OF A SIMPLE CAST BRACE WITH HINGED KNEE AND FIXED FOOT.

7.5.2 EXTERNAL FIXATION

High energy fractures are associated with extensive soft tissue damage, which often results in breaching of the skin or even loss of soft tissue. In such cases, because the blood supply is severely damaged, it is important to have an initial phase of soft tissue healing. This means that plaster splints are highly unsuitable because the wounds become inaccessible. Internal fixation is hazardous because of ischemia (lack of blood), and wound contamination increases the risk of an infection being introduced during surgery.

For these reasons a compromise must be sought. A device which is fixed to the bones by pins and which stabilizes the limb by means of an external scaffold, has attractions. Such a device (Figure 21) provides stability of the bones and allows access to the soft tissues for dressings and secondary surgery such as skin grafting.

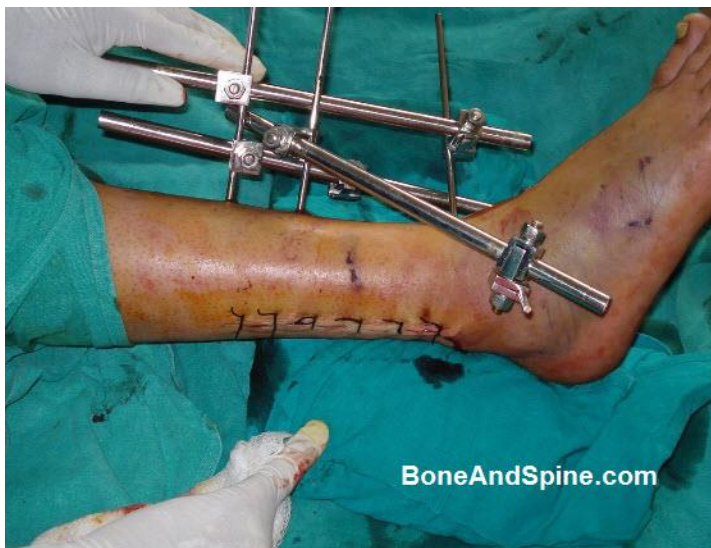

FIGURE. TYPICAL EXTERNAL FIXATOR ON A TIBIAL FRACTURE.

Initially, external fixators were designed to be removed once the soft tissues healed and fracture treatment continued by other means. It is possible to go on to treat the fracture definitively with a fixator, particularly if the fixator can be adjusted in the later stages to permit some movement at the fracture site. However, there are still problems, particularly with the pin sites which are an easy route for infection, a common and often problematic complication.

7.5.3 Internal fixation

Where a high degree of accuracy is required, or other methods fail, internal fixation of fractures is generally used. Internal fixation involves the holding of the fractured bone with devices such as screws, nails or plates.

To the beginner the question must come "why not internally fix all fractures?" This will be discussed at length below. Suffice it to say at this stage that internal fixation of fractures is technically very demanding, it has many complications and, most important of all, it prevents natural healing.

If internal fixation is to be used it can be achieved in a number of ways:

- ◆ Apposition
- ◆ Interfragmentary compression
- ◆ Interfragmentary compression plus onlay device
- ◆ Inlay device

Apposition

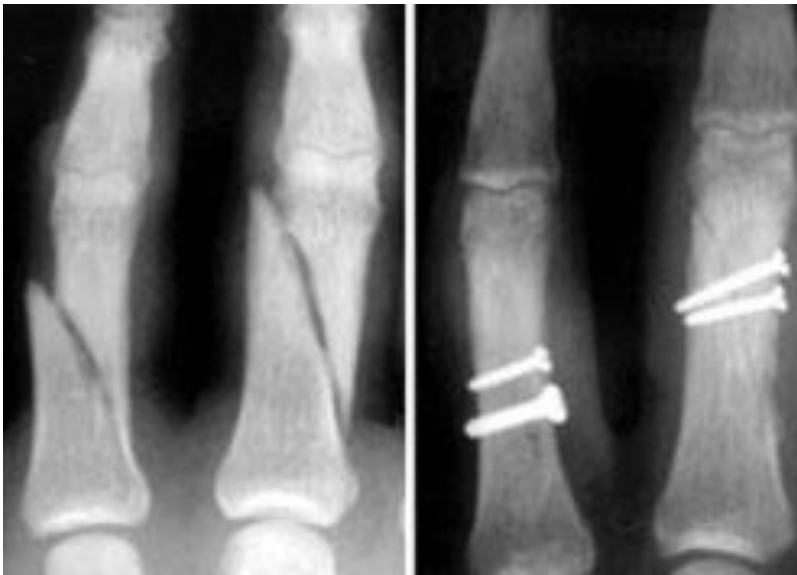
Once fractures are realigned they may only need to be held in apposition (i.e.. together in alignment) for healing to proceed satisfactorily. This is particularly true in children, and can be achieved simply by using semi-flexible wires known as K or Kirschner wires (see Figure 22). They hold position without producing immobility and so healing occurs by natural callus formation. They can be left standing proud of the bone and so can easily be pulled out once union is established and before consolidation.

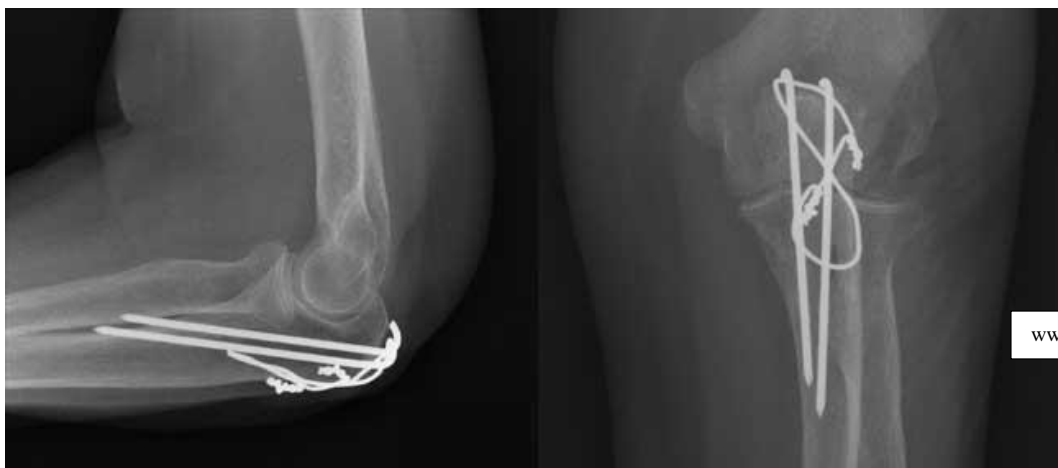

FIGURE. FRACTURE AROUND THE ELBOW IN A CHILD BEFORE AND AFTER FIXATION WITH "K" WIRES.

Interfragmentary compression

This consists of holding two bone fragments firmly together. Interfragmentary compression is usually achieved by screws (Figure 23) or occasionally by tension band wires.



<http://orthoinfo.aaos.org/topic.cfm?topic=A00010>

FIGURE ABOVE. A SCREW BEING USED TO COMPRESS FRACTURE FRAGMENTS TOGETHER.

These achieve great accuracy and are particularly valuable in cancellous bone around joints. They are also useful in long bones, particularly in the upper limb but in these situations extra support is required from an onlay device.

Onlay devices

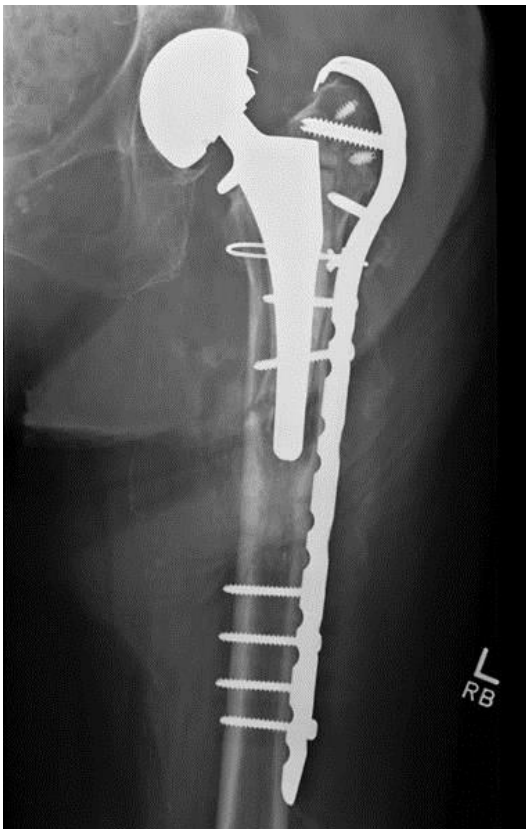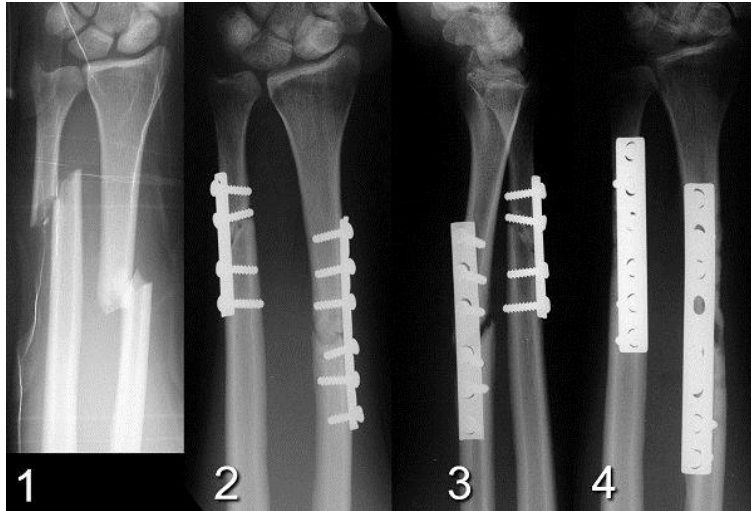


FIGURE. A PLATE COMBINED WITH INTERFRAGMENTARY SCREWS TO GIVE RIGID FIXATION.

<http://achesandjoints.org/2010/12/07/femur-fractures-around-hip-implants/>

Onlay devices usually consist of a plate of metal (although less rigid carbon fibre or plastic plates are undergoing clinical trials). Plates are used to buttress weak structures around joints and to fix long bones in the upper limb, as shown in Figure 24. They may be used in the lower limb but they are generally not strong and certainly should not be used in the lower limb without interfragmentary compression. These very rigid systems inhibit natural bone union and, although they permit early movement of the whole leg, they ultimately delay healing and full load bearing because they inhibit natural healing by eliminating micro-movement at the fracture site.

Inlay devices



<http://www.eatonhand.com/complic/figures/1360603x.htm>

FIGURE ABOVE. EXAMPLES OF THE USE OF INTRAMEDULLARY NAILS, WITH AND WITHOUT CROSS LOCKING SCREWS.

Intramedullary, or inlay devices, are in many ways the most satisfactory method of fixation. They achieve correct alignment of the broken bones without unduly disturbing natural bone healing. They are a relatively inaccurate method of restoring anatomical position and so are not useful around joints. Their great strength make them ideal devices for treating long bone fractures, particularly in the lower limb.

If fractures are badly comminuted (fragmented) or rotated, then cross screws can be inserted in the bone using an X-ray image intensifier to show the bone and nail during surgery. Such a technique requires great skill and can only be performed where high technology is available.

The removal of implants

Whether internal fixation devices should be removed or not is a controversial issue. Following fixation the bone next to a fixation device is relatively weaker as it shares the load with the fixation device. This is because bone is alive and adapts constantly to loads applied to it. If the plate off-loads the bone then that bone gets thinner than if it were not off-loaded. The adjacent unsupported bone is normal. Thus a boundary is created between normal bone and weak, fixed bone leading to stresses at the abnormal/normal bone interface. In the long term the biological risk from implants is unknown. There are a number of disturbing reports of bone tumours arising around implants late after implantation. This is not surprising when one considers the free ions and radicals likely to be emitted from bone implants. It is probably safer therefore to remove implants in young people, although there are risks involved in this procedure. Removal of a plate from scarred wounds is by no means easy and complications, such as infection and damage to nerves and blood vessels, may arise.

7.5.4 Traction

We have already discussed traction as a method of reduction of fractures but the term may also be applied to a technique for holding a reduced position. The common use of the term traction is unfortunate as there are only superficial similarities in its use in the two situations.

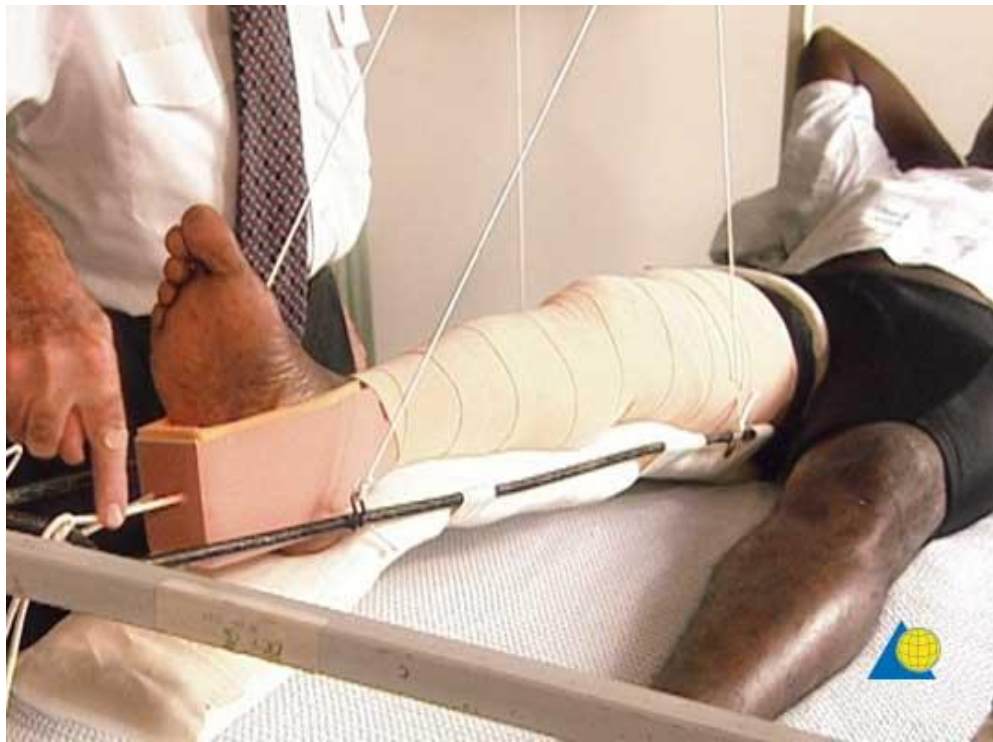Using traction as a holding device involves the application of a relatively small weight to a limb, which exerts a pull along the axis of the broken limb. This pull of at most 5 kilograms stimulates muscles to contract. Muscles completely surround a bone, and this slight contraction (which is really an increase in muscle tone), is sufficient to hold a broken bone in the position achieved at reduction. Therefore traction in this situation is a holding and moulding device as the muscles effectively "massage" the aligned fracture ends until natural healing takes place. This is in direct contrast to traction in reduction where a relatively large force is used to overcome muscle resistance to achieve alignment.

In practice traction can be applied in a number of ways:

- ◆ static
- ◆ dynamic
- ◆ balanced

Static traction

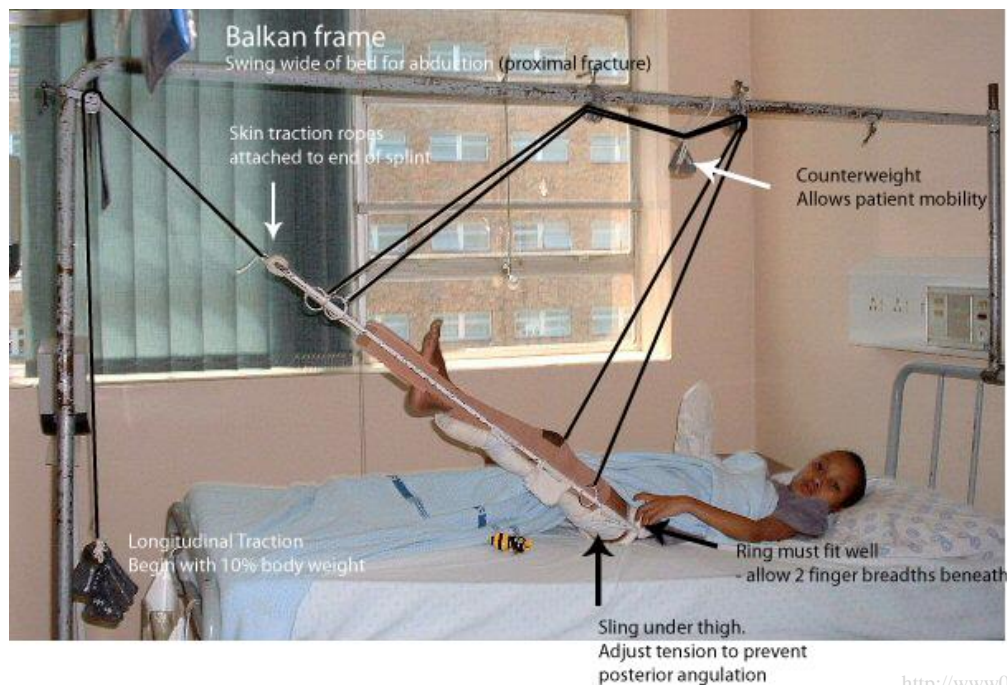
Static traction is used for relatively short periods where the pull is applied against another part of the body. In the Thomas splint (Figure 26), the pull is applied against the ring which presses against the pelvis.



https://www2.aofoundation.org/wps/portal/tut/p/a0/04_Sj9CPykssy0xPLMnMz0vMAfGjzOKN_A0M3D2DDbz9_UMMDRyDXQ3dw9wMDAzMjfULsh0VAbWjLW0!/?bone=Femur&classification=32-C2&method=Temporary%20Thomas%20splint&segment=Shaft&showPage=redfix&treatment=Non%20operative

Balanced traction

Balanced traction is used where static traction is in danger of causing damage to a part of the body through pressure. Here the pull against the ring (and thus the pelvis) is balanced by a weight attached to the whole splint. This takes the pressure off the skin round the ring while maintaining traction on the leg (Figure below).



<http://www0.sun.ac.za/ortho/webct-ortho/general/trac/ThomasTraction-child.png>

FIGURE A PULL IS MOUNTED ACROSS THE FRACTURE OF THE FEMUR USING THE THOMAS SPLINT.

Dynamic traction

Dynamic traction is used where joints are still permitted to move but, by means of pulleys, the pull is still maintained along the line of the broken bone. In this case weights provide the pull and the counter force is achieved by tilting the bed.

Traction may be applied using strapping stuck onto the skin. The weights used are not large and are applied only for short periods of time (a few days). This is particularly useful when traction is being used to relieve pain, such as following a fracture of the femoral neck. This technique results in a change in muscle tone, relieving muscle spasm and diminishing the need for pain-killing drugs.

For long term traction, requiring larger weights, a pin inserted through the bone is preferable and in the long run easier to manage. Pins can be problematical if they loosen, and/or if they become infected. Regular nursing care of pin tracts is essential to keep them clean and dry.

Traction, apart from being a short term pain relieving measure, is useful where other external treatment methods are problematic. It is frequently used for treatment of fractures of the femur where splintage to include the hip joint, although not difficult, is rather impractical, especially in the adult. It is also useful as an alternative to external fixation when there is a large degree of soft tissue damage. The main problem with traction is that the injured person must remain in bed, making hospital stay prolonged and nursing care difficult.

8. HOW FRACTURES HEAL

Bone tissue can be regenerated after injury, unlike other connective tissues which heal with fibrous tissue, forming a scar. This remarkable process remains poorly understood but we can glean enough information to help us in planning and understanding the various treatment regimens described above. The process of bone healing is outlined in Figure 29.

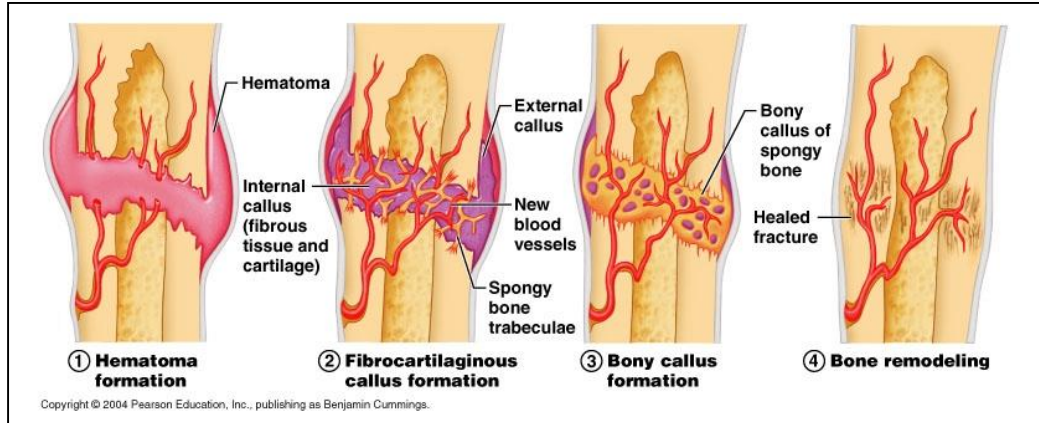


FIGURE. A DIAGRAMMATIC REPRESENTATION OF THE HEALING PROCESS OF FRACTURED BONE.

http://www.apsbiology.org/anatomy/2010/2010_Exam_Reviews/Exam_2_Review/Ch_6_Bone_Fractures.htm

Bones heal in the presence of some movement. This is clear from the example of broken ribs which unite efficiently (albeit painfully) with prodigious external callus formation. It appears that movement stimulates union but the movement must be small and only in certain directions. Bones are stimulated to heal by micro movement directed along the long axis of the bone at right angles to the break. They heal least efficiently if subjected to shearing forces or large movements.

The converse also holds true. Although bones will heal if there is no movement, they do so very slowly and by a different process which does not involve natural external callus formation. This method of fracture healing is also not fully understood.

All bone healing is highly dependent on a good blood supply and so we again come to appreciate the importance of the surrounding soft tissues and of the essential need to respect bone as a living, as well as a structurally important, material.

Bearing these points in mind we can conclude that bones which are allowed to heal with optimal movement will do so efficiently and with no long term adverse consequences, provided alignment may be maintained. However, if bones are fixed rigidly (using internal fixation techniques) then they will unite in accurate alignment (provided the surgeon has been able to be accurate!), but will do so slowly. This will be most marked in long bones and less problematical in cancellous bone, which tends to heal fairly quickly.

9. A PRACTICAL GUIDE TO FRACTURE MANAGEMENT

If we bear the factors already outlined in mind, we are now equipped to understand a more pragmatic approach to treating fractures. Remember that the aim of the orthopaedic management team is to return the individual to their pre-injury level of function by the safest available means.

9.1 Low Energy Injuries

Fortunately most fractures to the shafts of long bones are caused by a low velocity impact with relatively little soft tissue damage and correspondingly greater fracture stability. These injuries can be treated by manipulation and casting (Figures 29A, 29B and 29C), provided that holding is possible. If holding is a difficulty, such as in the femur for example, then traction may be used. Other methods of holding include functional bracing and internal fixation. Internal fixation may be justified if this leads to early mobilization of the injured person. If the risk of operation is low, such as in young people and the fit middle-aged, or the benefit is high, as in the elderly, then fixation by an experienced surgeon is generally justified.

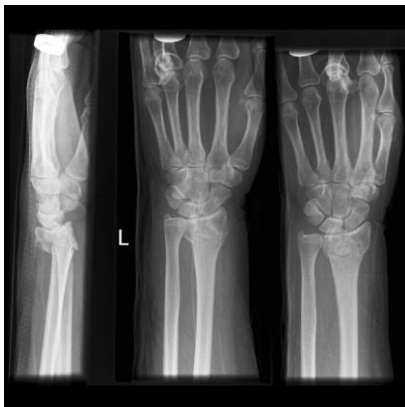
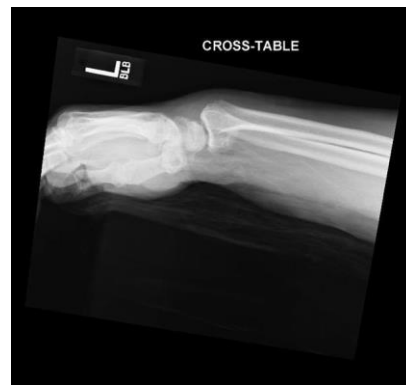
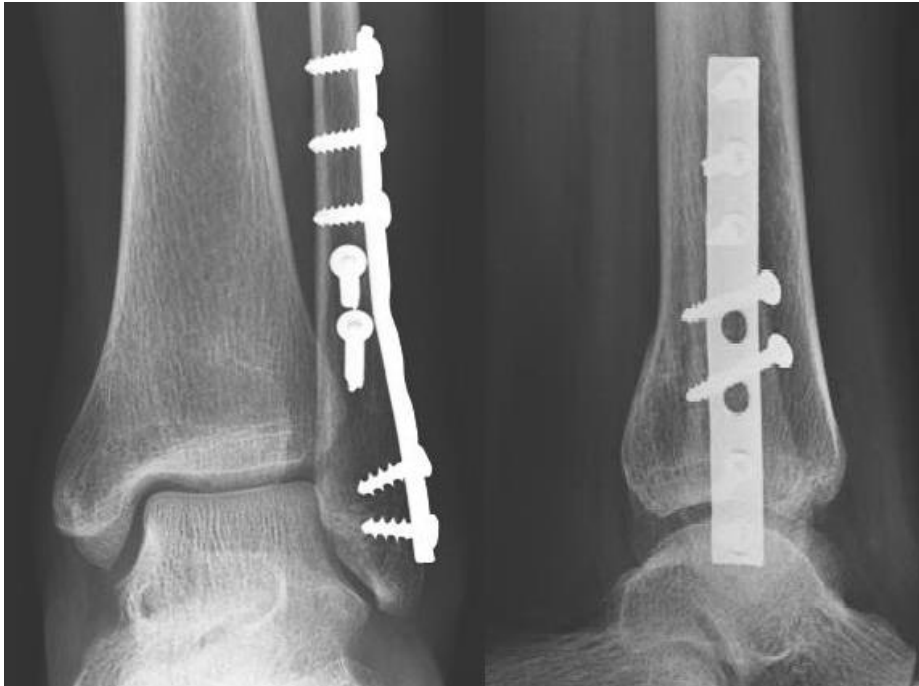FIGURE. A TYPICAL WRIST FRACTURES



9.2 Fractures Involving Joints

If fractures involve joints then, generally internal fixation is appropriate if the fracture is displaced. Reduction to the degree of accuracy required for intra-articular fractures is unusual without an operation. Around joints, where cancellous bone tends to be fragmented and often with little soft tissue support, holding requires accurate reconstruction of the fragments, usually with screws to aid stability (Figure below).



www.ocpodiatry.com

FIGURE ABOVE. TYPICAL ANKLE FRACTURES HELD USING INTERNAL FIXATION TECHNIQUES.

9.3 High Velocity Injuries

High velocity fractures, whether open or closed, require special attention because of the damage to the blood supply. They are fortunately few, but are the most challenging and ideally should be treated by experienced clinicians. They require early attention, followed by expert decisions about definitive management. External fixators are particularly valuable in mis-type of injury, as outlined above, although fixation, traction and splintage all have their place. A more detailed discussion of the management of these injuries is beyond the scope of this unit.

9.4 The Injured Person

Fractures should be held using fixation if it is of benefit to the injured person. This is particularly so in the elderly, where fixation will relieve pain and permit early mobility so preventing some of the complications caused by immobility including bedsores, chest and urinary infections and muscle wasting. For similar reasons pathological fractures should be fixed. Pathological fractures occur when a bone subjected to normal forces behaves abnormally by fracturing.

This is seen with examples following a bone tumor (a common secondary tumor to malignant tumors of the lung, breast, thyroid and kidney). Fixation of fractures in such circumstances, followed by radiotherapy will lead to bone healing but, more importantly, pain relief and early return home.

9.5 Choices

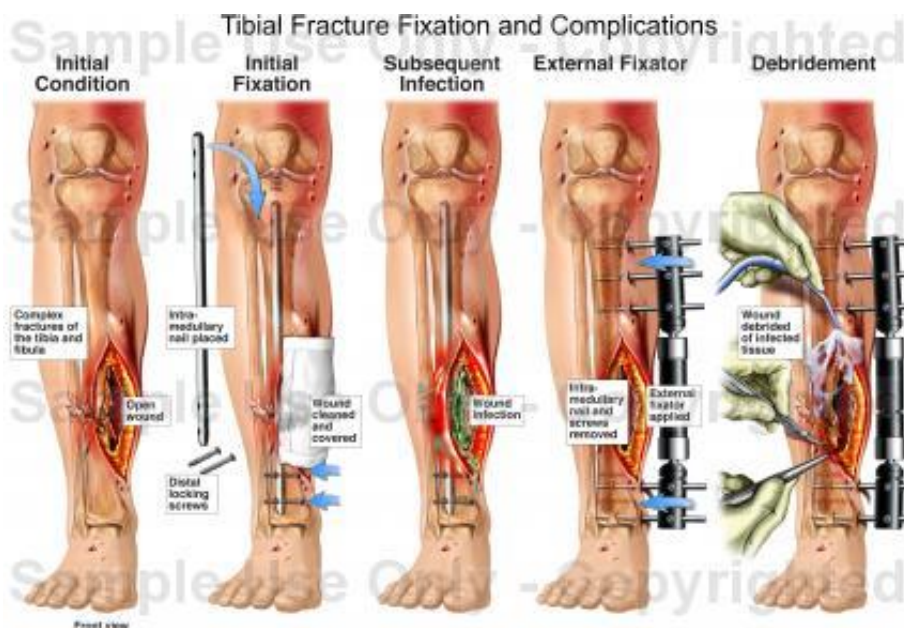
Finally there are occasions when fractures may be fixed at the specific request of the injured person. Internal fixation leads to early mobility, but slow healing, and a second operation may be necessary to remove the metalwork. However, early mobility may be of vital importance for some individuals in certain circumstances. Imagine, as you read this, what would happen if you broke your femur playing sport next weekend just before an important wedding or an exam! Early internal fixation would of course be beneficial, although the risks outlined above would still exist. If the surgeon is experienced and skilled and the facilities are excellent, then internal fixation is acceptable provided the injured person is properly informed and can give full consideration to the issues.

10. COMPLICATIONS OF FRACTURES

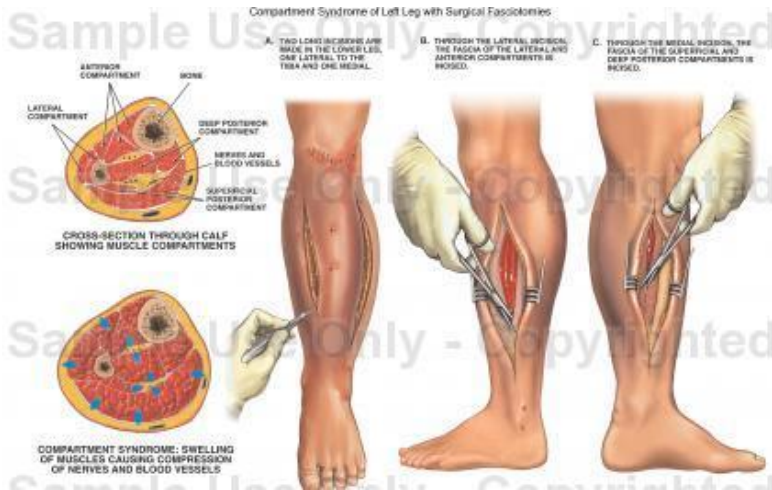
10.1 Introduction

Although this section is called "complications" a better title might be "consequences" as some factors such as blood loss and soft tissue bruising are inevitable consequences of an injury resulting in a fracture. However, by anticipating the consequences such as blood loss, for example by transfusion, serious problems can be prevented.

Complications may occur soon after the injury (early complications) as a consequence of the injury (primary). Some early problems may be associated with the treatment of the injury (secondary). Late complications are generally due to the fracture but a few are unfortunately precipitated by the treatment, or lack of it. The complications are listed below.



Compartment syndrome



<https://www.studyblue.com/notes/n/patho-exam-4-compartment-syndrome-venous-thrombo/deck/6454339>

10.2 Infection

Infection may occur after open fractures or after internal fixation: it is notable that the commonest cause of bone infection in the western world is surgery! Although infection may delay or prevent union this is not always inevitable. Provided a fracture is held stable then it will unite despite infection. If there is infection and movement then nonunion is most likely. This phenomenon is ill-understood but suffice it to say that if a fixed fracture is infected then, provided it is stable, it may be temporarily treated by drainage of any pus collection and by antibiotics until union has occurred.

If an open fracture that is not stable, or an unstable but fixed fracture, becomes infected then stabilization by external fixation followed by surgical wound cleansing and later bone grafting will be required.

10.3 Fat Embolism

The cause of fat embolism remains unclear. It was originally said to be due to the precipitation of marrow fat in the lungs. The breakdown of fats to fatty acids is said to precipitate an inflammation of the lungs (pneumonitis). However, the condition seems part of a more generalized abnormal response to injury. It is not common, but is found typically after the fracture of a long bone in men under twenty. The symptoms usually commence within two to five days from injury and may initially simply present as rapid and shallow breathing (tachypnea) and mild confusion. The injured person may have a rash on the chest and neck but this is by no means universal. Early diagnosis is highly dependent on the clinician's awareness of this complication and on the carrying out of appropriate investigations.

In severe cases the respiratory distress increases to the point where ventilation is required, but even with this support, the condition carries a significant mortality. Unfortunately and most distressingly, younger men are more prone to the full blown condition and fatalities do occur. Early diagnosis followed by treatment with high percentage oxygen and chest physiotherapy reduces the consequences, but late diagnosis is less than helpful. Steroids given early or even prophylactically are said to reduce the severity but this remains controversial.

10.4 Renal Failure

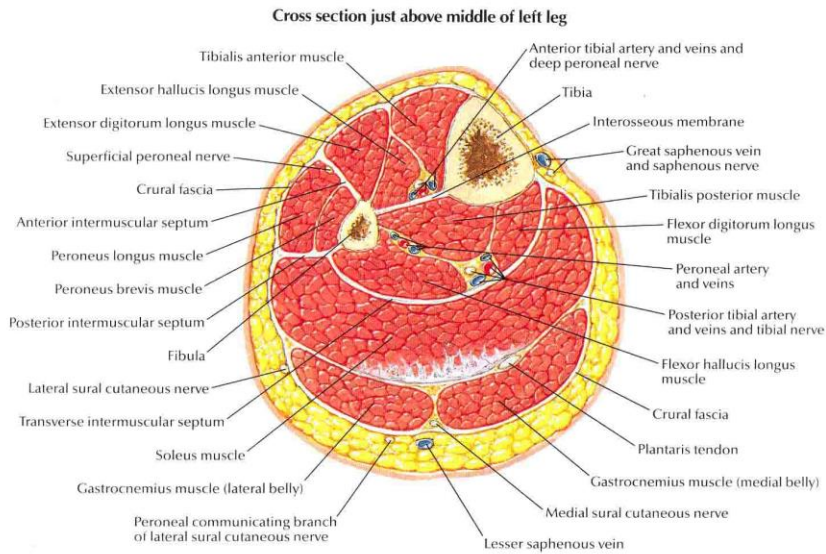
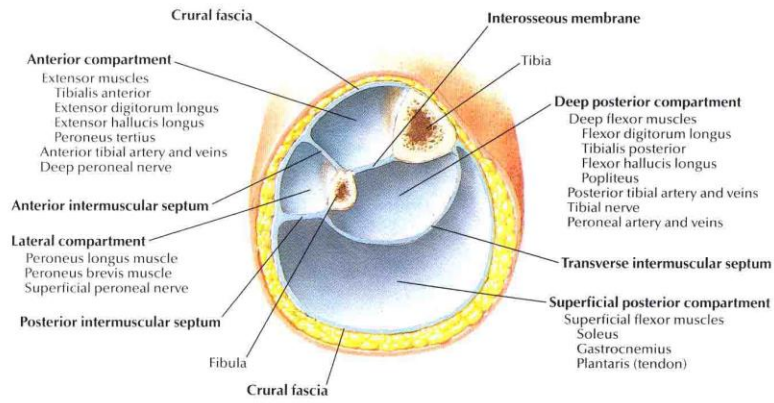
People with massive soft tissue injury who are trapped for prolonged periods, particularly where they are shocked or the trapped limbs are relatively starved of blood (ischemic), are prone to develop kidney failure. Myoglobin, which is the oxygen carrying material in muscle, is found in abundance in the kidneys of people who die from mis set of circumstances. The reason for this is unknown.

10.5 Compartment Syndrome

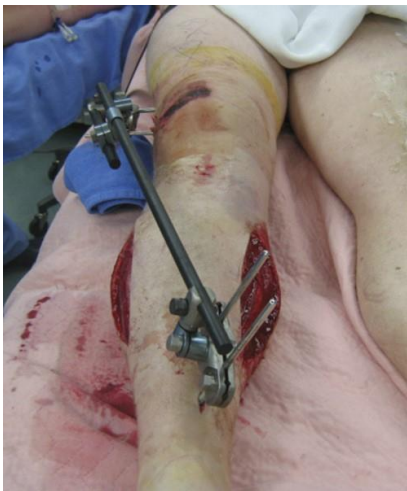Sometimes referred to as Volkmann's ischemia, this condition can occur in the upper or lower limbs following a fracture with excessive localized soft tissue swelling. Classically occurring in the forearm, it may also occur in the calf.

All muscles are surrounded by tough fibrous tissue called fascia. Groups of muscles are surrounded by a thicker layer of fibrous tissue (the fascial sheath). This sheath supports the muscles and gives them shape as well as anchoring them to bone and surrounding soft tissues.

The fascial sheaths act as boundaries between groups of muscles, creating isolated compartments containing muscles, blood vessels and nerves. If a bone is broken then bleeding will occur into the adjacent compartments and there will also be swelling from the inflammatory reaction. Both these factors lead to an increase in pressure within the compartment. Rises in pressure may reduce blood flow locally to the muscles. The reduced local muscle blood supply results in ischaemia. It is not understood why this only happens occasionally but it appears to be related to severity of injury. Rarely, compartment syndromes can occur without fracture and they can also be precipitated in association with exercise - for example shin splints. "Shin splints" is the term used to describe the often agonizing pain some athletes get in their shins when they run, often early in a training schedule. Why chronic shin splints occur is not fully understood.



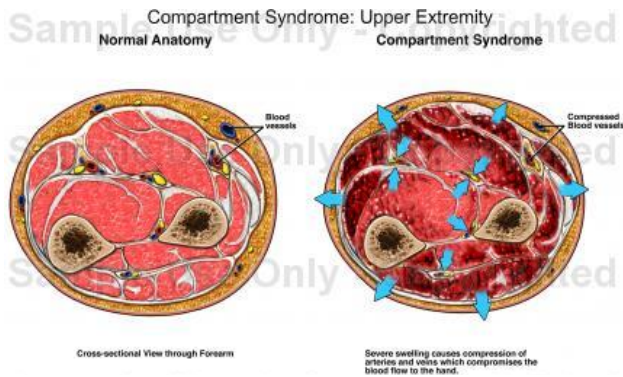
<http://woningzoeker.iproductfinder.com/beelden/Leg%20Anatomy%20Cross%20Section>



<http://z0mbie.host.sk/Tibial-Plateau-Fractures.html>

The injured person with compartment syndrome experiences pain which is out of proportion to

that expected by the injury. There is also associated loss of function of the muscles and often altered sensation over the compartment. Paradoxically, the pulse distal to the compartment is normal and the examiner may be lulled into a false sense of security. A useful diagnostic test is to stretch the muscles in the compartment, such as extending the fingers or toes. This usually precipitates extreme pain and is an indication to intervene as follows:



<http://www.passenlaw.com/failure-diagnose-compartment-syndrome/>

All dressings should be removed and plasters split to the skin and eased - this will not affect the splintage properties of the plaster. If this fails then surgical intervention (opening the fascia to decompress the compartment) is inevitable. The condition can be prevented by early elevation of the injured limb to prevent swelling occurring, by careful attention to the padding of casts, and by ensuring that dressings are not too tight.

10.6 Immobility

Immobility can result in a variety of problems. After injury the injured part of the body needs to be immobilized for a short period. The whole person does not need immobilizing at any time and people must begin to mobilize and rehabilitate as soon after injury as possible. It is vital that the injured person understands that this is their responsibility, although they will be helped by therapists and medical staff.

Muscle wasting, stiffness and skin sores are often combined under the term "fracture (or sometimes plaster) disease".

Early mobilization will discourage the development of:

- ◆ osteoporosis - the "thinning" of bone caused by disease
- ◆ renal stone formation - caused by calcium from the thinning bone
- ◆ stiffness - caused by disease of joints
- ◆ muscle wasting - caused by muscle disuse
- ◆ skin sores - caused by pressure of the plaster cast

10.7 Delayed and Non-union

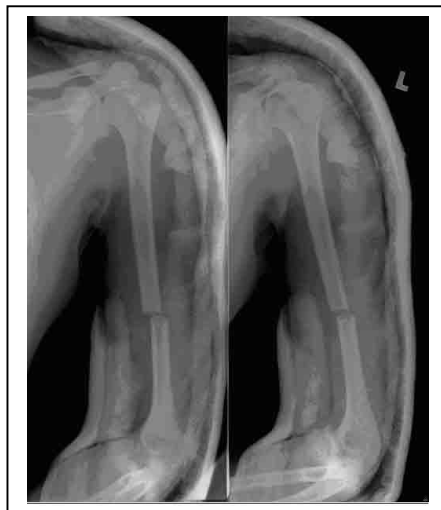About two percent of all fractures go on to non-union and a few more will be delayed as shown in Figure 33. If left to heal naturally, upper limb fractures heal in six weeks or so and lower limb fractures in twelve. This rule of thumb is useful but must not be too strictly adhered to and will be modified depending on the degree of violence involved and how the fracture was treated. It is worth noting that although growing children do heal faster than adults, once growth ceases the rate of union is not age dependent.

Non-union is commonest in the tibia but may occur at any site. The tibia is of course commonly injured, but other factors contribute to non-union, including its rather exposed site under the skin with little surrounding muscle and soft tissue. Why fractures go on to nonunion is not fully understood but some factors which are known to cause it may be listed:

- ◆ Excess movement
- ◆ Too little movement - a result of rigid internal fixation
- ◆ Soft tissue interposition - soft tissue between the bone ends
- ◆ Poor blood supply
- ◆ Infection
- ◆ Excessive traction, or splintage of bones too far apart
- ◆ Intact adjacent bone - e.g. tibia and fibula

Non-union may be said to occur when the injured person and/or the surgeon feels that healing has taken too long. Bearing in mind our rules of thumb for fracture union time, we may say that non-union is established at twenty weeks in the lower limb and ten in the upper. These are arbitrary but practical figures.

Delayed union is even less specific and it is really a period between expected union and accepted non union when the decision to do something is contemplated. The causes are the same as for non-union.



<http://jortho.org/2005/2/1/e2/index.htm>

Treatment for non union relies on removing any underlying cause, and then stimulating union. Stabilizing the fracture sufficiently and then adding a bone graft seems to stimulate union but how this works remains an enigma. The bone used for a graft is usually autologous (taken from the bone, usually the pelvis, of the same individual) and is placed next to the fracture. It appears to be able to "switch on" the hitherto deficient healing mechanism.

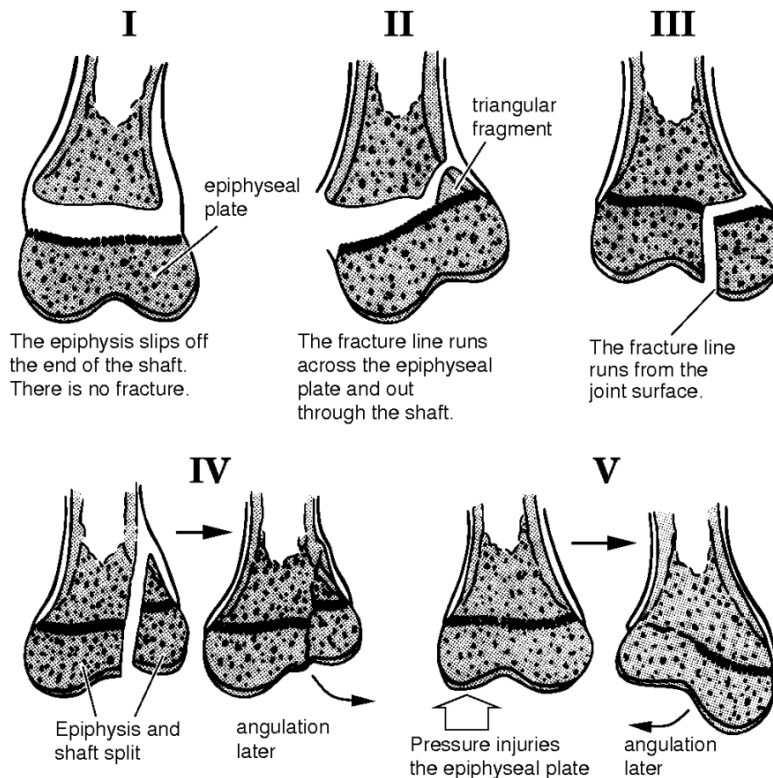
10.8 Mal-union

Mal-union implies that the fracture has been allowed to heal in a position that precludes normal function. It usually implies failure of the treatment method, or neglect by a surgeon, or by non-attendance at out-patient clinics. Regular out-patient review is the mainstay of fracture management and regular radiological and clinical examinations are essential to ensure all is going well. Once recognized, mal-union may be treated by open reduction and internal fixation.

10.9 Growth Arrest

If a fracture breaches the germinal layer of the epiphyseal growth plate (Skeletal Anatomy and Physiology Unit 2), bone growth may be arrested at the point of breach, resulting in deformity. These are rare injuries and difficult to manage. Children have a great capacity to remodel mal-united fractures, although they will not remodel rotary deformities.

EPIPHYSEAL INJURIES



<http://guzhe.baike.com/article-42878.html>

10.10 Arthritis

Arthritis will develop secondary to a fracture if a joint is excessively stressed. This will be likely if a fracture goes across a joint and disturbs the surfaces so that the joint is no longer congruent (i.e.. the two surfaces are no longer parallel). A very angulated fracture will also stress a joint by putting uneven forces on it. Occasionally, direct damage to the articular cartilage will result in arthritis. Good fracture management should minimize, but will never totally exclude, the risk of developing arthritis.

SUMMARY

In this unit we have attempted to give you an overview of some of the principles influencing modern fracture management. The treatment of individual fractures is a subject for discussion elsewhere.

Fractures in different people may look identical, but there are many other factors to consider when deciding which treatment methods to use. A balanced decision must be made after considering the type of fracture, the circumstances of the injury, the injured person's age, health and circumstances and the resources at the disposal of the orthopaedic management team. Injured people suffering an apparently similar fracture may be treated quite differently.

GLOSSARY

periosteum	closed reduction	fat embolism
fracture	open reduction	tachypnoea
history	united	ischaemic
pain	consolidated	kidney failure
deformity	casting	fascial sheath
tenderness	external fixation	compartments
swelling	internal fixation	shin splints
discolouration	plaster of Paris cast	compartment syndrome
bruising	union	fracture disease
loss of function	functional braces	non-union
crepitus	cast brace	delayed union
radiograph	ischaemia	bone graft
tomogram	external fixators	autologous
open fracture	internal fixators	mal-union
closed fracture	apposition	epiphyseal growth plate
spiral fracture	interfragmentary	arthritis
oblique fracture	compression	
transverse fracture	onlay device	
simple fracture	inlay device	
butterfly fracture	static traction	
comminuted fracture	Thomas splint	
pathological fracture	balanced traction	
pain-killers	dynamic traction	
splint	external callus	
traction	micromovement	
osteoporosis	low energy injury	
reduction	intra-articular fractures	
holding	high energy injury	
	early complications	

Orthopedic Medical Assistant Working in the Orthopedic Physician Setting

Unit VI

UNIT 6 – Section Objectives

AIM

The aim of this module is to provide you with information about a number of specialist subjects related to your professional practice in the plaster room.

OBJECTIVES

At the end of this unit you should be able to:

1. Describe the composition of plaster of Paris, polyurethane casting materials and sheet splinting products.
2. Compare and contrast the ways in which splints are constructed using the different materials.
3. Make decisions about when to use the different casting materials.
4. List the hazards and complications of casting.
5. List the procedures which minimize the risks of casting.
6. Describe how compartment syndrome may occur, how it may be prevented and how to initiate treatment.
7. Recognize the direct effects of pressure and describe how to prevent these.
8. List the anatomical areas where pressure effects are most likely to occur.
9. Describe the risks caused by the production of heat in the casting process.
10. List the dangers of removing casts and describe ways of minimizing such risks.
11. List the dangers in changing casts and describe how to anticipate these dangers.
12. Describe how to instigate a sound repair of a damaged cast.
13. List the principles of cast wedging.
14. List the reasons why written records should be kept and list the basic information required to be kept on record.
15. Describe the legal obligations you have to patients and fellow professionals.
16. Communicate essential information to patients both verbally and in writing.
17. List the basic principles of first aid and describe where you may obtain further training.
18. List the range of walking aids available and describe how to fit and measure a patient for an appropriate device.
19. Describe your obligations about acquiring lifting skills.
20. Describe the most efficient lifting methods and explain why these are more efficient than others.

UNIT 6 – Orthopedic Medical Assistant

CONTENTS

1. INTRODUCTION

2. MATERIALS USED IN THE CAST ROOM

- 2.1 History
- 2.2 Plaster of Paris Bandages
- 2.3 Plaster of Paris Casts
- 2.4 Resin Based Casting Materials
- 2.5 Sheet Materials
- 2.6 Other Materials
- 2.7 Indications for Use of the Various Materials

3. COMPLICATIONS AND DANGERS IN PLASTERING

- 3.1 Natural Processes After Injury
- 3.2 Prevention of Complications
- 3.3 The Consequences of Swelling
- 3.4 Compartment Syndrome
- 3.5 Direct Effects of Pressure
- 3.6 The Effects of Heat

4. RISKS IN REMOVAL OF PLASTERS

- 4.1 Cutting
- 4.2 Indenting
- 4.3 Penetration by Instruments
- 4.4 Dust
- 4.5 Noise

5. CHANGING PLASTERS

6. BREAKAGES AND REPAIRS

7. WEDGING TECHNIQUE

8. RECORD KEEPING

- 8.1 Cast Register
- 8.2 Other Records

9. LEGAL OBLIGATIONS TO PATIENTS

10. COMMUNICATING WITH PATIENTS

11. WALKING AIDS

- 11.1 Sticks
- 11.2 Crutches
- 11.3 Frames
- 11.4 Ferruling

12. SAFETY IN THE WORKPLACE

- 12.1 Handling Technique

13. FIRST AID

- 13.1 Calling help
- 13.2 What to do if a patient collapses
- 13.3 ABC
- 13.4 The recovery position
- 13.5 Choking
- 13.6 Fits
- 13.7 Diabetes
- 13.8 Burns and scalds
- 13.9 Electrocutation

Orthopedic Nostalgics in the Cast Room

1. INTRODUCTION

This module describes the aspects of fracture management in a hospital environment that affect you, *the Plaster Technician*, on a day to day basis. It has been written from a practical perspective but it also provides information about the reasons for certain procedures and gives advice about precautions which should be observed in various aspects of your work. Many of the sections, such as those on safety and First Aid, are not intended to be comprehensive but cover the basics. Practical instruction in these topics should be sought from qualified instructors. This is available either through local colleges, voluntary bodies, or within existing educational courses in the institution in which you work. You may get help from the Nursing Officer in Orthopaedics or in Accident and Emergency. You could also make enquiries in the department dealing with staff development and in-service training in your hospital.

2. MATERIALS USED IN THE PLASTER ROOM

2.1 History

Over the centuries, many materials have been used to form casts. In hot countries, such as Egypt and Persia, splints were fashioned from clay and sticks, or egg white and lime. Specimens have been found in the mummies of accident victims who were interred with their splints in place. In Europe wooden splints were used, often associated with strips of cloth known as clouts. The intertwining of these clouts was known as clouting and could produce very supportive splints.

Plaster of Paris, which will be described in detail later, was not used until the nineteenth century. A Dutch army surgeon, Antoninus Matysen, was the first to combine plaster of Paris with a bandage. Commercial plaster bandages were originally produced in Germany around 1910, and these were the first to resemble the modern plaster bandages used today. Commercial products were not made in the UK until 1949 and materials such as thermoplastics were first introduced in the 1970s.

It can therefore be seen that the casting materials in use today to treat fractures are relatively modern. Casting techniques continue to develop as the technology advances.

2.2 Plaster of Paris Bandages

Plaster of Paris is a natural material - **calcium sulphate** - which was first found in a mine near Paris at Montmartre. It is extracted in crystal form and heated to remove water, producing an almost water-free, powdery compound known as **calcium sulphate hemihydrate (Ca SO₄ · ½H₂O)**. If this compound is mixed with water it forms crystals again and "sets" to a solid. This process results in considerable heat production. The more calcium sulphate hemihydrate there is in the bandage, the more heat is produced. Therefore, when using plaster of Paris to form a cast, there is a real risk that the heat can cause damage to patients if care is not taken.

Commercial plaster bandages are made by dissolving calcium sulphate hemihydrate in an organic solvent, such as ether, which contains no water. Starch is added to this mixture and the whole paste is spread on a cotton bandage. This wet bandage is then dried and the solvent collected for re-use. The bandage is therefore coated with calcium sulphate 'held on' by starch. This is known as a **hard coated bandage**.

An old method, as described by Matysen and used until relatively recently, was simply to dust calcium sulphate hemihydrate onto a bandage so that there was a weak association between bandage and plaster. A skilled user could use these to make good casts, but much of the plaster was lost. This type of bandage was known as a loose **coated bandage**.

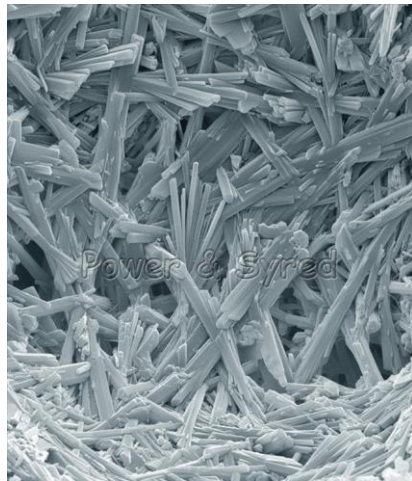
2.3 Plaster of Paris Casts

A plaster of Paris cast is made using cotton bandages, hard-coated with crystals of calcium sulphate hemihydrate as described above. The bandage adds little to the strength but provides a vehicle for getting the wet plaster on to the part to be splinted. It consists of cotton thread

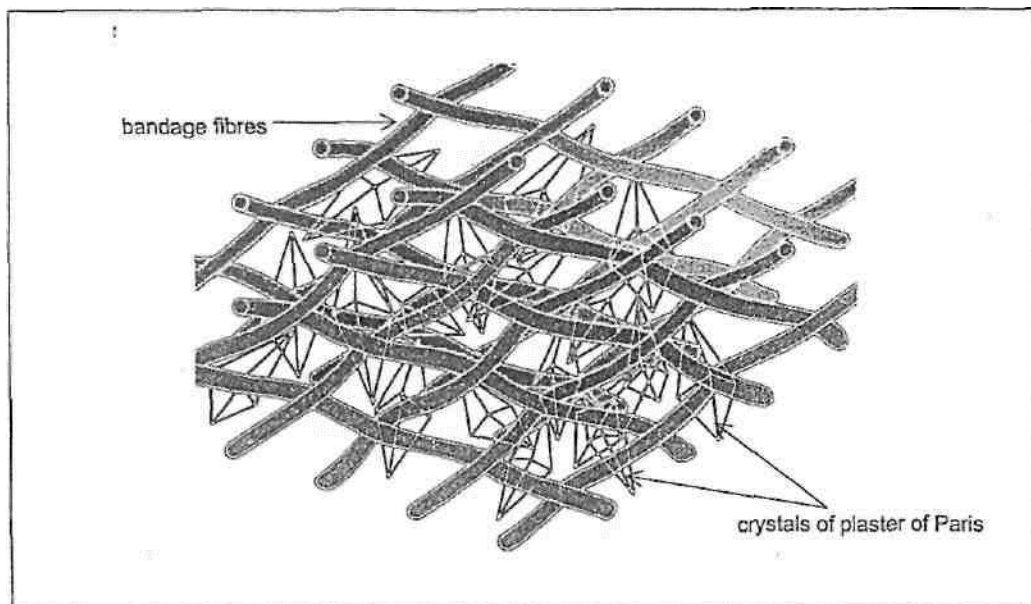
which may be double woven to prevent it fraying (known as leno cloth). The starch which sticks the plaster of Paris to the cloth adds nothing to the strength of the cast but it does influence the speed of the setting by speeding up the chemical reaction - it is an accelerator. Manufacturers can vary the setting time by altering the amount of starch. Other materials can be added to slow down setting. These are called retarders and common examples of these are alum and borax. The temperature of the water used to wet the bandage also influences the setting time of plaster of Paris. Professionals in different countries prefer different setting times.

The plaster of Paris itself is made up of two types of crystals. Some are long and sharp and others are shorter. The long crystals occur naturally as alabaster. They give a finished cast a hard quality. The smaller crystals give the cast a softer feel. Experiments have shown that commercially available casting materials, which differ in their proportions of the two crystal types, have similar strengths. However, professionals can tell the difference in the wet and finished qualities of the differing casting materials.

The properties of the material making up the final splint are largely dependent on the physical interlocking of the two types of crystal.



www.psmicrographs.co.uk



This interlocking will be influenced by how wet the plaster material is at the time of application. Ideally just enough water should be present to completely crystallize the calcium sulphate hemihydrate. However this would be insufficient to make the material workable, as it would only be vaguely damp! The amount of water required to make a plaster bandage workable means that excess water must evaporate before the cast is strong enough to bear weight. This may take up to two days in a typical cast. This inevitable weakening of a plaster cast is unfortunately necessary to give plaster that versatility of application which makes it such a useful material.

2.4 Resin Based Casting Materials

Many newer commercial casting bandages or tapes consist of **glass fiber** or other artificial fiber bandages in association with polyurethane resins.

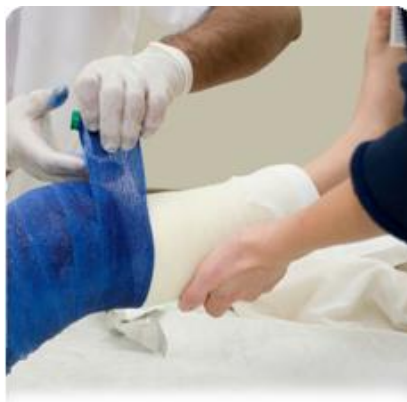When exposed to heat and moisture, **urethane monomer** molecules polymerize (combine) to form **polyurethane**. This chemical reaction also produces heat. There are very strong chemical links between the polymerized urethane molecules in polyurethane. The strength of polyurethane resins is considerably greater than that of plaster of Paris because of these chemical links.

The bandage consists of a woven net of glass fiber or another textile, such as **terylene or polypropylene**. The bandage adds considerably to the structure of a cast because it is intimately physically linked with the polyurethane resin.

The combination of polyurethane resin and bandage has properties of strength and flexibility which are better than either the bandage or the resin alone. Materials, which in combination produce such favorable properties, are known as composites.



<http://www.alibaba.com/showroom/medical-fiber-bandage.html>



www.ecvv.com

The disadvantage of polyurethane bandages is that the resin does not move around relative to the bandage in the same way as plaster of Paris does. This means that the way the bandage is laid on the limb to make the splint is very important and there is no scope for moving resin about to compensate for poor siting of the bandage.

The advantage of composite polyurethane bandages are that they are light, flexible and very strong.

2.5 Sheet Materials

An alternative way of constructing a splint is to make it from a rigid sheet which may be cut to shape and then made malleable by heating before being moulded to the limb and allowed to set.

Commercially available sheet materials either consist of polycaprolactones or isoprene rubbers. These materials are chosen because they are strong enough to form a splint at thicknesses practical to handle and they have low melting points so that they can be applied to the body for moulding without risk of causing burns. The advantage of these materials are that they can be used to make more complicated splints (e.g. for fingers and hands) or to construct functional braces.

The disadvantages of these materials are that they are difficult to work with and require the part of the body to be stable during setting and construction of the splint. This makes them unsuitable for fresh fractures which tend to be wobbly. These materials are also very expensive.

Materials with a higher melting point are available (**polyethylene** and **polypropylene**). These materials are largely used to make longer lasting splints for those with chronic disability and have

no place in fracture care, except in very rare cases such as a non-union.

2.6 Other Materials

There are a number of new commercially available splinting materials. These include foams which can be sprayed on or applied to the limb in stocking shaped bags. These materials tend to be used for specialised situations, such as spinal jackets or where a longer term removable splint is required. Many of these materials do not tolerate much bending.

2.7 Indications for use of the Various Materials

2.7.1 Casting new fractures

Fresh fractures are associated with pain and swelling and may be unstable. Often the first cast applied may be temporary and will be replaced once any swelling has gone. It may also be necessary to manipulate a fracture back to an anatomically acceptable position which will restore function - **reduce it** - and the splinting material needs to be versatile to fit around the manipulated limb in order to hold it in the reduced position. In this situation plaster of Paris has the advantage of ease and versatility of application and is inexpensive for making a temporary splint.

Polyurethane resin casts may be used for more stable fractures where there is little swelling (e.g. in young people and the elderly). Young people tend to need hard wearing casts and so the extra strength properties of polyurethanes may be beneficial. In the elderly, the lightweight properties are useful in helping them to stay mobile.

2.7.2 Casting fractures after a few days

Once swelling has settled then there is a greater choice of material for a second cast. Expense is a genuine consideration and the benefits of using a more expensive material must be justifiable. Stronger casts need less attention and repair and so this may justify the use of more expensive polyurethane resin casts. The patient may also benefit from the strength and lightweight properties as described above.

2.7.3 Other uses

It is more important to appreciate the extra scope polyurethane resins give for casting techniques. For example, because they are very strong they are excellent for constructing functional braces and they interface very well with hinges. They are also flexible, so the splint may be opened and closed without cracking. They can be interfaced with Velcro and other fastening materials making them useful for removable splints, such as back supports.

Polyurethane resin casts may be used for more stable fractures where there is little swelling (e.g. in young people and the elderly). Young people tend to need hard wearing casts and so the extra strength properties of polyurethanes may be beneficial. In the elderly, the lightweight properties are useful in helping them to stay mobile.

2.7.2 Casting fractures after a few days

Once swelling has settled then there is a greater choice of material for a second cast. Expense is a genuine consideration and the benefits of using a more expensive material must be justifiable. Stronger casts need less attention and repair and so this may justify the use of more expensive polyurethane resin casts. The patient may also benefit from the strength and lightweight properties as described above.

2.7.3 Other uses

It is more important to appreciate the extra scope polyurethane resins give for casting techniques. For example, because they are very strong they are excellent for constructing functional braces and they interface very well with hinges. They are also flexible, so the splint may be opened and closed without cracking. They can be interfaced with Velcro and other fastening materials making them useful for removable splints, such as back supports.

3. COMPLICATIONS AND DANGERS IN PLASTERING/ fiberglass

Encasing a limb in a rigid support is hazardous even if the limb is healthy. Immobilization is an unnatural state and so care is required if the patient is not to be put at unnecessary risk. If the limb is injured and subject to inflammation and swelling then the risks are greater. Patients cannot be expected to understand how hazardous splintage is and so the technician has a duty to provide care and protection and to communicate the dangers to the patient. No knowledge can be assumed on behalf of the patient. This section is designed to ensure that you understand the risks.

3.1 Natural Processes After Injury

Acute inflammation is a natural event after injury and results in:

- ◆ Increased blood supply
- ◆ Swelling (as a result of increased blood vessel permeability)
- ◆ Pain

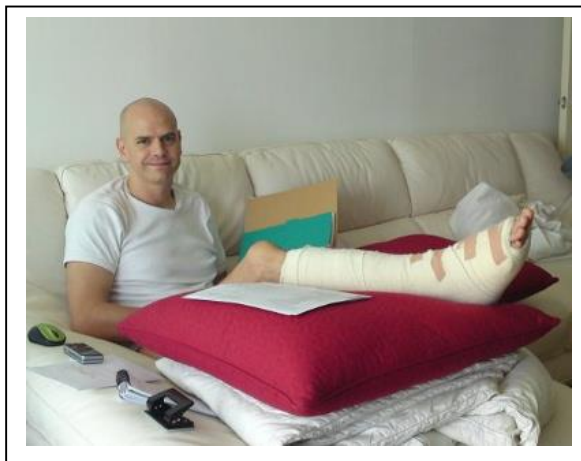The breaking of a bone or severe injury to soft tissues will stimulate this reaction whatever the carer does. However, the effects of acute inflammation can be reduced if appropriate care is given.

3.2 Prevention of Complications

We cannot prevent acute inflammation. However, we can reduce its effects by elevating the affected part of the body. For example, if the hand is held above the head for a few minutes we can feel the fingers tingle and become weaker. This is because the blood supply is reduced as the blood has to be pumped "uphill". If an injured part is elevated as much as possible above the heart, then an increase in blood flow is minimized, reducing swelling.



<http://suppliescentral.blogspot.com/>



<http://www.gfilotto.com/experiments/achilles-tendon-recovery-from-surgery-diary>

3.3 The Consequences of Swelling

If swelling is ignored, then it makes the soft tissues "hard" in the short term, and delays healing.

In the long term, swelling may lead to excessive scarring which is probably caused by the prevention of return to normal blood flow during the healing process. The effects of this are stiffness and loss of function of the affected part, resulting in a delay in the rehabilitation of the whole patient.

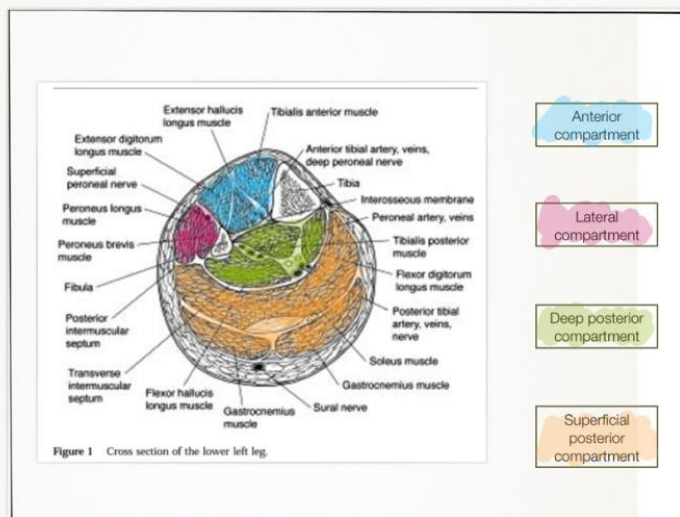
Early treatment of injury is therefore a balance between reducing the effects of the increased blood supply caused by inflammation, and encouraging the return of normal blood circulation as soon as possible.

3.4 Compartment Syndrome

One serious effect of injury is related to the natural consequences of acute inflammation and swelling. This is known as **compartment syndrome**. This is also described in the module on Trauma - section 10.5.

When muscles in a compartment are injured they bleed and swell naturally as described above. Generally the increased volume of the fluid and blood can be accommodated in the compartment through a modest expansion and a slight increase in pressure. However, if bleeding and swelling are excessive, the compartment cannot expand to cope because of the fibrous sheath surrounding it. **Pressure in the compartment therefore increases.**

<http://www.running-physio.com/shin-pain-part-two/>



ill enters the damaged muscles naturally and, as the resistance to flow builds up, the blood becomes increasingly sluggish. This means that the blood supply to the muscles decreases. capillaries in the muscle tissue dilate and the tissues continue to swell. Eventually the pressure

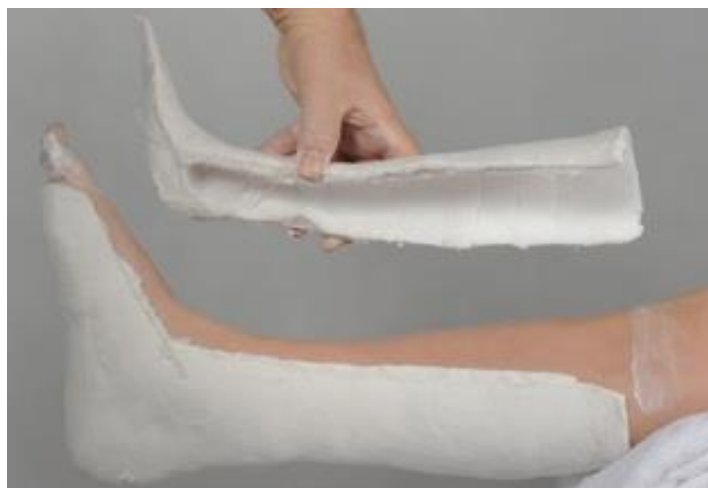in the tissues is the same as that in the small blood vessels, circulation to the muscles stops completely and they begin to die.

Why this process occurs is not fully understood. It is probably caused when the muscles in a compartment are damaged while the fascia remains intact. If the muscle is damaged, and its fascia is torn, it may swell without increasing pressure because it is no longer constricted by the fascia. However, in severe cases even a tear in the fascia may not protect the patient from compartment syndrome.

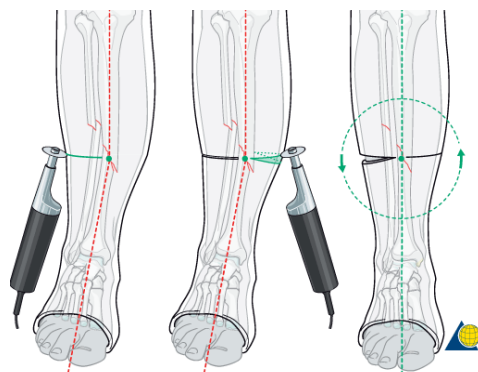
When a person with compartment syndrome is examined they complain of severe pain made worse by trying to move the injured part and adjacent joints. This pain is far worse than one would expect from the injury. The patient may not be able to use the muscles in the affected compartment voluntarily and the nerves may be affected, causing numbness and tingling.

It is important to realize that the major blood vessel to the limb may still be pulsating normally while the effects of compartment syndrome take place in the small, low pressure blood vessels in the muscle itself. Remember that a normal pulse in the limb does not mean that there is no local reduction in blood supply (ischemia) as a result of compartment syndrome.

Other causes of compartment syndrome are tight bandages or casts, as these can act like the tight fascia. **In acute treatment** always consider the possibility of such a problem - use back-slabs and flexible bandages wherever possible. If complete casts are used, they must be split to the skin, (see Figure 5), to permit the limb to expand. This will not affect the efficiency of the splint, and in any case, it is better to lose position of the fracture than to lose the limb.



http://www.rch.org.au/fracture-education/management_principles/Management_Principles/



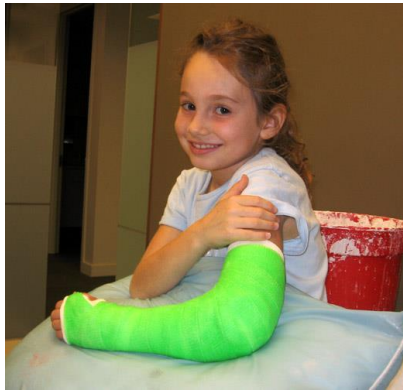www2.aofoundation.org

3.5 Direct Effects of Pressure

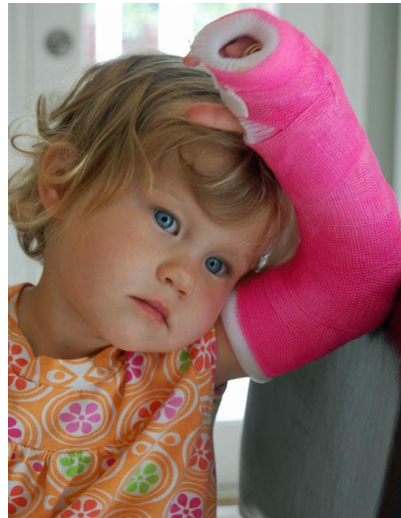Pressure will be exerted by a cast and its padding on a limb. The aim of the person who applies the cast is to ensure that pressure is distributed evenly over as large an area as possible, and that certain areas are well protected.

3.5.1 Even application of casts

Padding must be applied evenly with appropriate overlap so that there are no ridges



www.pic2fly.com



www.imgbuddy.com

Care must be taken to ensure that the joints are correctly positioned before the application of padding or it tends to wrinkle. Remember that wrinkles act as ridges when the casting material is applied and will produce areas of high pressure.

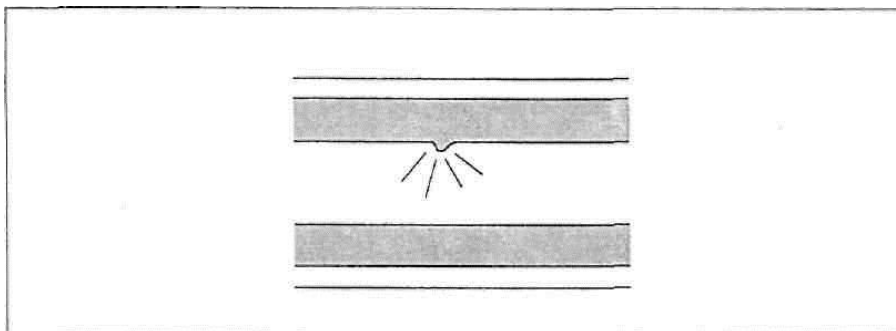


FIGURE SECTION THROUGH CAST TO SHOW EFFECT OF A WRINKLE IN THE PADDING.

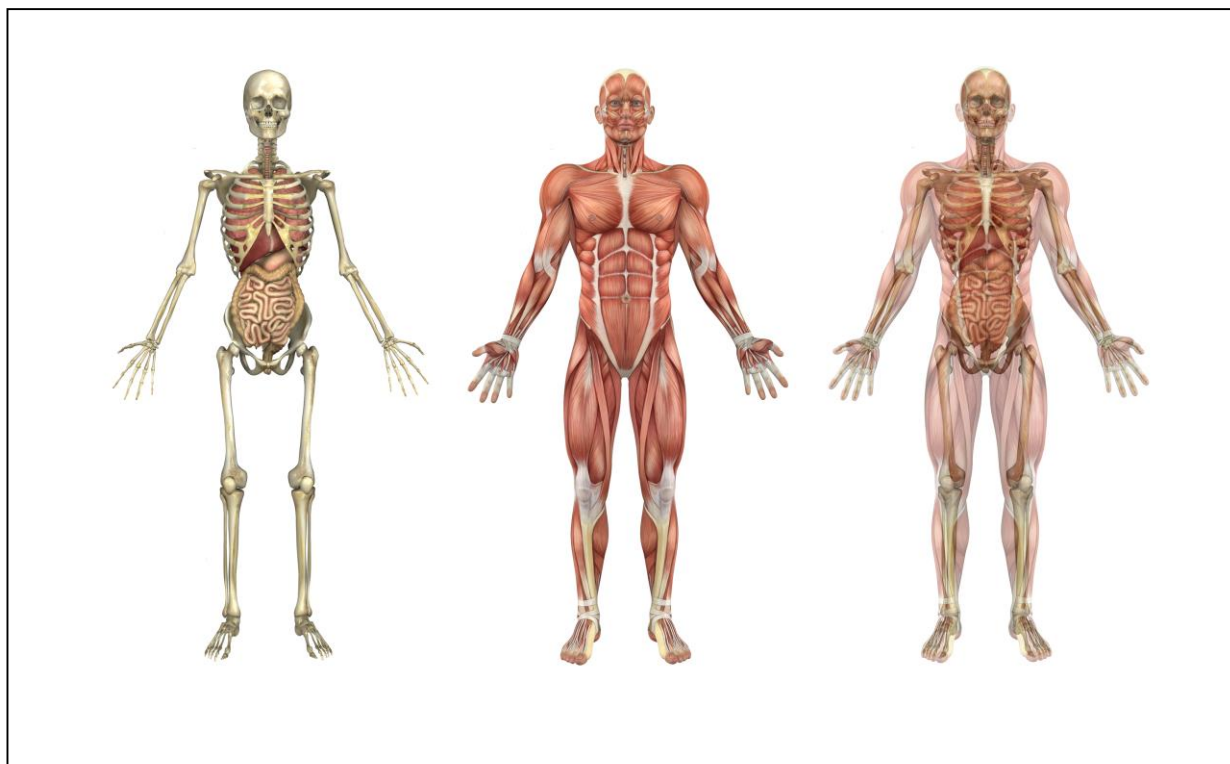
General indications that a cast may be too tight are complaints of tightness, swelling distal to the cast, duskiness of the skin, loss of peripheral pulses, tingling and loss of sensation. In extreme cases there may be a compartment syndrome in association with cast tightness. If these features are present then the cast must be split or removed.

3.5.2 Protection of particular areas

The following areas require particular attention because of anatomically vulnerable structures:

- ◆ The head of the fibula - this is an area of the fibula just below the skin and round which the common peroneal nerve winds.
- ◆ The malleoli - these structures are only protected by skin and the area has a poor blood supply, often made worse by venous congestion in the elderly, (see Figure 8)
- ◆ The distal end of ulna - again this is just under the skin and is very prominent, particularly in those patients suffering from rheumatoid arthritis.
- ◆ Other superficial bony points include the olecranon, the acromion and the crest of the pelvis.

All these areas must be padded carefully to avoid excess pressure which may lead to skin breakdown.



Signs that these areas may be affected adversely include:

- ◆ Loss of function - such as development of a weak foot dorsiflexion from common peroneal nerve damage.
- ◆ Change in sensation - this may be numbness or tingling below a pressure point.
- ◆ Pain and burning sensations - these must be taken seriously.
- ◆ Discoloration - if the skin is dusky or blue or if, when pressed until the skin blanches, it takes a long time to go pink again.

If any of these features are present then the cast must be removed and the area inspected.

3.6 The Effects of Heat

As described, both plaster of Paris and polyurethane polymers give off heat during setting. The amount of heat produced depends on two factors:

- ◆ The **temperature** of the water used in wetting the cast bandage.
- ◆ The **total quantity** of material used.

1. Take three rolls of old plaster of Paris.
2. Divide one roll into two halves. Wet one half with water as per manufacturer's instructions. Time how long it takes to set. Feel the temperature difference between the wet roll and the dry roll.
3. Take one of the remaining rolls and dip it in water as per manufacturer's instructions. Time how long it takes to set.
4. Dip the last roll (using forceps) in water that is too hot for your hands. Time how long it takes to set.

Up to a certain temperature, increasing the temperature of the water used will decrease the setting time. Beyond this optimum temperature the setting reaction will not continue to be accelerated. Using water at a higher temperature than the optimum only adds to the general heat hazard. Water temperatures should be kept well within the limits set by a manufacturer for their particular product.

The heat released per molecule involved in the chemical reaction is always the same. The more molecules there are, the more heat is given off. This means that thick heavy casts are more likely to generate higher temperatures than thin casts. In addition, a thick cast will tend to act as an insulator and retain the heat produced, thus increasing the risk.

4. RISKS IN REMOVAL OF PLASTERS

4.1 Cutting

Only one commercially available material has a zipper in it and nearly all casts have to be split for removal. There are two basic methods:

- ◆ Hand cast cutters
- ◆ Power cast cutters.

The principles are the same for both techniques. The cast should be cut from top to bottom down to the skin through the cast and the padding. Preferably, all casts should be cut in this manner on either side, so that the cast is cut in half (bi-valving). This is especially important with resin casting materials, as they are too strong and springy to be pried apart to remove them without risk of them springing back and nipping the patient.

When using hand cutters, be aware that they are designed to be used so that the lower jaw remains parallel to the skin at all times and does not dig in.

Power cutters work by vibrating a saw toothed disc - it does not rotate. In plaster of Paris casts, the vibration breaks up the plaster of Paris and only partly cuts it. In resin casts the vibrating saw must cut the material. This generates a great deal of heat which rapidly warms up the saw blade to dangerous levels. The saw should be stopped frequently and constantly rotated to dissipate heat. The saw should not come in contact with the skin. The vibrating blade is designed not to cut skin by ensuring the skin merely vibrates with the blade. However, it will cut skin over bony points and, if pressed heavily, can cut as well as burn. Power cutters do not cut a cast efficiently at the upper and lower margins where the material is more flexible and tends to vibrate with the blade. Manual cutting should be used at the margins. When power cutters are used, under cast padding should be cut with blunt nosed scissors.

[Note: More litigation occurs over cast removal than cast application.]

4.2 *Indenting*

If a cast is only split partially and pried there is a risk of it indenting the skin where it has to give way. This is avoided by bi-valving the cast.

4.3 *Penetration by Instruments*

Once split it may be necessary to insert a spreading instrument to prize the cast apart. These instruments may penetrate the skin if not used carefully.

4.4 *Dust*

Plaster of Paris dust has not been shown to be an industrial hazard and resin alone may also be thought of as relatively safe. However, glass fiber is a known industrial hazard. The long term effects of inhaling resin impregnated glass fiber remain unknown. It is prudent to avoid any dust hazard as a part of good working practice. Power cutting should be carried out using a saw with a dust extractor. Alternatives are to use hand cutting, which generates large heavy particles, or to use a face mask.

4.5 *Noise*

Noise can be very frightening for children and silenced saws may be obtained. Sawing is generally quicker and less traumatic than hand cutting once it can be demonstrated to the child's satisfaction that, if used properly, the saw will not cut them. The noise levels for regular users are probably unacceptable and ear protectors are recommended.

5. CHANGING PLASTERS

Once swelling has settled, a cast may have lost its effectiveness either because it no longer makes a good overall contact or because it has lost its three point contact (see section - Trauma): It is essential that a cast is changed as soon as these possibilities are recognized.

Signs that a cast is loose include:

- ◆ Complaints of discomfort because of movement of the cast
- ◆ The ability to move the cast vertically relative to the limb
- ◆ The ability to rotate a cast slightly on the skin

The risks of cast change are:

- ◆ Pain for the patient during removal
- ◆ Loss of position of the fracture

A balance has to be struck between these risks. Plasters should be changed without anesthetic provided the patient will co-operate (children may not). This has the advantage that muscle tone will tend to maintain fracture position. Often a simple painkiller such as oral codeine or injected morphine half an hour before the procedure will reduce discomfort to acceptable levels. Doctors can also block sensation by injecting local anesthetic around nerves.

After changing the cast it is essential that an X-ray is taken immediately afterwards to ensure the position of the fracture has not been lost.

6. BREAKAGES AND REPAIRS

Casts tend to break at predictable points, relating to how they are used and loaded. They break due to bending and impact forces.

Bending is a particular problem in the lower limb. As we walk we inevitably tend to alternately bend the cast backwards and forwards. Points where bending causes maximum compression are at the front around the joints - particularly the knee and ankle. Plaster particularly is susceptible to being crushed here and, once the material has been disrupted, it needs to be repaired.

Impact forces predictably occur at the heel and to a lesser extent at the elbow.

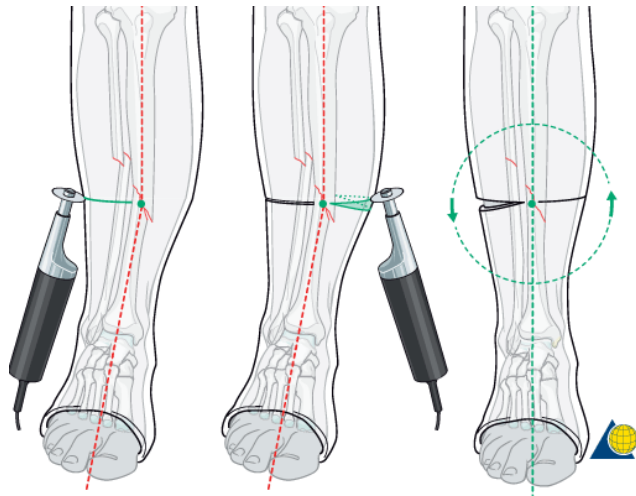
A cast should be repaired with the same material as it was made where possible as this will bind more efficiently to give a good repair.

In your plaster room, when the next three patients with below knee plaster or Paris splints return for an appointment, inspect their casts to see where they are soft or worn. Do the same for the next three patients with arm casts.

7. WEDGING TECHNIQUE

Wedging of a cast may be carried out to correct the alignment - particularly an angulation but occasionally a rotation. Wedging does not correct shift and occasionally makes shift worse. Wedging should always be done under medical supervision.

It is always better to perform an opening wedge - adding material - and not a closing wedge which removes material. The former tends to increase cast volume which is unlikely to cause pressure problems.

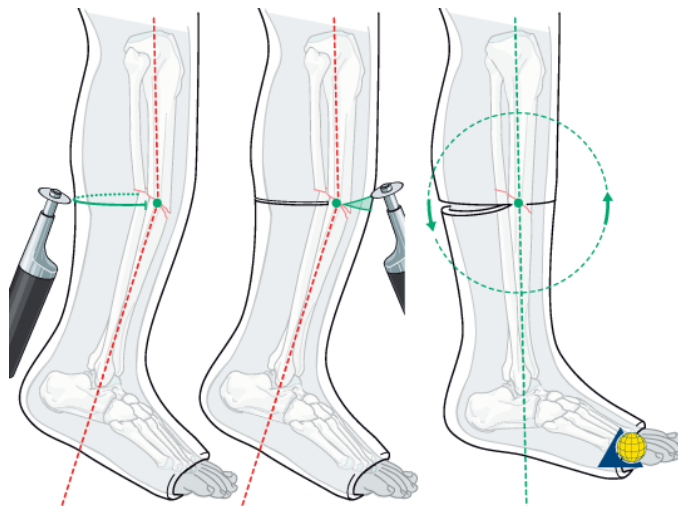


https://www2.aofoundation.org/wps/portal/tut/p/a0/04_Sj9CPykssy0xPLMnMz0vMAfGzOKN_A0M3D2DDbz9_UMMDRyDXQ3dw9wMDAx8jfULsh0VAdAsNSU!/?approach=&basicTechnique=Fracture%20management%20with%20limited%20resources&bone=Tibia&classification=&contentUrl=%2Fsrq%2F42%2F05-RedFix%2F2011EHS%2FNonOp%2F42EHS_12_CastWedging.pdf&segment=Shaft

The steps involved in wedging are as follows:

1. The patient is informed of the procedure and the reasons for it. He/she is suitably sedated for half an hour in advance if this is felt necessary.
2. An X-ray is taken in two planes. The cast is marked at intervals with radiolucent markers such as paper clips. This allows the exact level of the fracture to be identified relative to the cast.
3. Lines are drawn on the bones on the X-ray to show the angle to be corrected. The lines may also be drawn on the cast.
4. The angle of correction is measured. This will be the same as the angle of the wedge to be cut.
5. The cast is marked at the point where the two lines drawn on the bones intersect. This mark will be at a different level to where the bone ends currently meet. This is where the wedge is to be cut.
6. The cast is cut round two thirds of its circumference - less will cause dangerous indenting by the intact hinge.
7. The wedge is opened to the correct angle and held with the cut cork.
8. A new X-ray is taken to check the end result.
9. The cast is completed with the same material. The cork is removed where possible, or positioned so that it does not cause an internal pressure point.

The dangers of wedging are in creating general and localized pressure points.



https://www2.aofoundation.org/wps/portal/surgerymobile?contentUrl=/srg/42/05-RedFix/2011EHS/NonOp/42EHS_12_CastWedging.jsp&soloState=precomp&title=&Language=en&bone=Tibia&segment=Shaft

8. RECORDKEEPING

8.1 Cast Register

All plaster rooms must keep written records of all procedures carried out. This usually takes the form of a ledger (cast register) which must record the following:

- ◆ Patient name, address and telephone number
- ◆ Type of cast applied
- ◆ Date of application
- ◆ Name of technician or other person applying the cast
- ◆ Comments of any particular relevance

8.2 Other Records

- ◆ Requests for procedures should be made in writing - preferably in a form to be stored in the patient's notes.
- ◆ A record of any complications should be kept.
- ◆ Proper inventories of equipment and materials should be constantly updated.

9. LEGAL OBLIGATIONS TO PATIENTS

- ◆ All information given to cast room staff by doctors and patients is confidential.
- ◆ Patients, however famous, must not be discussed outside the confines of the plaster room.
- ◆ Requests for casting should be reasonable and technicians should feel free to query requests which seem inappropriate, without any prejudice.
- ◆ Plaster room staff are responsible for the safety of patients within their care whilst in the plaster room.
- ◆ Together with supervisory medical staff, a policy of communication between doctor, patient and plaster room staff must be established and procedures defined in writing.
- ◆ All accidents to patients and staff must be recorded according to the hospital's policy. An accident form should be completed. A good record is a better defense than no record, whoever seems to be to blame. Attempts to hide misadventures are always viewed with great suspicion by the law.
- ◆ Male workers should never find themselves alone with female patients, particularly if the patient is in a state of undress. A female chaperon must always be used.

10. COMMUNICATING WITH PATIENTS

Cast room staff must appreciate that having a cast is a novel experience for most people and having it put on and taken off can be most intimidating, especially for the young and the frail. A careful explanation of what is to be done, and reassurance that care will be taken, is essential. The hazards of having a cast are known to you but may not be obvious to the patients and so a verbal and written checklist of things to look out for should be discussed with the patients. One good way of ensuring the patient knows about the risks is to stick a warning list on the cast!

11. WALKING AIDS

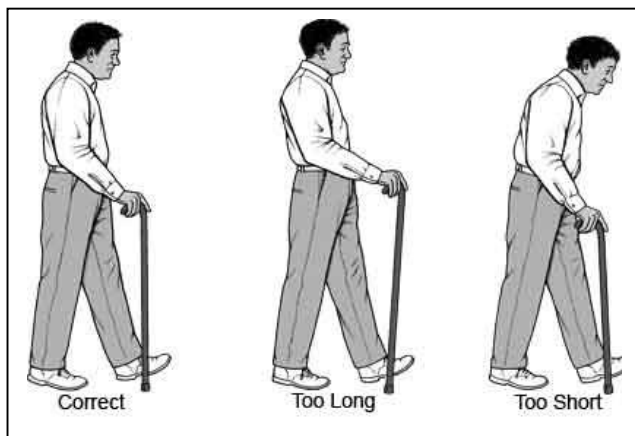
For most purposes in the plaster room three types of aid are in common use:

- ◆ Walking stick
- ◆ Crutches
- ◆ Frames

11.1 Sticks

A walking stick is used, on the opposite side to an injured limb, to off-load the limb in order to help an injured person to walk (see Figure 13). During weight bearing, loading on a limb is in part caused by the weight of the body and in part by muscle contractions across the joints. When muscles contract to make a joint move then the same force pulls both sides of a joint together. By using a stick, it is possible to take some of the weight of the body and also to reduce the need for the muscles to contract so strongly - so further off-loading the limb.

In the hip, to clear the non-weight bearing leg from the ground, the abductors of the weight bearing hip contract, tilting the pelvis up. This causes high loading of the weight bearing hip. Use of a stick on the opposite side will, in part, take some of the load of the body through the arm bypassing the weight bearing limb. It will also help to tilt the pelvis, reducing the need for the abductors to work so hard. Thus the hip is off-loaded in two ways



www.allgoodideas.co.uk

FIGURE . DIAGRAM TO SHOW THE USE OF A WALKING CANE.

An individual must be provided with a stick which is long enough to bear weight comfortably with the arm fairly straight, but not so long that it gets in the way.

11.2 Crutches

Crutches work in the same way as walking sticks but they provide more stability because they are held against the trunk. They also help by permitting a swing-through kind of gait.

Crutch walking is not particularly efficient as it involves a bobbing up and down motion. Moving the patient's center of gravity up requires a lot of physical work. When fitting crutches that permit efficient swing-through, it is important that they are not too long (making the bobbing up very inefficient) or too short (when the crutches will not permit any useful swing-through at all).



11.3 Frames

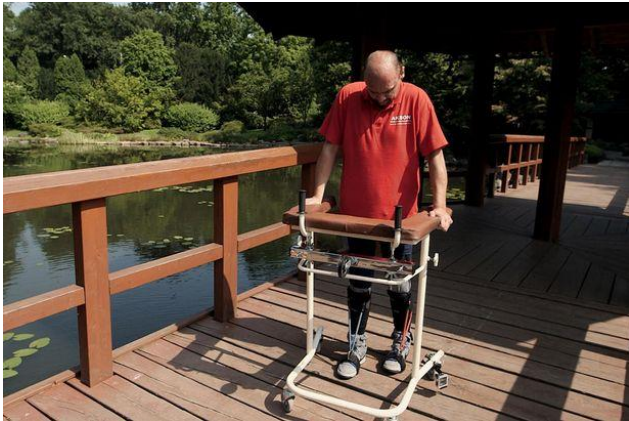Commonly known as Zimmer frames after the company which first introduced them (and who incidentally do not market them any longer), these devices consist of three or four limbed devices which provide stability for those who have difficulty balancing using sticks and crutches (Figure 15). They may be of value for the elderly. They are designed to ensure that a user is surrounded by a mechanism which keeps the center of gravity of the patient within the confines of the frame, so preventing a fall. Fitting follows similar principles to that of the other devices.



www.epts1960.com



www.walesonline.co.uk



www.dailyrecord.co.uk

11.4 Ferruling

All the devices above require a firm contact with the ground if the device is not to slip forward. This is provided by a rubber tip on each leg of the device - a ferrule. Before issue, all walking aids should be safety checked and all worn ferrules should be replaced.

12. SAFETY IN THE WORKPLACE

12.1 Handling Technique

Employers are required to ensure that the risk of injury to employees from manual handling is reduced, as far as is reasonably practicable, by assessing and reducing risks and by providing adequate training and/or instruction. Employees are required to make full and proper use of systems of work provided and to perform their jobs as trained and/or instructed.

Figure below shows a lifting position which can result in damage to the spine. The tension in the long back muscles, in this position, may be ten times greater than the weight of object being lifted. Also shows a load being lifted more safely - knees are bent, back is straight and the object being lifted is being held close in to the body. Lifting an object close to your body reduces the loading on the spine thus reducing the risk of injuring your back.



<http://thatsmyphysio.com.au/correct-lifting-techniques/>

FIGURE. (A) LIFTING POSITION THAT CAN RESULT IN INJURY TO THE BACK (B) SAFER LIFTING POSITION WITH KNEES BENT, BACK STRAIGHT AND THE LOAD HELD CLOSE TO THE BODY.

Plaster room staff should never lift a patient without help both from assistants and the patient themselves. A careful explanation to the patient about what is about to happen in a lifting procedure will reduce anxiety and encourage co-operation. Patients may help by holding onto monkey poles or other overhead lifting aids and also by pushing with their feet when being lifted from a lying to a sitting position.

To learn to lift safely in your own working environment, you must receive training.

13. FIRST AID

All hospital staff should understand the basis of first aid. It is desirable that all plaster room staff obtain a recognized first aid certificate. What happens in the first few moments after a sudden illness or accident can be critical. It is inadequate to assume that there will always be a doctor or nurse on hand.

PLEASE CONSULT YOUR LOCAL RED CROSS FOR FIRST AID AND OTHER APPROPRIATE LIFE SAVING PROCEDURES

SUMMARY

Being a professional means that you demonstrate the skills, the demeanor and the standard of conduct appropriate to your position. This module brings together a number of the professional aspects of being a plaster technician. It is not intended to be a practical guide to the application of certain kinds of casts. It is aimed at ensuring that you have a basic understanding of the general aspects of working in an environment where casting takes place. Hopefully it will encourage you to develop your skills by seeking further training in areas such as First Aid so that you may enhance your professional practice.

Being known as a professional has significant connotations. It means that you put the care of your patient above all things that you treat each individual with integrity and in a manner that you would wish for yourself or your family.

GLOSSARY

plaster of Paris

calcium sulphate

calcium sulphate hemihydrate

hard coated bandage

loose coated bandage

leno cloth

accelerator

retarders

glass fiber

polyurethane resins

monomer

terylene

polypropylene

composites

reduction

holding

acute inflammation

compartment syndrome

ischaemia

bi-valving

bending

impact

walking stick

crutches

Zimmer frames

ferrule

breathing

pulse

recovery position

abdominal thrust maneuver

fits

diabetes

hypoglycaemia