QUESTIONS PATIENTS ASK

When the Bite Changes and No One Can Explain It

Your teeth may be telling you something about the joint beneath them.

A stable foundation



Both joints have lost height



Dr. Mark Piper, DMD, MD

Board certified oral and maxillofacial surgeon

Piper Education

pipereducation.org

A question I hear more than any other

A patient notices that her teeth no longer meet the way they used to. One side touches first. Her front teeth may not quite close together. Chewing feels different, and something she never had to think about now feels wrong every time she bites.

She sees her dentist, then another. The teeth are examined, perhaps adjusted, perhaps fitted with a night guard. No one can tell her why it happened. Eventually she turns to an online support group and asks whether anyone else has lived through the same thing. Dozens of people answer that they have.

They are right. In more than forty years of imaging and surgically reconstructing temporomandibular joints, I have seen this story thousands of times. The explanation is usually not in the teeth at all. It is in the joint the teeth sit upon.

Your bite rests on a foundation

The lower jaw hangs from two joints, one in front of each ear. In each joint, the rounded top of the jawbone, the condyle, sits in a socket in the skull. Between them lies a small disc of firm, flexible tissue that cushions and guides every movement. The space the disc and condyle occupy sets the height and position of the entire lower jaw.

Your teeth meet wherever that jaw is held. If the space inside either joint changes, the jaw changes its posture, and the teeth meet differently. Even a slight disc shift out of place alters how the whole lower jaw sits. The bite changes the moment the foundation changes.

This is the core of what I call Joint Based Occlusion (JBO): a stable bite depends on a stable joint foundation. When that foundation is damaged, the result is Joint Based Malocclusion (JBM), a bite that has changed because the joint beneath it has changed.

Here’s what most patients have never been told. The teeth are often the first place a structural problem in the joint shows itself. Pain usually comes much later, sometimes years later. A bite that changes without explanation deserves a careful look at the joints.

How a damaged joint rearranges the bite

The most common mechanism is a loss of height inside the joint. A disc that has slipped out of place, a ligament torn by an injury, or bone worn down by arthritis all allow the condyle to sit higher and farther back in its socket. The jaw on that side rises.

When a joint loses height, a predictable pattern follows:

1. The back teeth collide first. When only one joint has lost height, the collision is on that side.
2. The chin moves. When both joints are injured, the chin may drop back. When only one is injured, the chin drifts toward the injured side.
3. The front teeth separate. When both joints are injured, the widest gap is between the front teeth. When only one is injured, the widest gap appears at the cuspids (the eyeteeth) on the opposite side. This separation is called an open bite. In the most severe cases, the front teeth can no longer touch when trying to bite into something.

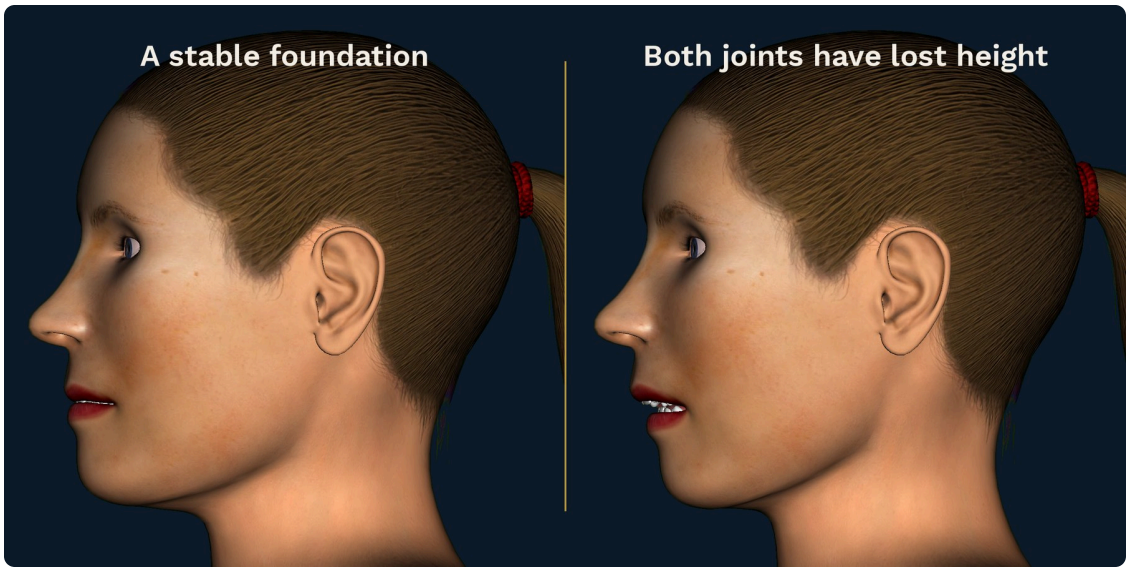

My Anomalous Medical model. Left, a stable foundation. Right, both joints have lost height: the chin drops back and the front teeth no longer meet.

Because two joints rarely lose exactly the same amount of height, many bites show a blend of these patterns, with one side deforming the bite more than the other.

A facial or jaw injury can start this process, even when no bone is broken. So can a disc displacement that began years earlier from childhood trauma. In 1990, Dr. Kurt Schellhas, M.R. Omlie, and I reported on 100 patients studied with CT and MR imaging. Degeneration of the jaw joint was the principal cause of acquired changes in the facial skeleton and of unstable bites, and the chin deviated toward the smaller or more diseased joint [1]. Those findings have held up through every case I have imaged since.

Why no one could explain it, and what to ask for

If your dentist could not explain your bite change, it is not because your dentist failed you. Dentistry trains its doctors to examine and treat the bite with great skill. Very few were trained to examine the temporomandibular joint, and fewer still were taught what to do with CT and MR images of it. The teeth are visible in the chair. The joint is not. As a result,

treatment often proceeds on the assumption that a bad bite caused the joint problem, when it is often the other way around. That is the central principle of Joint Based Dentistry: the joint changes first, and the bite follows.

Imaging is the only way to see the joint. An MRI shows the disc, ligaments, soft tissues, and bone marrow. A CT scan shows the condyle and its socket. Together, they answer the question every patient with an unexplained bite change deserves to have answered: what has happened inside the joint, and are the bite changes caused by those findings?

The Piper Classification of TMJ disorders, which I developed over decades of correlating these images with what I found in surgery, gives you and every clinician involved in your care a common language for the answer. It stages the joint from a normal foundation through progressive disc displacement and, ultimately, bone loss. Bite changes typically appear once the disc has displaced at both the outer and inner sides of the joint, and they become unstable when the bone itself begins to break down [3].

This matters most before any treatment that permanently changes the teeth. Grinding the teeth to fit, moving them with braces or aligners, building new crowns, or repositioning the jaw surgically all assume the foundation underneath is stable. In 1992, we studied 100 patients scheduled for jaw surgery and found joint derangement in 88 of them, so we recommended imaging the joints before operating on the bite to verify whether there were any signs of instability [2]. The same principle applies to any plan for extensive dentistry: image the joints before rebuilding the bite.

If your bite has changed and no one can tell you why, these are fair questions to bring to your dentist or physician:

> - Could my joints be the reason my bite has changed?
> - Can we image both joints with MRI and CT before my teeth are altered?
> - What stage is each joint, and is it stable or still changing?
> - If my joint is still changing, what will happen to my bite after treatment?

The foundation comes first

A bite that changes on its own is not a mystery. It is information. It is often the earliest signal that something has changed in the joint, and for many patients, the bite changes long before the joint announces itself with pain. Pay attention to any change you notice in your bite, and ask that the foundation be examined before undergoing extensive bite alteration.

I no longer see patients or offer individual consultations. What I can do is give you and your dentist the same foundational understanding I spent forty years developing in the operating room and the imaging suite. That is the purpose of Piper Education.

At pipereducation.org you will find:

- The Piper Classification of TMJ disorders, explained stage by stage, so you can understand what an imaging report is describing
- The Piper TMJ MRI Scan Protocol, which you can share with your dentist or physician and the imaging center
- Short videos under construction will show, with my Anomalous Medical model, exactly how a damaged joint moves the bite

Dr. Mark Piper, DMD, MD

References

1. Schellhas KP, Piper MA, Omlie MR. Facial skeleton remodeling due to temporomandibular joint degeneration: an imaging study of 100 patients. *AJNR Am J Neuroradiol*. 1990;11(3):541-551. PubMed 2112321. Free full text.
2. Schellhas KP, Piper MA, Bessette RW, Wilkes CH. Mandibular retrusion, temporomandibular joint derangement, and orthognathic surgery planning. *Plast Reconstr Surg*. 1992;90(2):218-229. PubMed 1631214.
3. Piper MA. Temporomandibular joint MRI and CT imaging. In: Kerstein RB, ed. *Handbook of Research on T-Scan Technology Applications in Dental Medicine*. IGI Global; 2025:413-562. doi:10.4018/978-1-6684-9313-7.ch005.

This article is educational and is not a diagnosis or medical advice for any individual.

Read this article online at pipereducation.org. To receive each new article as it is published, subscribe at drpipertmj.substack.com. Both patients and dentists are welcome. © 2026 Piper Education.